

Osteotome sinus floor elevation technique without grafting material: 3-year results of a prospective pilot study.

Rabah Nedir^{1,2}, Mark Bischof^{1,2}, Lydia Vazquez², Nathalie Nurdin¹, Serge Szmukler-Moncler³, Jean-Pierre Bernard²

¹ Ardentis Clinique Dentaire Vevey, Swiss Dental Clinics Group, Vevey, Switzerland.

² Department of Stomatology and Oral Surgery, School of Dental Medicine, University of Geneva, Switzerland.

³ Galeazzi Orthopaedic Institute, Department of Odontology, University of Milano, Milano, Italy.

Running title: Implant prognosis in non-grafted resorbed maxillae

Key words: Dental implants; sinus osteotome; sinus lift; grafting material; posterior maxilla; crestal bone loss.

ABSTRACT

Objective: In a prospective pilot study, short ≤ 10 mm ITI-SLA implants were placed in the resorbed posterior maxilla by means of an osteotome sinus floor elevation (OSFE) procedure without grafting material. This paper presents 3-year data assessing bone level changes around implants.

Material and methods: Twenty-five implants were placed in 17 patients to rehabilitate 16 molar and 9 premolar sites. The mean residual bone height (RBH) was 5.4 ± 2.3 mm. A healing period of 3-4 months was allowed before abutment tightening. Most implants (21/25) were 10 mm long, the others 8 and 6 mm. At the 3-year control, endo-sinus bone gain, implant length protruding into the sinus and crestal bone loss (CBL) were measured on periapical radiographs.

Results: All implants fulfilled survival criteria. Despite absence of grafting material, implants were embedded into newly formed bone tissue. All implants gained endo-sinus bone; the mean gained bone was 3.1 ± 1.5 mm. The residual protrusion length decreased from 4.9 ± 2.1 mm to 1.8 ± 2.1 mm. CBL was 0.9 ± 0.8 mm.

Conclusions: This study confirms that the OSFE procedure without grafting material is sufficient to create bone beyond the natural limit of the sinus. On the mid-term of three years, the technique showed to be predictable in the posterior maxilla when the RBH is limited. Implants gained endo-sinus bone despite the lack of grafting material. Bone gain was still improving over the first year control. No shrinkage of the augmented area was observed.

INTRODUCTION

Poor residual bone height (RBH) in the posterior maxilla beneath the sinus is still a challenge for the oral implantologist. To recreate a sufficient volume of bone, various surgical procedures have been developed over the years (Jensen et al. 1998; Fugazzotto 2003). Sinus elevation with a lateral approach is the most common of them. Implant placement can be performed either simultaneously or after a 6-8 months healing period with favorable results. However, this surgical procedure is rather complex and invasive; therefore, alternative methods have been developed to avoid it, whenever it is possible. The consensus conference held on sinus lift in 1996 (Jensen et al. 1998) recommended to adjust the surgical procedure according to the residual bone height. When the RBH belongs to class A and B (RBH 10 mm and 7-9 mm respectively), the lateral sinus lift surgery can be avoided. Instead, the osteotome sinus floor elevation (OSFE) through the crestal approach is applied with concomitant implant placement. However, when the residual bone belongs to class C (RBH 4-6 mm) or D (RBH 1-3 mm), the lateral approach is recommended; it involves the use of a grafting material in conjunction with immediate or delayed implant placement, for class C and class D, respectively.

The OSFE procedure, introduced by Summers (1994a, 1994b), is less invasive, less time-consuming and reduces post-operative discomfort to the patient. Recent meta-analysis showed it to be highly predictable in several short-term and long-term surveys (Emmerich et al. 2005; Shalabi et al. 2007). The procedure consists into elevating the Schneiderian membrane with osteotomes through a crestal approach, placing simultaneously the bone grafting material and the implant. After a healing period of 3-6 months, implants are osseointegrated and get surrounded with bone over the implant apex. This approach has been so reliable and predictable that some authors recommended going beyond the recommendation of the consensus conference of 1996. They have been extending the OSFE procedure to class C as well, when primary stability can be achieved (Nedir et al. 2006a; Davarpanah et al. 2008).

Recently the necessity of placing a filling material for sinus elevation procedures has been questioned, either in lateral (Bruschi et al. 1998; Haas et al. 1998; Winter 2002, 2003, Lundgren et al. 2003, 2004; Palma et al. 2006; Chen et al. 2007, Hatano et al. 2007) or crestal approaches (Nedir et al. 2006b; Winter 2002, 2003; Leblebicioglu et al. 2005). These groups demonstrated that, when a space is maintained between the sinus membrane and the sinus floor, bone forms and fills the graft-free volume. All the above-mentioned studies demonstrated the successful creation of bone beyond the original limits of the sinus but none has documented this fate on the longer-term.

In a previous clinical report (Nedir et al. 2006a), the one-year outcome of 25 implants placed in resorbed posterior maxillae with an OSFE procedure but without grafting material was presented. By that time, all implants were in function and supported the definitive prostheses. The simplified surgical procedure led to an endo-sinus bone gain of 2.5 ± 1.2 mm. Implant protrusion length in the sinus, which averaged 4.9 ± 2.1 mm immediately after placement, was reduced to 2.2 ± 1.1 mm.

The present study presents the 3-year clinical and quantitative radiographic evaluation of the same pool of implants. It was undertaken to answer the question of the proper becoming of the newly formed bone around these implants, created beyond the natural boundary of the sinus. Implant survival rates, endo-sinus bone

gain, implant length protruding into the sinus and crestal bone loss (CBL) were measured and analyzed.

MATERIALS AND METHODS

Inclusion criteria

Inclusion criteria to enroll in this pilot study were the following:

- (1) Patients had to require implant treatment in the posterior maxilla;
- (2) The OSFE procedure was performed without grafting material;
- (3) 10 mm long implants were planned, shorter ones (6 and 8 mm) were tolerated only in case of membrane perforation;
- (4) RBH was ≤ 8 mm on at least one implant side, either mesial or distal;
- (5) At least 1 mm of bone was required on the mesial and distal sides to ensure implant stability;
- (6) Implants had to penetrate at least 2 mm in the sinus on at least one side;
- (7) Implant primary stability had to be achieved;
- (8) Wearing a removable partial denture during the healing period was not permitted.

Surgical and prosthetic procedures

Between April and December 2003, 17 patients from a private practice setting were enrolled in the study. Patients were 14 females (82.3%) and 3 males (17.7%); the mean age was 54.2 ± 9.6 years, varying from 38 to 69 years. They received 25 Straumann SLA implants (Straumann AG, Basel, Switzerland), 16 in the molar area and 9 in the premolar, under clean but not sterile conditions as defined by Scharf & Tarnow (1993). All implants were placed with an OSFE procedure without grafting material; the procedure has been previously detailed elsewhere (Nedir et al. 2006a). Most implants (84%) were 10 mm long, 3 (12%) were 8 mm long and only 1 (4%) was 6 mm long. Implant diameter was 4.1 mm (80%) and 4.8 mm (20%). Bone quality was categorized according to Lekholm & Zarb (1985); this resulted in eight implants inserted in type II bone, 12 in type III and 5 in type IV.

After 3 to 4 months of healing, clinical stability was assessed. When implants were stable, abutments were tightened with a 35 Ncm torque. In case of implant rotation, an additional 6 weeks of healing was allowed. When the implant resisted the applied torque, the classical prosthetic steps were conducted and porcelain fused to gold prostheses were fabricated.

Clinical evaluation

The survival criteria proposed by Buser et al. (1997) and Cochran et al. (2002) were applied. They were: 1) absence of clinically detectable implant mobility, 2) absence of pain or any subjective sensation, 3) absence of recurrent peri-implant infection, 4) absence of continuous radiolucency around the implant.

Radiographic evaluation

Periapical radiographs were taken with the long-cone technique before and after implant placement, at 3 months, 6 months, 1 year and 3 years. Radiographs were analyzed at implant placement, at 1 and 3 years by the same investigator; implant placement served as baseline. The aim was to determine on both mesial and distal sides: 1) the actual RBH measured after implant placement, 2) the change in endo-

sinus bone level, 3) the change in implant protrusion into the sinus, 4) the change in crestal peri-implant bone level.

The radiographs were scanned in a digital format by a flatbed scanner (Epson Expression 1680 Pro, Wädenswil, Switzerland) at a resolution of 600 dpi. They were analyzed by a computerized measuring technique with image analysis software (Digora, Soredex, Helsinki, Finland) measuring the distance between 2 points. Internal calibration was performed for each radiograph on 3 inter-thread distances (3.75 mm), given that the tips of two consecutive threads are separated by 1.25 mm. Precision of the measuring system is 0.01 mm. In order to improve image analysis, image enhancement operations like sharpening, brightness, contrast and gamma adjustments were performed when necessary. Radiographic analysis and measurements were performed by an investigator not involved in the surgical procedure (VL).

The landmarks, appearing in figure 1, served to calculate the measurements, where:

- A is the vertical distance between the most coronal bone-implant contact and the most apical implant-bone contact. It indicated the RBH under the sinus,
- B is the distance from the most coronal implant thread to the most apical implant-bone contact. It served to assess the endo-sinus bone height;
- C is the distance from the most apical implant-bone contact to the implant dome. It indicated the protruding length of the implant into the sinus;
- D is the distance between the most coronal bone-implant contact and the most apical implant thread. It served to assess the crestal bone height.

Endo-sinus bone gain or loss was calculated by subtracting the B-distances measured at the 3-year control and immediately after implant placement. A positive outcome expressed a gain and a negative one a loss.

CBL was calculated by subtracting the D-values measured at the 3-year control and immediately after implant placement. When negative, the outcome expressed the amount of bone loss over this period.

Statistical analysis

Descriptive statistics, mean and standard deviation, were used to assess the endo-sinus bone level, protrusion length and crestal bone level changes at the mesial and distal implant sides. The non parametric Wilcoxon matched pairs signed-rank test was used to compare the groups of RBH and the groups of values of the endo-sinus bone gain, protrusion implant length and crestal bone loss measured at the 1-year (Nedir et al. 2006a) and at the 3-year control. The threshold value for statistical significance was set at 0.05 ($p < 0.05$).

RESULTS

Membrane perforation was recorded at four implant sites; this led to the placement of implants < 10 mm in length. After surgery, nasal bleeding was recorded for one patient; two patients had sensation of blocked-up nose that abated within a few days. Except the above episodes, healing was uneventful.

The RBH was measured after implant placement on the radiographs on both implant sides. Mean RBH was 5.4 ± 2.3 mm; on the mesial side it was 5.7 ± 2.6 mm and, on the distal side 5.1 ± 1.9 mm. The difference in bone height between the mesial and the distal sides varied substantially, up to 6 mm; details of the RBH have been extensively reported elsewhere (Nedir et al. 2006a).

After a period of 3.1 ± 0.4 months, abutments were tightened with a torque of 35 Ncm. One implant rotated after a healing period of 3.5 months. It was a \varnothing 4.1 mm x 10 mm implant placed in type IV bone; RBH at placement was 3.0 and 4.2 mm on the mesial and distal sides. Implants were rehabilitated with 4 single crowns and 13 fixed partial dentures of 2 to 3 units. All restorations were cemented.

All 17 patients completed the scheduled follow-up visits up to the three-year control. Figure 2 shows the radiographic follow-up of a case from implant placement to the 3-year control. By that time, no patient complained about pain, signs of suppuration or sinus-related pathology. All implants were clinically stable, leading to a survival rate of 100 %.

Radiographically, all implants gained endo-sinus bone; table 1 reports the various parameters measured on the radiographs. The mean endo-sinus bone gain was 3.1 ± 1.5 mm; it was 2.9 ± 1.6 mm and 3.1 ± 1.4 mm on the mesial and distal side, respectively, ranging from 0.7 to 5.8 mm. Table 2 shows the mean endo-sinus bone gain versus the RBH of the implant sides measured at implant placement. All 20 implant sides placed in lower RBHs (between 1 and 5 mm) gained more endo-sinus bone than those placed in RBH > 5 mm ($p=0.0001$ for the 1-year control and $p=0.008$ for the 3-year control).

At three years, the mean value of implant protrusion length into the sinus was 1.8 ± 1.1 mm; it was 1.6 ± 1.3 mm and 2.0 ± 1.1 mm on the mesial and distal side, respectively. Three implants became completely embedded into bone on the mesial side and were not protruding any more into the sinus. The outline of a clear demarcation of the new sinus limit beyond the anatomical one associated with bone densification could be detected at all implant sides except one. The mean CBL was 0.9 ± 0.8 mm; it was 1.0 ± 0.8 mm and 0.9 ± 0.8 mm on the mesial and distal side, respectively, ranging from 0.6 to 2.6 mm.

The present 3-year data can address this issue by comparing it with the 1-year data published previously (Nedir et al. 2006a). Comparison showed that endo-sinus bone increased by 0.6 ± 0.7 mm in average and was statistically significant ($p = 0.0009$). Starting from 2.5 ± 1.2 mm the first year, it was now 3.1 ± 1.5 mm. An additional bone gain was measured for 21 (84 %) implants out of 25, while 4 showed a decrease of 0.4 ± 0.2 mm in average. Similarly, implant protruding length have also evolved over the 2 years; it decreased by 0.3 ± 0.5 mm and the diminution was statistically significant ($p = 0.0105$). Instead of increasing, CBL has decreased by 0.3 ± 0.4 mm to reach 0.9 ± 0.8 mm at the 3-year control; the difference was statistically significant ($p = 0.0016$). Between the two milestones, 17 implants gained crestal bone height (0.5 mm in average), 6 were stable and 2 lost 0.5 and 0.1 mm, respectively.

DISCUSSION

The 100 % survival rate of implants included in the present pilot study showed that the osteotome approach can be relevant even when the RBH is < 5 mm. This is in line with other papers having reviewed the literature. Shalabi et al. (2007) reported an overall survival rate for implants placed with the osteotome procedure varying between 99% after 6 months to 94% after 42-56 months. Emmerich et al. (2005) based their meta-analysis on 1139 implants and found a survival rate of 97.5% and 90.9% after 12 and 36 months of loading, respectively. Although relying on a limited

number of implants, the high survival rate obtained in this study confirms that short rough-surfaced implants are predictable in the maxillary posterior region (Nedir et al. 2004).

The osteotome procedure without grafting material was effective for all the studied implants in forming new bone beyond the original limits of the sinus. Compared to baseline, peri-implant bone was denser on all radiographs and was found to partially or completely embed the implants. The fact that all implants have been successfully functioning demonstrates that the newly formed ensemble of bone is able to provide adequate support to prostheses in full occlusion, even on the mid-term. In addition, it shows that, like in standard situations (Nedir et al. 2004), implants of 10 mm and less in length are efficient under these specific conditions. The study confirms that a grafting material is not needed to promote osteogenesis and maintain the bone volume around the implants.

Choosing the most suitable grafting material for sinus augmentation has been a subject of controversy over the years. Autogenous bone graft has been the most widely used grafting material (Daelemans et al. 1997). Despite increased morbidity, surgical and duration of hospitalization, autogenous bone graft has been often considered as the "gold standard" of bone grafting materials for sinus augmentation (Daelemans et al. 1997). However, as its resorption rate is high, particularly when cancellous bone is used, it is often insufficient to promote the expected osteogenesis and bone remodelling (Haas et al. 1998, Keller et al. 2000). To avoid the problems related to bone harvesting at secondary surgical sites, bone substitutes were proposed. Esposito et al. (2006) reported that they are as effective as autogenous bone grafts in case of extremely atrophic ridge. Bone substitutes can fill large volumes beyond the physiological limits of the sinus and be maintained over time. However, xenograft materials of bovine origin like Bio-Oss[®] have no osteoinductive potential, only osteoconductive properties. They act as a scaffold for new bone apposition (Davies 1996, Berglundh & Lindhe 1997) and become integrated in the newly formed tissue (Botticelli et al. 2004). Bovine bone material undergoes a slow resorption process and is still present until at least 6 years (Schlegel & Donath 1998). This slow resorption rate allows maturation of the grafted site. The sinus membrane is maintained elevated and the gained volume is preserved while newly formed bone gradually replaces the grafting material (Zitzmann & Schärer 1998). Combination of grafting materials, such as mixtures of autogenous bone and bovine xenograft, is supposed to simultaneously promote osteogenesis and to preserve the augmented bone volume (Del Fabbro et al. 2004). Thus the quest for the best grafting material for sinus augmentations may be solved in an unexpected way if successful and reliable sinus augmentations can be performed without any grafting material.

A critical difference between the lateral and the crestal approach is that by the end of the osseointegration period, implants placed with the lateral approach are embedded in a larger bone volume. Immediately after surgery, the grafted bone area can end up with 5-10 mm of material above the implant apex (Hatano et al. 2004; Blus et al. 2008) while with osteotome technique it is limited to 1-3 mm above the apex (Zitzman & Schärer 1998; Fugazzotto 2003; Brägger et al. 2004; Nedir et al. 2006a). Several papers have now documented the ability of forming bone without grafting material when the Schneiderian membrane has been lifted beyond the anatomical limits of the sinus floor, either crestally (Leblebicioglu et al. 2005) or laterally (Lundgren et al. 2003, 2004; Winter 2002, 2003; Palma et al. 2006; Chen et al. 2007; Hatano et al. 2007). But none has so far documented a 3-year follow-up to check the behavior of

the bone newly formed during the first 6 to 12 months; does it shrink, remain stable or get more mineralized? It is legitimate to question the long-term destiny of the neo-formed bone because a certain rate of resorption at the expense of the sinus cavity has been documented to happen over time with grafting materials (Hatano et al. 2004; Brägger et al. 2004). Indeed, partial resorption of the grafted area has been reported when the sinus is augmented either with a limited volume via the osteotome technique (Brägger et al. 2004) or with a large volume of grafting material via the lateral approach (Peleg et al. 1999; Hatano et al. 2004). In an up to 10-year survey, Hatano et al. (2004) found on radiographs that the height of the embedding bony material measured at implant placement decreases substantially during the first three years; then it stabilizes at or slightly below the level of the implant apices. It might be interesting to speculate on the relevance of striving to place under the elevated membrane the greatest possible volume of grafting material. In addition, there is no long-term study investigating the future of the bone gained with the crestal approach. It must be, therefore, clarified if the extend of bone resorption stops close to the level of the implant apex, as for the lateral approach (Hatano et al. 2004), or if the neo-formed bone slowly resorbs and, after a longer period of time, reaches back the original volume of the sinus because of the internal pneumatization forces. In the latter case, the limited bone volume gained by the osteotome procedure would be doomed. It would resorb beyond the implant apex and result in an insufficient bone height.

In the present study, the bone height gained at the expenses of the sinus did not shrink over 2 years as this has been documented when grafting materials of either xenogenic origin (Brägger et al. 2004) or mixed with autologous bone in a rapport of 1:2 (Hatano et al. 2004). Noteworthy, the above documented resorption reached a level close to the implant apices that corresponds to the augmented level in this study. No standardized densitometric analysis with an aluminium reference wedge was performed to follow evolution of the bone density over the two years, but densification of the bone formed after the osteotome procedure was subjectively noticed. This may indicate that the bone that had developed around the implants during the first year was remodeled to adapt to the loading condition. The new elevated sinus floor was also better delimited and was level with the implant apices. An increase above the apices is not to be expected since the tenting effect is limited to the implant dome. Yet, three years after membrane elevation, it is premature to make a definitive assessment on the durability of this created bone; 5-year and more studies are warranted. But the fact that shrinkage of the novel bone was not observed and remained stable during these three years is promising. Indeed, reduction of the grafted volume down to implant apices has been reported to be significant during the first three years and then remained stable over time, up to 10 years (Hatano et al. 2004).

CBL might provide information about the capacity of peri-implant bone to withstand occlusal stresses (Isidor 1996, 2006; Szmukler-Moncler et al. 2008). The presence of a steep crestal bone loss (Szmukler-Moncler et al. 2008) might have indicated that the newly obtained bone support is still insufficient to optimally distribute the peak stresses, that are occurring at the crest for implants with a rough surface (van Oosterwyck et al. 1998).

The reason for CBL reduction over time is unclear because it has been usually reported to increase with time (Albrektson et al. 1986, Behneke et al. 2002). It can be that the new created endo-sinus bone get remodeled; it provided a better overall

support to the occlusal stresses and bone grew back, close to the limit of the rough-machined neck border. But, it can also be that bone level remained unchanged and that densification of the crestal bone happened with time. This made the limits of the first bone-to-implant contact to become more accurate than previously. In the best case, the net bone gain was augmented by 0.9 ± 0.9 mm. In the worst case, CBL did not increase with time but this result can be nevertheless another piece sustaining the durability of this treatment without bone grafting.

The consensus conference recommended using the lateral approach instead of the crestal one when the RBH was 4-6 mm, i.e. belonging to class C. The reason for this limitation was because implant primary stability was considered more difficult to achieve in such a limited amount of bone (Toffler 2004). This present pilot study has shown that the osteotome approach can be used even when the RBH is less than 5 mm. Achieving primary stability was indeed more difficult than in denser bone (Nedir et al. 2006a) but it was still feasible. Finally, to ease this promising procedure, we found in a previous study (Nedir et al. 2006b) that primary stability in reduced RBH of 1-6 mm could be more easily secured by using tapered implants with threads up to the limit of the neck, like the Straumann Tapered Effect (TE[®]) implant.

CONCLUSION

Despite a limited number of treated patients, the results of this three-year pilot study demonstrated that: 1) a grafting material is not needed to promote osteogenesis in an OSFE procedure in the atrophic maxilla, 2) elevating the Schneiderian membrane with simultaneous implant placement is sufficient to create bone beyond the natural limit of the sinus, 3) the present technique without grafting material can be predictable because the success rate was 100 %, 4) bone gain observed at the 1-year control is preserved and does not shrink, 5) on the contrary, bone gain slightly increased over the two years in a statistically significant way, making thus a patent difference with grafting materials that shrink. Further studies are needed to evaluate the fate of the newly formed bone over time.

REFERENCES

- Albrektsson, T., Zarb, G.A., Worthington, P. & Eriksson, A.R. (1986) The long-term efficacy of currently used dental implants: a review and proposed criteria of success. *The international Journal of Oral and Maxillofacial Implants* **1**: 11-25.
- Behneke, A., Behneke, N. & d'Hoedt, B. (2002) A 5-year longitudinal study of the clinical effectiveness of ITI solid-screw implants in the treatment of mandibular edentulism. *The international Journal of Oral and Maxillofacial Implants* **6**:799-810.
- Berglundh, T. & Lindhe, J. (1997) Healing around implants placed in bone defects treated with Bio-Oss[®]. An experimental study in the dog. *Clinical Oral Implants Research* **8**:117-24.
- Blus, C., Szmukler-Moncler, S., Salama, M., Salama, H. & Garber, D. (2008) Sinus bone grafting procedures using ultra-sonic bone surgery. A 5-year experience. *The International Journal of Periodontics and Restorative Dentistry* **28**: in press.
- Botticelli, D., Berglundh, T. & Lindhe, J. (2004) The influence of a biomaterial on the closure of a marginal hard tissue defect adjacent to implants. An experimental study in the dog. *Clinical Oral Implants Research* **15**:285-292.

- Brägger, U., Gerber, C., Joss, A., Haenni, S., Meier, A., Hashorva, E. & Lang, N.P. (2004) Patterns of tissue remodeling after placement of ITI® dental implants using an osteotome technique: a longitudinal radiographic case cohort study. *Clinical Oral Implants Research* **15**:158-166.
- Bruschi, G.B., Scipioni, A., Celesini, G. & Bruschi E. (1998) Localized management of sinus floor with simultaneous implant placement. A clinical report. *The International Journal of Oral & Maxillofacial Implant* **13**:219-226.
- Buser, D., Mericske-Stern, R., Bernard, J.P., Behneke, A., Behneke, N., Hirt, H.P., Belser, U.C. & Lang NP. (1997) Long-term evaluation of non-submerged ITI implants. Part 1: 8-year life table analysis of a prospective multi-center study with 2359 implants. *Clinical Oral Implants Research* **8**:161-172.
- Chen, T.W., Chang, H.S., Leung, K.W., Lai, Y.L. & Kao, S.Y. (2007) Implant placement immediately after the lateral approach of the trap door window procedure to create a maxillary sinus lift without bone grafting: a 2-year retrospective evaluation of 47 implants in 33 patients. *Journal of Oral and Maxillofacial Surgery* **65**:2324-2328
- Cochran, D.L., Buser, D., ten Bruggenkate, C., Weingart, D., Taylor, T.M., Bernard, J.P., Peters, F. & Simpson, J.P. (2002) The use of reduced healing times on ITI® implants with a sandblasted and etched (SLA) surface: early results from clinical trials on ITI® SLA implants. *Clinical Oral Implants Research* **13**:144-153.
- Daelemans, P., Hermans, M., Godet, F. & Malevez, C. (1997) Autologous bone graft to augment the maxillary sinus in conjunction with immediate endosseous implants: a retrospective study up to 5 years. *International Journal of Periodontics and Restorative Dentistry* **17**:27-39.
- Davarpanah, M., Szmukler-Moncler, M., Khoury, P.M., Jakubowicz-Kohen, B., Martinez, H. (2008) *Manuel d'Implantologie clinique. Concepts, protocoles et innovations récentes*, 2nd edition, p. 367-416. Paris: CdP Editions.
- Del Fabbro, M., Testori, T., Francetti, L. & Weinstein, R. (2004) Systematic review of survival rates for implants placed in the grafted maxillary sinus. *International Journal of Periodontics and Restorative Dentistry* **24**:565-577.
- Emmerich, D., Att, W. & Stappert, C. (2005) Sinus floor elevation using osteotomes: a systematic review and meta-analysis. *Journal of Periodontology* **76**:1237-1251.
- Esposito, M., Grusovin, M.G., Coulthard, P. & Worthington, H.V. (2006) The efficacy of various bone augmentation procedures for dental implants: a Cochrane systematic review of randomized controlled clinical trials. *The International Journal of Oral and Maxillofacial Implants* **21**:696-710.
- Fugazzotto, P.A. (2003) Augmentation of the posterior maxilla. A proposed hierarchy of treatment selection. *Journal of Periodontology* **74**:1682-1691.
- Haas, R., Donath, K., Födinger, M. & Watzek, G. (1998) Bovine hydroxyapatite for maxillary sinus grafting: comparative histomorphometric findings in sheep. *Clinical Oral Implants Research* **9**:117-122.
- Hatano, N., Shimizu, Y. & Ooya K. (2004) A clinical long-term radiographic evaluation of graft height changes after maxillary sinus floor augmentation with a 2:1 autogenous bone/xenograft mixture and simultaneous placement of dental implants. *Clinical Oral Implants Research* **15**:339-345.
- Hatano, N., Sennerby, L. & Lundgren, S. (2007) Maxillary Sinus Augmentation Using Sinus Membrane Elevation and Peripheral Venous Blood for Implant-Supported Rehabilitation of the Atrophic Posterior Maxilla: Case Series. *Clinical Implant Dentistry and Related Research* **9**:150-155.

- Isidor, F. (1996) Loss of osseointegration caused by occlusal load of oral implants. A clinical and radiographical study in monkeys. *Clinical Oral Implants Research* **7**:143-152.
- Isidor, F. (2006) Influence of forces on peri-implant bone. *Clinical Oral Implants Research* **17**:8-18.
- Jensen, O.T., Shulman, L.B., Block, M.S. & Lacone, V.J. (1998) Report of the sinus consensus conference of 1996. *The International Journal of Oral and Maxillofacial Implants* **13(sup)**:11-32.
- Keller, E.E., Tolman, D.E. & Eckert, S. (1999) Surgical-prosthetic reconstruction of advanced maxillary bone compromise with autogenous onlay block bone grafts and osseointegrated endosseous implants: a 12-year study of 32 consecutive patients. *The International Journal of Oral and Maxillofacial Implants* **14**:197-209.
- Leblebicioglu, B., Ersanli, S., Karabuda, C., Tosun, T. & Gokdeniz, H. (2005) Radiographic evaluation of dental implants placed using an osteotome technique. *Journal of Periodontology* **76**:385-390.
- Lekholm, U. & Zarb, G.A. (1985) Patient selection and preparation. In: Brånemark, P.I., Zarb, G.A. & Albrektsson, T., eds. *Tissue Integrated Prostheses: Osseointegration in Clinical Dentistry*, p.199-209, Chicago: Quintessence Publishing Company.
- Lundgren, S., Andersson, S. & Sennerby, L. (2003) Spontaneous bone formation in the maxillary sinus after removal of a cyst: coincidence or consequence? *Clinical Implant Dentistry and Related Research* **5**:78-81.
- Lundgren, S., Andersson, S., Gualini, F. & Sennerby, L. (2004) Bone reformation with sinus membrane elevation: a new surgical technique for maxillary sinus floor augmentation. *Clinical Implant Dentistry and Related Research* **6**:165-173.
- Nedir, R., Bischof, M., Briaux, J.M., Beyer, S., Szmukler-Moncler, S. & Bernard, J.P. (2004) A 7-year life table analysis from a prospective study on ITI implants with special emphasis on the use of short implants. Results from a private practice. *Clinical Oral Implants Research* **15**:150-157.
- Nedir, R., Bischof, M., Vazquez, L., Szmukler-Moncler, S. & Bernard, J.P. (2006a) Osteotome sinus floor elevation without grafting material: a 1-year prospective pilot study with ITI implants. *Clinical Oral Implants Research* **17**:679-686.
- Nedir, R., Szmukler-Moncler, S., Nurdin, N. & Bischof, M. (2006b) Another indication for tapered Straumann-TE implants: placement in the posterior resorbed maxilla. *Clinical Oral Implants Research* **17(4)**:lxxvii.
- Palma, V.C., Magro-Filho, O., de Oliveria, J.A., Lundgren, S., Salata, L.A. & Sennerby L. (2006) Bone reformation and implant integration following maxillary sinus membrane elevation: an experimental study in primates. *Clinical Implant Dentistry and Related Research* **8**:11-24.
- Peleg, M., Mazor, Z. & Garg, A.K. (1999) Augmentation grafting of the maxillary sinus and simultaneous implant placement in patients with 3 to 5 mm of residual alveolar bone height. *The International Journal of Oral and Maxillofacial Implants* **14**:549-556.
- Scharf, D.R. & Tarnow, D.P. (1993) Success rates of osseointegration for implants placed under sterile versus clean conditions. *Journal of Periodontology* **64**: 954-956.
- Shalabi, M.M., Manders, P., Mulder, J., Jansen, J.A. & Creugers, N.H.J. (2007) A meta-analysis of clinical studies to estimate the 4.5-year survival rate of implants placed with the osteotome technique. *The International Journal of Oral Maxillofacial Implants* **22**:110-116.

- Schlegel, A.K. & Donath, K. (1998) BIO-OSS - a resorbable bone substitute? *Journal of Long-Term Effects of Medical Implants* **8**:201-209.
- Summers, R.B. (1994a) A new concept in maxillary implant surgery: the osteotome technique. *Compendium of Continuous Education in Dentistry* **15**:152-160.
- Summers, R.B. (1994b) The osteotome technique. Part 3. Less invasive methods in elevation of the sinus floor. *Compendium of Continuous Education in Dentistry* **15**:698-708.
- Szmukler-Moncler, S., Davarpanah, M., Bernard, J.P., Jakubowicz-Kohen, B. & Khoury, P.M. (2008) Réponse des tissus durs et mous à l'implantation. in : Davarpanah, M., Szmukler-Moncler, S., Khoury, P.M., Jakubowicz-Kohen, B. & Martinez M. *Manuel d'implantologie clinique. Concepts, protocoles et innovations récentes*, 2nd edition, p. 25-57, Paris: CdP Editions.
- Toffler, M. (2004) Osteotome-mediated sinus floor elevation: a clinical report. *International Journal of Oral and Maxillofacial Implants* **19**: 266-273.
- van Oosterwyck, H., Duyck, J., Vander Sloten, J., Van der Perre, G., De Cooman, M., Lievens, S., Puers, R. & Naert, I. (1998) The influence of bone mechanical properties and implant fixation upon bone loading around oral implants. *Clinical Oral Implants Research* **9**: 407-418.
- Winter, A.A., Pollack, A.S. & Odrich, R.B. (2002) Placement of implants in the severely atrophic posterior maxilla using localized management of the sinus floor: a preliminary study. *The International Journal of oral Maxillofacial Implants* **17**:687-695.
- Winter, A.A., Pollack, A.S. & Odrich, R.B. (2003) Sinus/alveolar crest tenting (SACT): a new technique for implant placement in atrophic maxillary ridges without bone grafts or membranes. *International Journal of Periodontics and Restorative Dentistry* **23**:557-565.
- Zitzmann, N.U. & Schärer, P. (1998) Sinus elevation procedures in the resorbed posterior maxilla. Comparison of the crestal and lateral approaches. *Oral Surgery Oral Medicine Oral Pathology Oral Radiology and Endodontics* **85**:8-17.

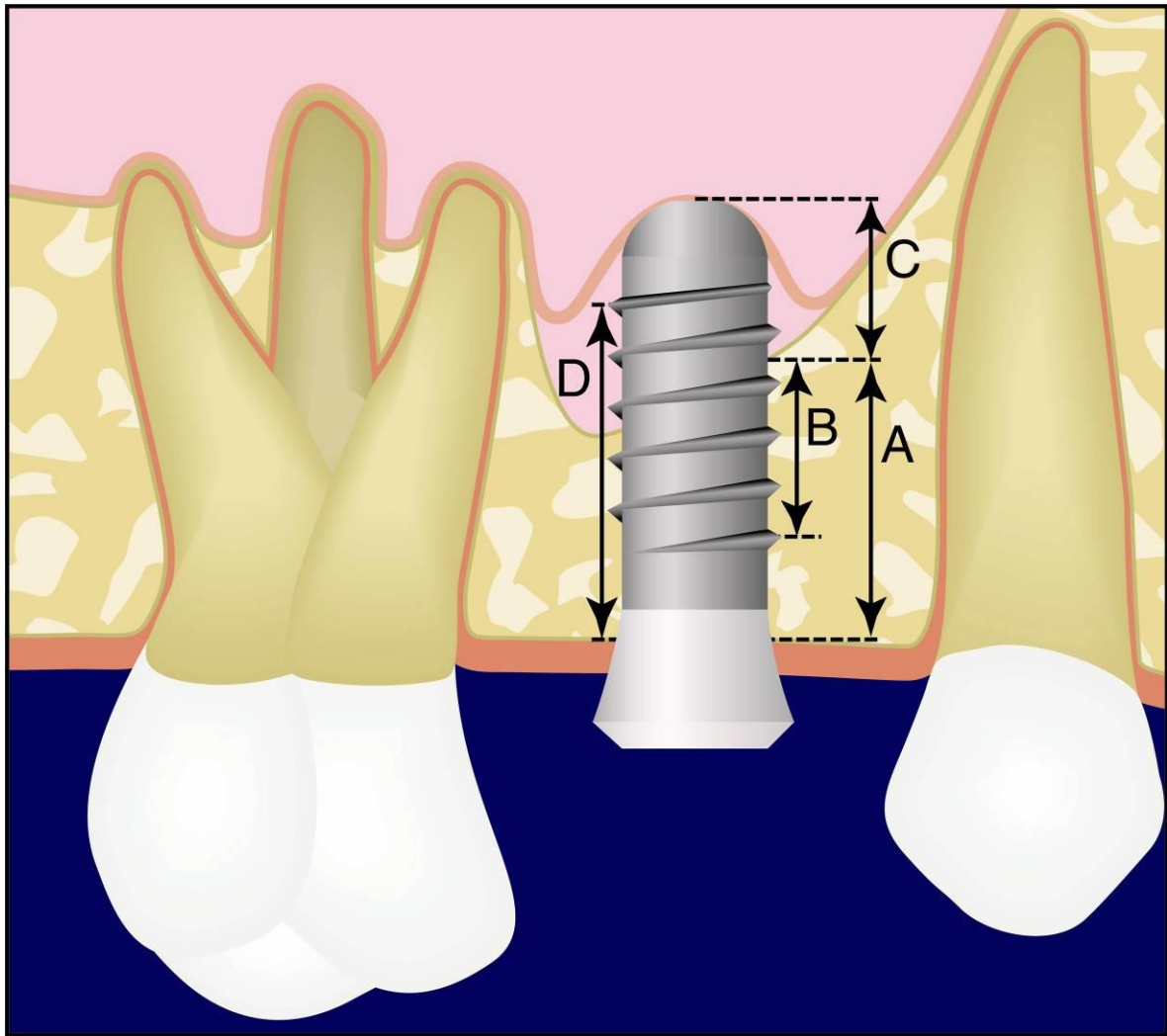


Fig. 1. Schematic drawing of the parameters measured on radiographs:
A: residual bone height under the sinus.
B: distance from the most coronal implant thread to the most apical visible implant-bone contact. Increase in the B distance corresponds to endo-sinus bone gain.
C: implant length protruding in the sinus.
D: distance from the most coronal bone-implant contact to the most apical implant thread. Decrease in the D distance corresponds to crestal bone loss.

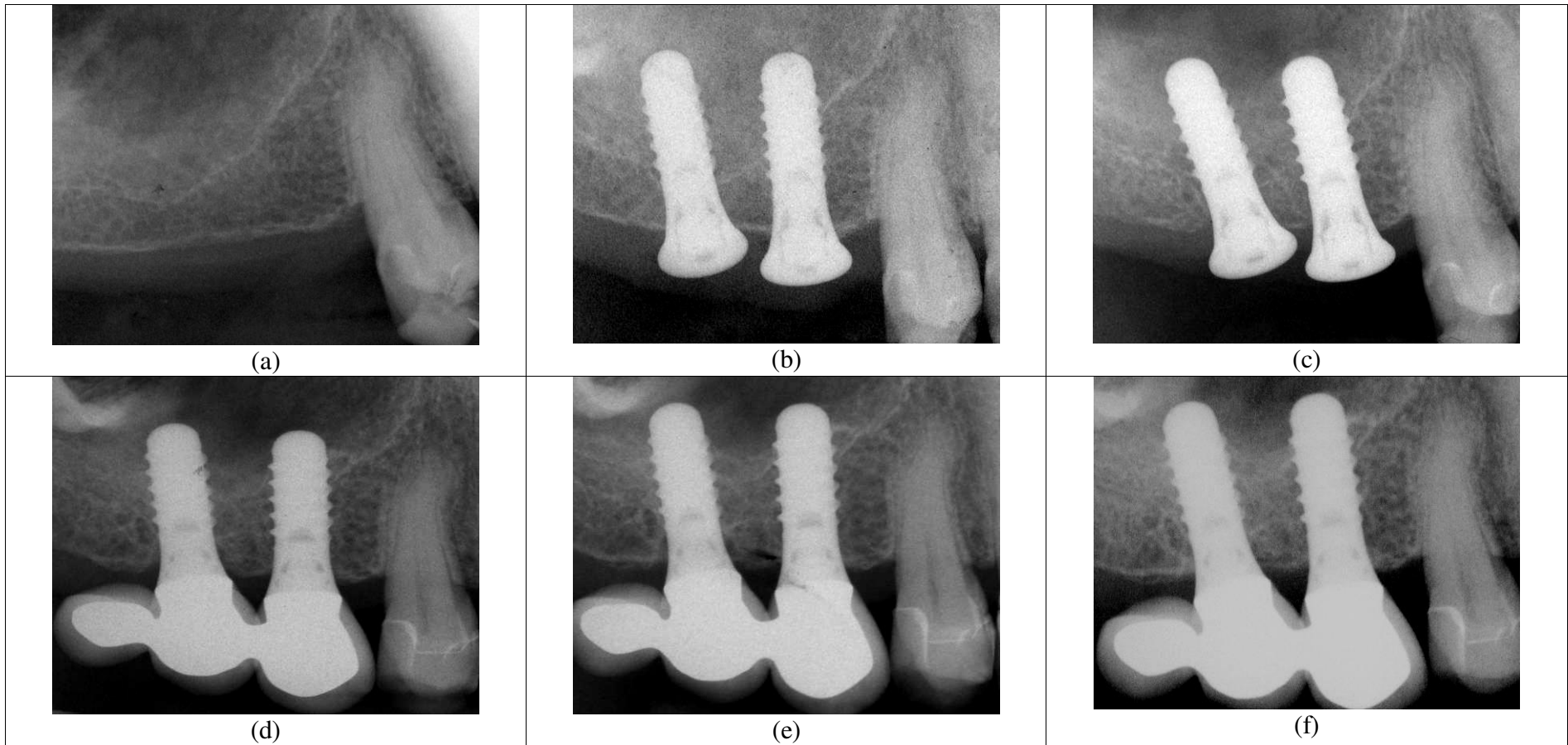


Fig. 2. Radiographic evolution of sinus demarcation after the OSFE procedure without grafting material. Radiograph taken: (a) before implant placement, (b) immediately after implant placement, (c) after 3 months, (d) after 6 months, (e) after 1 year, (f) after 3 years.

Measured parameters	Residual bone height (mm)	Endo-sinus bone gain (mm)	Implant protruding length (mm)	Crestal bone loss (mm)
at implant placement	5.4 ± 1.9	-	4.9 ± 2.1	-
at the 1-year control	-	2.5 ± 1.2	2.2 ± 1.1	1.2 ± 1.5
at the 3-year control	-	3.1 ± 1.5	1.8 ± 1.1	0.9 ± 0.8

Table 1. Bone parameters measured and calculated on the radiographs taken immediately after implant placement and at the 3-year control. Data of the 1-year control have been measured elsewhere (Nedir et al. 2006a); they are brought here for comparison. The difference in respectively endo-sinus bone gain, implant protruding length and crestal bone loss values between 1- and 3-year controls was statistically different (respectively $p=0.0009$, $p=0.0105$ and $p=0.0016$).

RBH (mm)	Number of implant sides	Endo-sinus bone gain after 1-year (mm)	Endo-sinus bone gain after 3-years (mm)
1 < RBH < 3	9	3.2 ± 0.8	4.0 ± 1.2
3 < RBH < 5	11	3.3 ± 1.1	3.7 ± 1.3
5 < RBH < 7	18	2.4 ± 1.0	3.0 ± 1.5
7 < RBH	12	1.4 ± 0.5	1.9 ± 0.9

Table 2. Endo-sinus bone gain measured at the 1- and 3-year controls versus RBH of the mesial and distal implant sides measured at placement time.

The difference in endo-sinus bone gain values measured for groups with $RBH < 5$ mm and $RBH > 5$ mm was statistically different ($p=0.0001$ for the 1-year control and $p=0.0008$ for the 3-year control).