

Osteotome sinus floor elevation technique without grafting: A five-year prospective study

Rabah Nedir^{1,2}, Nathalie Nurdin¹, Lydia Vazquez²,

Serge Szmukler-Moncler³, Mark Bischof^{1,2}, Jean-Pierre Bernard²

¹ Ardentis Clinique Dentaire Vevey, Swiss Dental Clinics Group, Vevey, Switzerland.

² Department of Stomatology and Oral Surgery, School of Dental Medicine, University of Geneva, Switzerland.

³ Department of Odontology, Galeazzi Orthopaedic Institute, University of Milano, Milano, Italy.

Corresponding author

Dr Rabah Nedir

Ardentis Clinique Dentaire Vevey, Swiss Dental Clinics Group

Rue du Collège 3, 1800 Vevey, Switzerland

Tel. / Fax: + 41 58 234 00 10 / + 41 58 234 00 19

E-mail: rabah.nedir@ardentis.ch

Key words

atrophic maxilla, bone grafting, bone regeneration, crestal bone loss, dental implants;
long-term study, posterior maxilla, sinus osteotome, sinus lift

Running title

Sinus elevation without grafting.

Conflict of interest and source of funding statement

The authors declare that they have no conflict of interests.

No external funding, apart from the support of the authors' institutions, was available for this study.

ABSTRACT

Aim: To evaluate the long-term stability of peri-implant bone formation following implant placement without grafting into resorbed posterior maxillae.

Materials and methods: Twenty-five implants ≤ 10 mm were placed in 17 patients to rehabilitate atrophic maxillae by means of an osteotome sinus floor elevation procedure (OSFE) without grafting. Mean residual bone height was 5.4 ± 2.3 mm. Bone levels were evaluated at 1, 3 and 5 years using periapical radiographs.

Results: All implants fulfilled survival criteria and gained peri-implant bone (mean increase 3.2 ± 1.3 mm). Implant protrusion into the sinus decreased from 4.9 ± 1.9 mm after surgery to 1.5 ± 0.9 mm after 5 years. Mean crestal bone loss amounting 0.8 ± 0.8 mm stabilized over the 5-year observation interval. Twenty implants showed additional peri-implant bone gain following the 1-year control.

Conclusions: Implant rehabilitation of atrophic maxillae may be greatly simplified using implants ≤ 10 mm and the OSFE technique without grafting. Grafting material is not needed to gain at least 3 mm of bone in the atrophic maxilla. The procedure appears predictable with favorable long-term results.

Clinical Relevance

Scientific relevance for the study: The peri-implant bone formation after sinus augmentation without grafting is now accepted but few studies have documented the

long-term fate of this newly formed bone. Furthermore, long-term predictability of the OSFE technique without grafting in atrophic maxillae was not yet established.

Principal findings: The survival rate after a follow-up of 5 years was 100%. Grafting materials are not a pre-requisite for bone formation in the atrophic maxilla. Bone formed after the 1st year did not shrink; it tended to increase and reached 3.2 mm after 5 years.

Practical implications: Rehabilitation of the atrophied posterior maxilla can be greatly simplified by placing implants of 10 mm or less and using OSFE technique without grafting. The procedure seems to allow a reliable treatment with favorable long-term results.

INTRODUCTION

The posterior maxilla is a challenging site for dental implant rehabilitation. To increase bone height in this area, sinus elevation is often performed using lateral window access and sinus lift techniques to create bone for implant fixation. This newly formed bone provides sufficient primary stability and osseointegration can predictably be achieved. Numerous long-term follow-ups of implants placed using lateral window access and sinus lift techniques present survival rates greater than 90% (Raghoobar et al. 2001, Peleg et al. 2006, Bornstein et al. 2008, Kahnberg & Vannas-Löfqvist 2008, Blus et al. 2008). In most of these studies, crestal bone levels have been reported, however few evaluated bone changes within the sinus.

Summers (1994) introduced the osteotome sinus floor elevation (OSFE). In this technique, the Schneiderian membrane is elevated using osteotomes through a crestal approach and implants are simultaneously inserted. The use of the OSFE procedure improves implant primary stability and bone-to-implant contact (Zitzmann & Schärer 1998). In comparison with the lateral window access and sinus lift technique, the OSFE procedure is less invasive and less time-consuming; furthermore, it reduces post-operative discomfort (Brägger et al. 2004, Toffler 2004). Recent meta-analyses indicate that implants placed using the OSFE technique have the same prognosis than implants placed using conventional techniques (Emmerich et al. 2005, Shalabi et al. 2007). Unfortunately, controlled randomized clinical trials are lacking and only limited data on -sinus bone level changes are available (Berengo et al. 2004, Brägger et al. 2004, Deporter et al. 2005, Emmerich et al. 2005, Leblebicioglu et al. 2005, Nedir et al. 2006, 2009, Shalabi et al. 2007).

The need for sinus grafting has been questioned. Consistently, peri-implant bone formation can be achieved around implants within the sinus without bone grafting or biomaterials (Bruschi et al. 1998; Haas et al. 1998; Winter et al. 2003; Lundgren et al. 2004; Leblebicioglu et al. 2005, Nedir et al. 2006, 2009, Fermergård & Ånstrand 2008, Sohn et al. 2008, Lai et al. 2008). It has been suggested that a prerequisite for peri-implant bone formation is that implant apex serves as tent pole for the sinus membrane (Lundgren et al. 2004). Elevation of the Schneiderian membrane creates a compartment in which a fibrin clot is stabilized and is protected from external trauma other than intra-sinus air pressure. The clot has the potential to stimulate bone formation (Lundgren et al. 2004, Hatano et al. 2007). Histological examination in primates has shown newly formed trabecular bone in close apposition to implants and lining up the Schneiderian membrane (Palma et al. 2006).

Graft shrinkage/resorption appears to be a common problem following bone augmentation procedure also in the maxillary sinus (Hatano et al. 2004), particularly when autogenous bone is used (Keller et al. 1999). The use of biomaterials can decrease graft shrinkage/resorption (Zitzmann & Schärer 1998). Until now, no study has documented the long-term stability of peri-implant bone formation in the maxillary sinus without grafting. The objective of this prospective evaluation was to clinically and radiographically evaluate the long-term stability of peri-implant bone formation following implant placement into the maxillary sinus without grafting.

MATERIALS AND METHODS

Inclusion criteria

Inclusion criteria to enroll in this study were the following (Nedir et al. 2006, 2009):

- (1) Patients had to require implant treatment in the posterior maxilla;
- (2) The OSFE procedure had to be performed without grafting material;
- (3) 10 mm long implants were planned, shorter ones (6 and 8 mm) were admitted only in case of membrane perforation;
- (4) Residual bone height (RBH) was ≤ 8 mm on mesial or distal implant side;
- (5) Bone > 1 mm was required on mesial and distal sides to ensure implant stability;
- (6) Implants had to penetrate at least 2 mm into the sinus on mesial or distal implant side;
- (7) Implant primary stability had to be achieved;
- (8) Patients were not allowed to wear a removable partial denture during the healing period.

Between April and December 2003, 17 patients (14 women and 3 men) were enrolled in the study; the mean age was 54.2 ± 9.6 years (range 38-69 years).

Surgical and prosthetic procedures

Procedures were previously described (Nedir et al. 2006 and 2009). Clinical interventions took place in a private practice setting (Ardentis Clinique Dentaire Vevey, Switzerland). Using aseptic techniques the OSFE protocol without grafting including standard endosseous dental implants (Standard/2.8 mm collar/ and Standard Esthetic/1.8 mm collar/ SLA; $\text{Ø}4.1/\text{Ø}4.8 \times 10$ mm; Straumann AG, Basel, Switzerland) were used. All surgical procedures were performed under antibiotic prophylaxis initiated the day prior to surgery. A midcrestal incision was used for flap elevation, vertical or periosteal release incision was not performed. To gain access to the sinus floor, cortical bone perforation was performed using increasing diameter round burs ($\text{Ø} 1.4\text{-}3.1\text{mm}$). In type II bone, drilling up to 1mm away from the floor was

continued with the Ø 2.1, 2.8 and 3.5mm drills until final preparation. In type III and 4 IV bone, expansion osteotomes (Straumann AG, Basel, Switzerland) were used instead of the drills. In all cases, independent of bone density, a Ø 2.8mm sinus floor elevation osteotome (Straumann AG, Basel, Switzerland) was used.. Light tapping with a mallet carefully imploded the sinus floor into the sinus cavity elevating the Schneiderian membrane. The osteotomy was then enlarged with the Ø 3.5mm sinus floor elevation osteotome (Straumann AG, Basel, Switzerland) and the integrity of the membrane was controlled with an undersized Ø 2.1mm depth gauge. Implants were placed without tapping creating a space delineated by the elevated Schneiderian membrane and maintained by the implant apex.

At seating, primary stability was assessed by finger pressure exerted on the implant; all implants showed primary stability. Stability was achieved by the threads or by placing the implant deeper, resting against the flared neck. The flap was sutured around the implant neck (non-submerged) and the area was maintained prosthesis-free over the entire healing period. Clinical stability was assessed after 3 to 4 months of healing. When implants were stable, abutments were tightened with a 35 Ncm torque. When the implant resisted the applied torque, the classical prosthetic steps were conducted and porcelain fused to gold prosthesis were produced.

Clinical and radiographic evaluation

The study hypothesis was that peri-implant bone formation would occur in absence of grafting and that the bone volume would be stable over at least 5 years.

The survival criteria proposed by Buser et al. (1997) and Cochran et al. (2002) were used including: 1) absence of clinically detectable implant mobility, 2) absence of

pain or any subjective sensation, 3) absence of recurrent peri-implant infection, 4) absence of continuous radiolucency around the implant.

Periapical radiographs were taken with the long-cone technique pre- and post-implant placement, at 3 months, 6 months, and at 1, 3 and 5 years.. The radiographic analysis was performed by one investigator not involved in the surgical procedure. Radiographs obtained at implant placement and at 1, 3 and 5 years post-surgery were used; implant placement served as baseline. The following parameters were recorded at the mesial and distal side for each implant: 1) RBH at implant placement, 2) peri-implant sinus bone levels, 3) implant protrusion into the sinus, 4) peri-implant crestal bone levels. Figure 1 details the landmarks used for the radiographic recordings.

The radiographs were scanned in a digital format by a flatbed scanner (Epson Expression 1680 Pro, Wädenswil, Switzerland) at a resolution of 600 dpi. They were analyzed by a computerized measuring technique with image analysis software (Digora, Soredex, Helsinki, Finland) measuring the distance between 2 points. Given that the tips of two consecutive implant threads are separated by 1.25 mm, internal calibration was performed for each radiograph by measuring the distance between 3 implant threads (3.75 mm) at least. Whenever possible, 4 or 5 inter-thread measurements was used. Precision of the measuring system is 0.01 mm. In order to improve image analysis, image enhancement operations like sharpening, brightness, contrast and gamma adjustments were performed when necessary (Nedir et al. 2006, 2009).

Statistical analysis

Descriptive statistics, mean and standard deviation, were used to present sinus bone levels, protrusion into the sinus and crestal bone levels on recordings from the mesial and distal implant sides. A non-parametric Wilcoxon matched pairs signed-rank test was used to compare the various radiographic parameters at the follow-ups. The threshold value for statistical significance was set at $p < 0.05$. The Pearson linear correlation coefficient between two independent parameters was calculated for the protruding implant length and the sinus bone level gain.

RESULTS

Twenty-five implants, 15 Standard/10 Standard Esthetic, were placed; sixteen were placed in the molar area and 9 in the premolar. Twenty-one implants were 10 mm long. Membrane perforation led to placement of three 8 mm long implants and one 6 mm long implant. RBH at implant placement averaged 5.4 ± 2.3 mm (mesial 5.7 ± 2.6 mm, and distal 5.1 ± 1.9 mm). After a period of 3.1 ± 0.4 months, abutments were tightened with a torque of 35 Ncm. Implants reconstructions included 4 single crowns and 13 two-to-three units fixed partial dentures.

All 17 patients completed the scheduled follow-up visits up to the three-year control (Nedir et al. 2006, 2009). At the 5-year control, one patient with one implant was lost to follow-up because he moved away. No patient complained about pain, signs of suppuration or sinus-related pathology. Implants were clinically stable, leading to a survival rate of 100 %.

All the implants exhibited peri-implant bone formation (figure 2). Mean bone gain amounted to 3.2 ± 1.3 mm (mesial 3.2 ± 1.5 mm, distal 3.2 ± 1.2 mm), ranging from 1.0 to 4.7 mm. Six implants showed a bone gain exceeding 4 mm. Mean implant

protrusion length into the sinus amounted to 1.5 ± 0.9 mm (mesial 1.2 ± 1.0 mm, distal 1.8 ± 1.0 mm). Three implants became completely embedded into bone on the mesial side and did not protrude any more into the sinus; no implant showed a protrusion length greater than 4 mm. Mean crestal bone level amounted to 0.8 ± 0.8 mm (mesial 0.9 ± 0.9 mm, distal 0.7 ± 0.8 mm).

Twenty implants (83.3%) showed increased bone formation past the 1-year observation; bone gain was stabilized for 3 implants while one showed bilateral bone loss (mesial 0.5 mm, distal 0.2 mm). Starting from 2.5 ± 1.2 mm the first year, mean bone gain was 3.1 ± 1.5 mm after 3 years and 3.2 ± 1.3 mm after 5 years (figure 3) encompassing an overall mean increase of 0.7 ± 0.5 mm between year 1 and 5. Bone gain seemed to stabilize between the 3- and 5-year controls. The difference in peri-implant bone formation between year 1 and 3 ($p=0.0009$) and between year 1 and 5 ($p=0.0001$) was statistically significant whereas it was not significant between year 3 and 5 ($p=0.20$).

The protrusion length into the sinus decreased from 4.9 ± 1.9 mm at surgery to 2.2 ± 1.0 mm after 1 year, 1.8 ± 1.1 mm after 3 years and 1.5 ± 0.9 mm after 5 years. The difference in protrusion length between year 1, 3 and 5 was statistically significant (year 1-3 $p=0.009$; and year 1-5 $p=0.0001$; year 3-5 $p=0.001$). A positive correlation was noted between the post-operative protrusion and peri-implant de novo bone formation at year 5. The two parameters exhibited a linear relationship $y = 51x + 0.77$ and a correlation coefficient $r = 0.70$.

Crestal bone levels decreased significantly by 0.3 ± 0.4 mm from the 1-year control to reach 0.9 ± 0.8 mm at the 3-year control ($p=0.0016$). The 5-year control showed that this parameter stabilized at 0.8 ± 0.8 mm. The difference in crestal bone levels between 1 and 5 years was statistically significant ($p=0.001$).

None of the patients, including those exposed to membrane perforation, suffered from any related sinus pathology during the 5-year follow-up. The four implants sites that experienced membrane perforation showed a mean endo-sinus bone gain of 3.7 ± 0.9 mm and a mean crestal bone loss of 0.8 ± 0.6 mm after 5 years.

DISCUSSION

When using OSFE procedure the RBH was reported to influence survival rate. Rosen et al. (1999) reported a survival rate for 174 implants of 96% when RBH was ≥ 5 mm; this rate dropped to 85.7% when RBH was ≤ 4 mm. A meta-analysis reported a mean 3-year implant survival rate of 92.8% (19 studies, 4388 implants), but 91.8% when implants placed in RBH ≥ 8 mm were excluded (Tan et al. 2008). In the present study, 6 implants were placed in RBH < 4 mm and none of these implants failed. The reason may be the small sample size and the special care devoted to these cases.

Long-term preservation of crestal bone height around implants is one of the major success criteria. Crestal bone level remodeling was reported to occur predominantly during the unloaded healing phase and then to slightly decrease at a rate of about 0.1-0.2 mm per year (Albrektsson et al. 1986). In this study, crestal bone levels did not increase after 1 year; it stabilized after adaptation to the local biomechanical environment.

Peri-implant bone formation was observed; this confirms that a grafting material is not required to promote osteogenesis and maintain de novo bone volume. Peri-implant bone was mainly gained during the first year (2.5 ± 1.2 mm); it did not shrink with time, but rather increased up to 3.2 ± 1.3 mm. These findings were not in

agreement with previously reported data. (Hatano et al. 2004, Bragger et al. 2004). Isidor (2006) suggested that the 1-year bone gain is obtained from natural guided bone regeneration conditions, while the mechanical stimulus generated by functional occlusion leads to an increased bone remodeling.

The more implants protruded post-operatively into the sinus, the more peri-implant bone was gained at year 5. This finding in combination with the previously mentioned bone graft shrinkage addresses the question of the optimal bone height. The present data are suggesting that extended grafting is irrelevant for implant function. The height of the graft should match the expected implant apex and not be above it. Elevation of the sinus membrane ranges between 2.5 and 8.6 mm for transcrestal techniques, according to membrane thickness, elasticity, adhesion force between membrane and underlying bone (Pommer et al. 2009). Therefore, elevation height should take into account membrane resilience capacity and the bone filling likelihood following elevation. Above a certain height bone would not fill the created space and only perforation risk would increase. Thus the question of the optimal implant I protrusion into the sinus needs also to be addressed in relationship to the RBH.

The protocol called for placement of 10 mm long implants whatever the initial RBH was. When the membrane was perforated, shorter implants were inserted in order to contain membrane tearing and they performed well with similar bone gain. In a dog study, Sul et al. (2008) observed that when elevation was confined to 4 mm, the sinus membrane remained intact and leveled with the implant apex after 6 months. In contrast, the 8-mm protruding implants were not fully covered with an intact membrane and did not demonstrate greater bone formation than the 4-mm protruding ones.. Therefore, an implant protrusion > 4 mm into the sinus would not be relevant.

Without grafting, membrane lesion occurs mainly when the sinus membrane is lifted more than 5 mm (Tilotta et al. 2008). When perforation of the Schneiderian membrane happens, it might hinder stability of the fibrin clot (Sohn et al. 2008). In the present evaluation, perforation of the Schneiderian membrane had no effect on the long-term survival rate despite the perforated sites were not being sealed with collagen plugs to hold the clot into the sinus. Similarly, Schwartz-Arad et al. (2004) did not link membrane perforation and implant survival after a mean follow-up period of 43.6 months. In addition, present data showed that membrane perforation was amazingly not prejudicial to bone formation. This observation has already been reported by Haas et al. (1998) in a sheep model. The reason for that warrants further investigation.

The use of implants ≤ 10 mm in length in a private practice permits a safe and simpler implant therapy accessible to a high number of patients and practitioners (Toffler 2006). When RBH is 5 mm, the use of 6 to 10 mm long implants reduces the application span of sinus augmentation (Toffler, 2004). The present study showed that 4.9 mm sinus floor elevation above 5 mm RBH allows osseointegration and early loading. This elevation height allowed gaining 3.2 mm of bone height, sufficient for long-term stability. The combination of implants ≤ 10 mm in length and regenerative properties of the bone beneath the sinus floor may allow treating almost all clinical situations in a simple and straightforward way. Nevertheless, despite their high success rates, some practitioners are reluctant to use implants ≤ 10 mm. By using longer implants, they are confronted to higher implant protrusion within the sinus and have to seek for more than 3-4 mm of bone gain; in these situations, the use of grafting can be advocated.

CONCLUSION

Implant rehabilitation of edentulous atrophied posterior maxilla can be greatly extended and simplified using implants ≤ 10 mm in length and the OSFE technique without grafting. Peri-implant bone formed after 1 year did not shrink; it tended to increase and reached 3.2 mm after 5 years. This study confirms the potential of healing and bone formation of the posterior maxilla beneath the sinus membrane. Grafting is not a pre-requisite for bone formation in atrophic maxilla. The procedure appears to be predictable and allows treating the compromised posterior maxilla with reliable long-term results.

REFERENCES

- Albrektsson, T., Zarb, G.A., Worthington, P. & Eriksson, A.R. (1986) The long-term efficacy of currently used dental implants: a review and proposed criteria of success. *The international Journal of Oral and Maxillofacial Implants* **1**, 11-25.
- Berengo, M., Sivoletta, S., Majzoub, Z. & Cordioli, G. (2004) Endoscopic evaluation of the bone-added osteotome sinus floor elevation procedure. *The international Journal of Oral and Maxillofacial Implants* **33**,189-194.
- Blus, C., Szmukler-Moncler, S., Salama, M., Salama, H. & Garber, D (2008). Sinus bone grafting procedures using ultrasonic bone surgery: 5-year experience. *International Journal of Periodontics and Restorative Dentistry* **29**,161-167.
- Bornstein, M.M., Chappuis, V., von Arx, T. & Buser, D. (2008) Performance of dental implants after staged sinus floor elevation procedures: 5-year results of a prospective study in partially edentulous patients. *Clinical Oral Implants Research* **19**,1034-1043.

Brägger, U., Gerber, C., Joss, A., Haenni, S., Meier, A., Hashorva, E. & Lang, N.P.

(2004) Patterns of tissue remodeling after placement of ITI® dental implants using an osteotome technique: a longitudinal radiographic case cohort study.

Clinical Oral Implants Research **15**,158-166.

Bruschi, G.B., Scipioni, A., Celesini, G. & Bruschi E. (1998) Localized management

of sinus floor with simultaneous implant placement. A clinical report. *The*

International Journal of Oral & Maxillofacial Implant **13**,219-226.

Buser, D., Mericske-Stern, R., Bernard, J.P., Behneke, A., Behneke, N., Hirt, H.P.,

Belser, U.C. & Lang NP. (1997) Long-term evaluation of non-submerged ITI implants. Part 1: 8-year life table analysis of a prospective multi-center study with

2359 implants. *Clinical Oral Implants Research* **8**,161-172.

Cochran, D.L., Buser, D., ten Bruggenkate, C., Weingart, D., Taylor, T.M., Bernard,

J.P., Peters, F. & Simpson, J.P. (2002) The use of reduced healing times on ITI® implants with a sandblasted and etched (SLA) surface: early results from clinical trials on ITI® SLA implants. *Clinical Oral Implants Research* **13**,144-153.

Deporter, D.A., Caudry, S., Kermalli, J. & Adegbembo, A. (2005) Further data on the

predictability of the indirect sinus elevation procedure used with short, sintered,

porous-surfaced dental implants. *International Journal of Periodontics and Restorative Dentistry* **25**,585-593.

Emmerich, D., Att, W. & Stappert, C. (2005) Sinus floor elevation using osteotomes:

a systematic review and meta-analysis. *Journal of Periodontology* **76**,1237-1251.

Fermergård, R. & Astrand, P. (2008) Osteotome sinus floor elevation and

simultaneous placement of implants--a 1-year retrospective study with Astra Tech

implants. *Clinical Implant Dentistry and Related Research* **10**,62-69.

- Haas, R., Donath, K., Födinger, M. & Watzek, G. (1998) Bovine hydroxyapatite for maxillary sinus grafting: comparative histomorphometric findings in sheep. *Clinical Oral Implants Research* **9**,117-122.
- Hatano, N., Shimizu, Y. & Ooya K. (2004) A clinical long-term radiographic evaluation of graft height changes after maxillary sinus floor augmentation with a 2:1 autogenous bone/xenograft mixture and simultaneous placement of dental implants. *Clinical Oral Implants Research* **15**,339-345.
- Hatano, N., Sennerby, L. & Lundgren, S. (2007) Maxillary Sinus Augmentation Using Sinus Membrane Elevation and Peripheral Venous Blood for Implant-Supported Rehabilitation of the Atrophic Posterior Maxilla: Case Series. *Clinical Implant Dentistry and Related Research* **9**,150-155.
- Isidor, F. (2006) Influence of forces on peri-implant bone. *Clinical Oral Implants Research* **17** Suppl. 2,8-18.
- Kahnberg, K.E. & Vannas-Löfqvist, L. (2008) Sinus lift procedure using a 2-stage surgical technique: I. Clinical and radiographic report up to 5 years. *The International Journal of Oral and Maxillofacial Implants* **23**,876-884.
- Keller, E.E., Tolman, D.E. & Eckert, S. (1999) Surgical-prosthetic reconstruction of advanced maxillary bone compromise with autogenous onlay block bone grafts and osseointegrated endosseous implants: a 12-year study of 32 consecutive patients. *The International Journal of Oral and Maxillofacial Implants* **14**, 197–209.
- Lai, H.C., Zhang, Z.Y., Wang, F., Zhuang, L.F. & Liu, X. (2008) Resonance frequency analysis of stability on ITI implants with osteotome sinus floor elevation technique without grafting: a 5-month prospective study. *Clinical Oral Implants Research* **19**,469-475.

- Leblebicioglu, B., Ersanli, S., Karabuda, C., Tosun, T. & Gokdeniz, H. (2005) Radiographic evaluation of dental implants placed using an osteotome technique. *Journal of Periodontology* **76**,385-390.
- Lundgren, S., Andersson, S., Gualini, F. & Sennerby, L. (2004) Bone reformation with sinus membrane elevation: a new surgical technique for maxillary sinus floor augmentation. *Clinical Implant Dentistry and Related Research* **6**,165-173.
- Nedir, R., Bischof, M., Vazquez, L., Szmukler-Moncler, S. & Bernard, J.P. (2006) Osteotome sinus floor elevation without grafting material: a 1-year prospective pilot study with ITI implants. *Clinical Oral Implants Research* **17**,679-686.
- Nedir, R., Bischof, M., Vazquez, L., Nurdin, N., Szmukler-Moncler, S. & Bernard, J.P. (2009) Osteotome sinus floor elevation without grafting material: 3-year results of a prospective pilot study. *Clinical Oral Implants Research* **20**,701-707.
- Peleg, M., Garg, A.K. & Mazor, Z. (2006) Predictability of simultaneous implant placement in the severely atrophic posterior maxilla: A 9-year longitudinal experience study of 2132 implants placed into 731 human sinus grafts. *The International Journal of Oral and Maxillofacial Implants* **21**,94-102.
- Palma, V.C., Magro-Filho, O., de Oliveria, J.A., Lundgren, S., Salata, L.A. & Sennerby L. (2006) Bone reformation and implant integration following maxillary sinus membrane elevation: an experimental study in primates. *Clinical Implant Dentistry and Related Research* **8**,11-24.
- Pommer, B., Unger, E., Sütö, D., Hack, N. & Watzek, G. (2009) Mechanical properties of the Schneiderian membrane in vitro. *Clinical Oral Implants Research* **20**,633–637.

- Raghoobar, G.M., Timmenga, N.M., Reintsema, H., Stegenga, B. & Vissink, A. (2001) Maxillary bone grafting for insertion of endosseous implants: results after 12-124 months. *Clinical oral Implants Research* **12**,279-286.
- Rosen, P.S., Summers, R., Mellado, J.R., Salkin, L.M., Shanaman, R.H. & Marks, M.H. (1999) The bone-added osteotome sinus floor elevation technique: multicenter retrospective report of consecutively treated patients. *International Journal of Oral and Maxillofacial Implants* **14**,853–858.
- Schwartz-Arad, D., Herzberg, R. & Dolev, E. (2004) The prevalence of surgical complications of the sinus graft procedure and their impact on implant survival. *Journal of Periodontology*. **75**,511-516.
- Shalabi, M.M., Manders, P., Mulder, J., Jansen, J.A. & Creugers, N.H.J. (2007) A meta-analysis of clinical studies to estimate the 4.5-year survival rate of implants placed with the osteotome technique. *The International Journal of Oral Maxillofacial Implants* **22**,110-116.
- Sohn, D.S., Lee, J.S., Ahn, M.R. & Shin, H.I. (2008) New bone formation in the maxillary sinus without bone grafts. *Implant Dentistry* **17**,201-209.
- Sul, S.H., Choi, B.H., Li, J., Jeong, S.M. & Xuan, F (2008) Effects of sinus membrane elevation on bone formation around implants placed in the maxillary sinus cavity: an experimental study. *Oral Surgery Oral Medicine Oral Pathology Oral Radiology and Endodontics* **105**,684-687.
- Summers, R.B. (1994) The osteotome technique. Part 3. Less invasive methods in elevation of the sinus floor. *Compendium of Continuous Education in Dentistry* **15**,698-708.
- Tan, W.C., Lang, N.P., Zwahlen, M. & Pjetursson, B.E. (2008) A systematic review of the success of sinus floor elevation and survival of implants inserted in

combination with sinus floor elevation. Part II: Transalveolar technique. *Journal of Clinical Periodontology* **35** Suppl. 8,241-254.

Tilotta, F., Lazaroo, B.& Gaudy, J.F. (2008) Gradual and safe technique for sinus floor elevation using trephines and osteotomes with stops: a cadaveric anatomic study. *Oral Surgery Oral Medicine Oral Pathology Oral Radiology and Endodontics* **106**,210-216.

Toffler, M. (2004) Minimally invasive sinus floor elevation procedures for simultaneous and staged implant placement. *The New York State Dental Journal* **70**,38-44.

Toffler M. (2006) Treating the atrophic posterior maxilla by combining short implants with minimally invasive osteotome procedures. *Practical Procedures and Aesthetic Dentistry* **18**,301-8.

Winter, A.A., Pollack, A.S. & Odrich, R.B. (2003) Sinus/alveolar crest tenting (SACT): a new technique for implant placement in atrophic maxillary ridges without bone grafts or membranes. *International Journal of Periodontics and Restorative Dentistry* **23**,557-565.

Zitzmann, N.U. & Schärer, P. (1998) Sinus elevation procedures in the resorbed posterior maxilla. Comparison of the crestal and lateral approaches. *Oral Surgery Oral Medicine Oral Pathology Oral Radiology and Endodontics* **85**,8-17.

FIGURE CAPTIONS

Fig. 1. Schematic drawing of the parameters measured on radiographs (Nedir et al. 2006, 2009a):

A: residual bone height under the sinus.

B: distance from the most coronal implant thread to the most apical implant-bone contact. Increase in B distance corresponds to endo-sinus bone gain.

C: implant length protruding in the sinus.

D: distance from the most coronal bone-implant contact to the most apical implant thread. Decrease in D distance corresponds to crestal bone loss.

Fig. 2. Radiographic evolution of sinus demarcation.

(a) before surgery,

(b) immediately after surgery ($t=0$) (Nedir et al. 2006),

(c) year 1 (Nedir et al. 2006),

(d) year 3,

(e) year 5.

Fig. 3. Crestal bone level, peri-implant bone formation and protrusion length measured immediately after surgery ($t=0$), at year 1, year 3 and year 5.

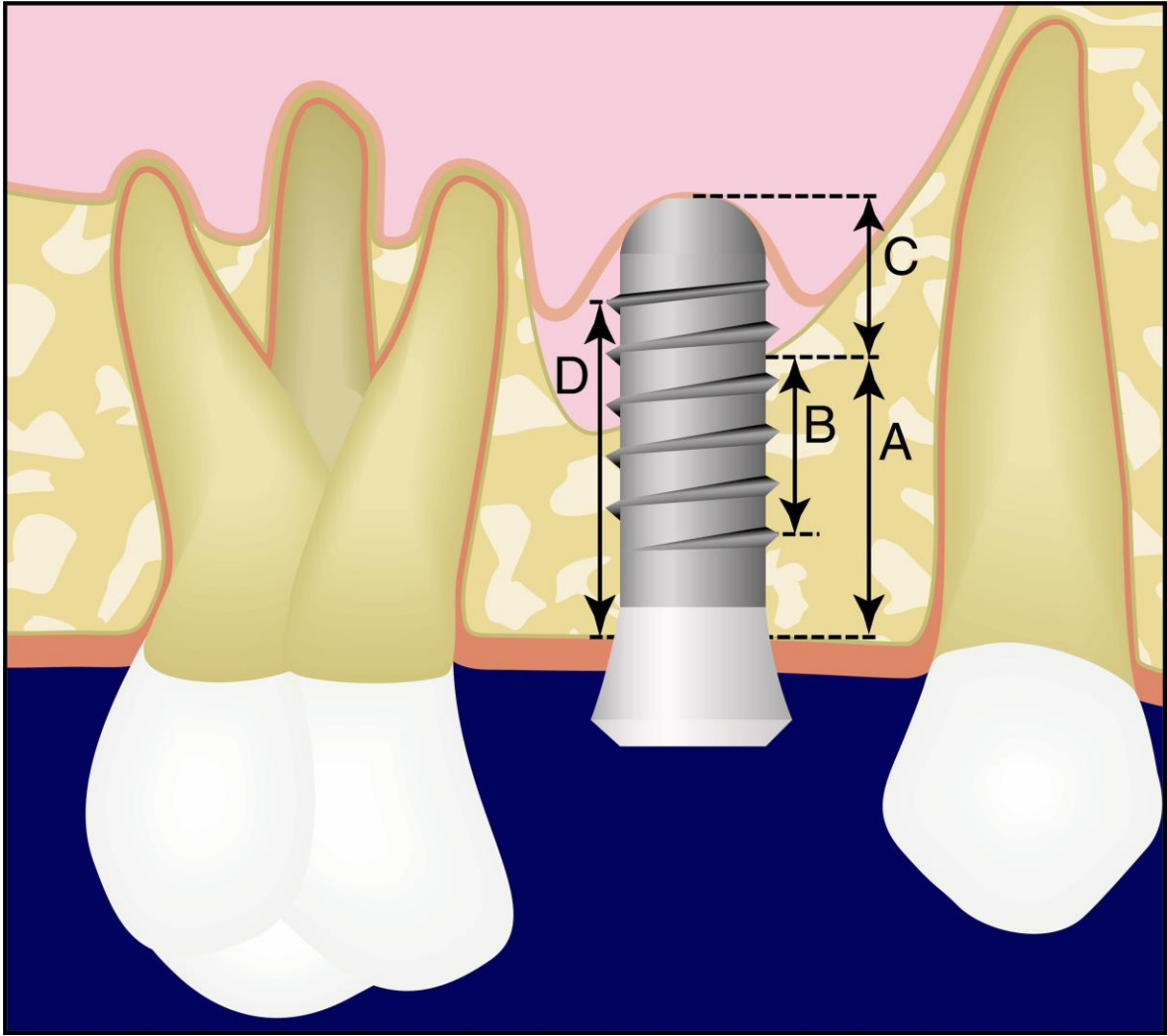


Fig. 1. Schematic drawing of the parameters measured on radiographs (Nedir et al. 2006, 2009a):

A: residual bone height under the sinus.

B: distance from the most coronal implant thread to the most apical implant-bone contact. Increase in B distance corresponds to endo-sinus bone gain.

C: implant length protruding in the sinus.

D: distance from the most coronal bone-implant contact to the most apical implant thread. Decrease in D distance corresponds to crestal bone loss.

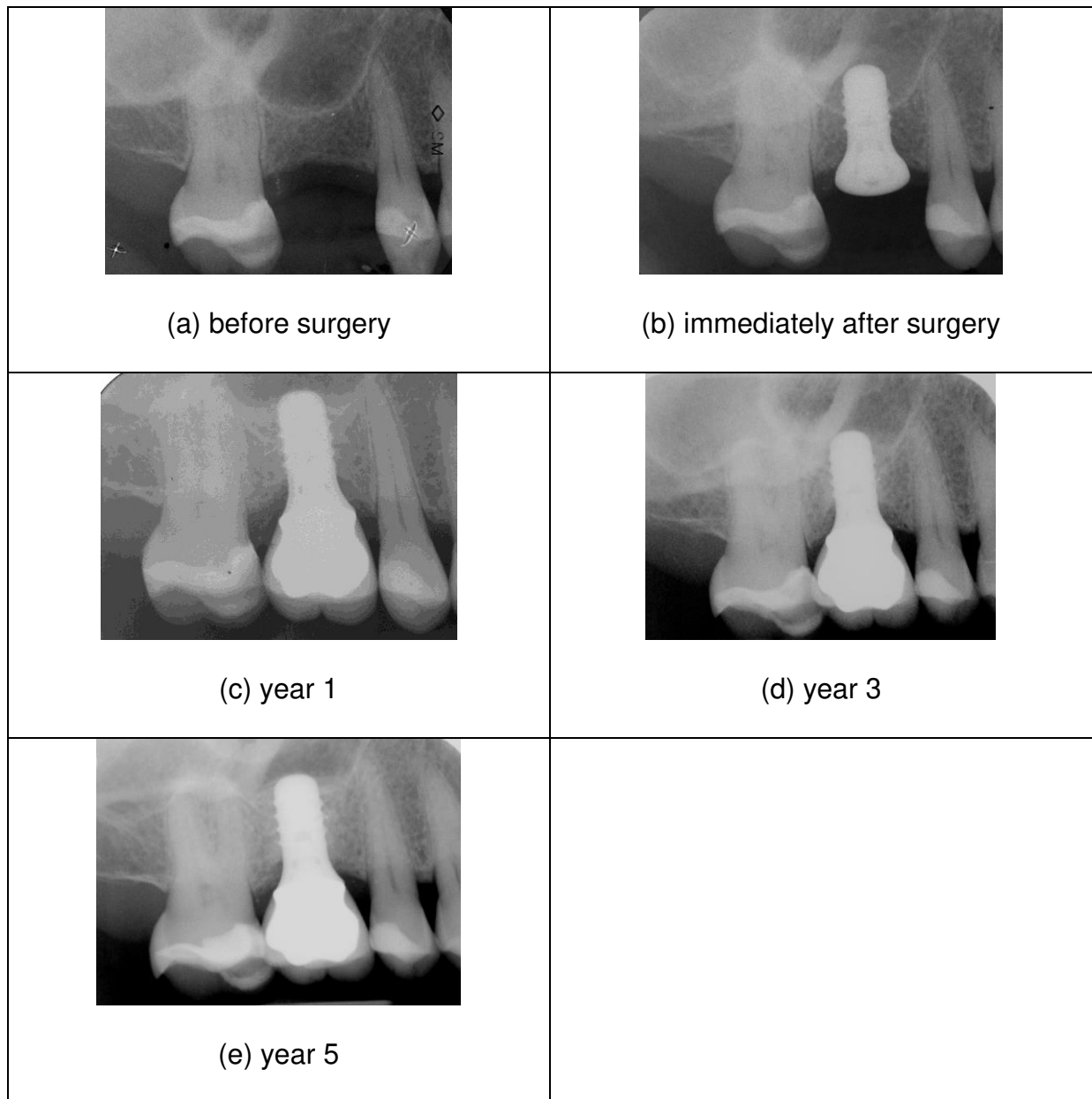


Fig. 2. Radiographic evolution of sinus demarcation.

(a) before surgery,

(b) immediately after surgery ($t=0$) (Nedir et al. 2006),

(c) year 1 (Nedir et al. 2006),

(d) year 3,

(e) year 5.

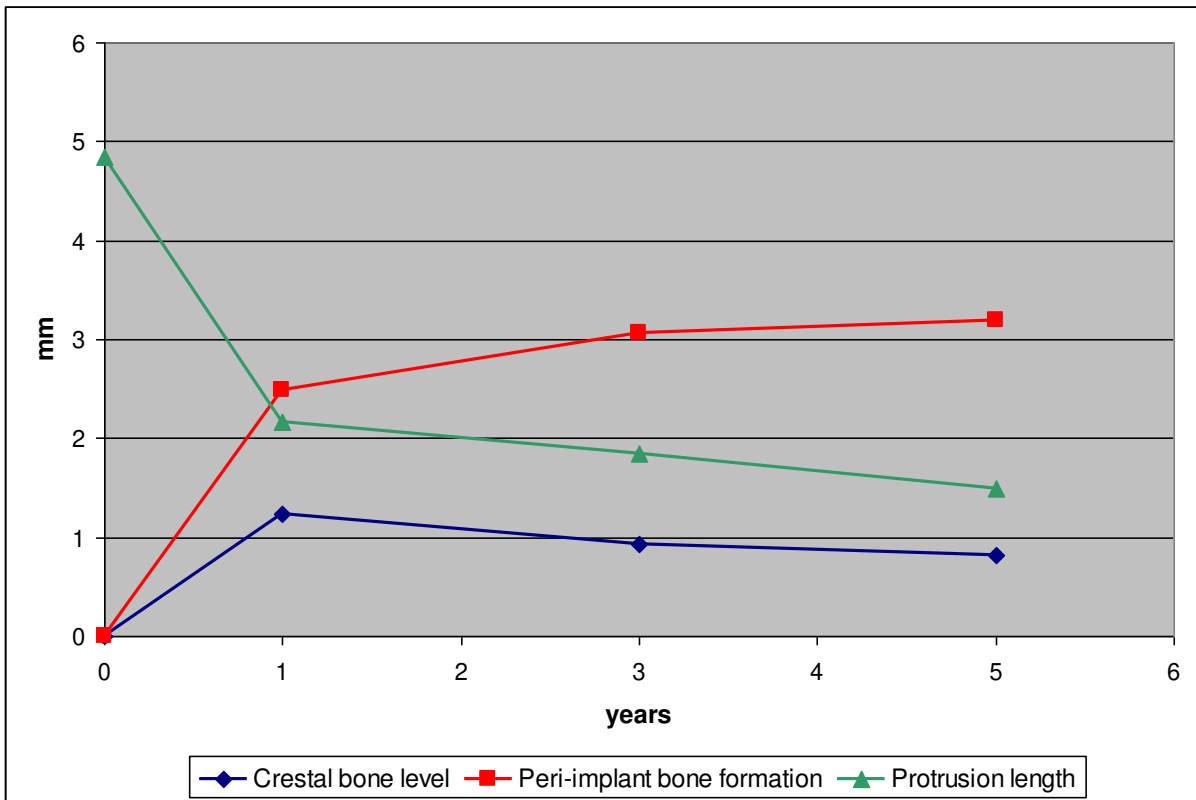


Fig. 3. Crestal bone level, peri-implant bone formation and protrusion length measured immediately after surgery (t=0), at year 1, year 3 and year 5.