

Graft shrinkage and survival rate of implants after sinus floor elevation using a nano-crystalline hydroxyapatite embedded in silica gel matrix: A 1-year prospective study.

Marc EL HAGE, DMD ^{1,2}, Semaan ABI NAJM, DMD ^{2,3}, Mark BISCHOF, DMD ^{2,4}, Rabah NEDIR, DMD ^{2,4}, Jean-Pierre CARREL, MD, DMD ⁴, Jean-Pierre BERNARD, MD ⁵

¹ Lecturer, Department of Oral Surgery, Oral Medicine, Oral and Maxillofacial Radiology, School of Dental Medicine, University of Geneva, Geneva, Switzerland

² Medical Director, Ardentis Clinique Dentaire, Swiss Dental Clinics Group, Switzerland

³ Senior Lecturer, Department of Oral Surgery, Oral Medicine, Oral and Maxillofacial Radiology, School of Dental Medicine, University of Geneva, Geneva, Switzerland

⁴ Assistant Professor, Department of Oral Surgery, Oral Medicine, Oral and Maxillofacial Radiology, School of Dental Medicine, University of Geneva, Geneva, Switzerland

⁵ Professor and Dean, Department of Oral Surgery, Oral Medicine, Oral and Maxillofacial Radiology, School of Dental Medicine, University of Geneva, Geneva, Switzerland

Corresponding author: Marc EL HAGE, DDS, Department of Oral Surgery, Oral Medicine, Oral and Maxillofacial Radiology, School of Dental Medicine, University of Geneva, 19 Rue Barthelemy-Menn, 1205 Geneva, Switzerland, Phone: 41 (22) 3794026, Fax: 41 (22) 3794082, Email: marc.elhage@unige.ch

Conflicts of interest and source of funding: none were declared.

Graft shrinkage and survival rate of implants after sinus floor elevation using a nano-crystalline hydroxyapatite embedded in silica gel matrix: A 1-year prospective study.

Abstract

Objectives: The aims of this study were 1) to evaluate the vertical shrinkage percentage of nano-crystalline hydroxyapatite embedded in silica gel (NanoBone[®]) used for maxillary sinus floor elevation (SFE) and 2) to determine the survival rate of the implants one year after placement in the healed grafted sinuses.

Materials and Methods: Eleven maxillary sinuses were augmented in eight patients with NanoBone[®]. After a healing period averaging 14.42 months, 19 implants were placed and followed with clinical and radiographic evaluation. Panoramic radiographs were taken immediately after SFE and at 12 months post grafting. Measurements of changes in height were made by a computerized measuring technique using an image editing software.

Results: The mean graft height shrinkage percentage at 12 months after surgery was 8.84% (± 5.32). One implant was lost before loading. All the 18 remaining osseointegrated implants received the prosthetic rehabilitation and were controlled after 3 months of functional loading. The implant survival rate at the one-year interval was 94.74%.

Conclusions: 100% NanoBone[®] alloplastic graft used in lateral SFE procedures presented limited height shrinkage. Implants placed in these grafted sinuses showed survival rates similar to that found in published data. These results should be interpreted cautiously considering the study's reduced sample size.

Key words: alloplast, hydroxyapatite, dental implant, maxillary sinus floor elevation, bone height.

Introduction

In the posterior maxilla, insufficient bone volume is frequently encountered due to the pneumatisation of the maxillary sinus together with crestal bone resorption after tooth loss.¹ This can hinder dental implant placement in this region. Maxillary sinus floor elevation (SFE) is a widely used surgical procedure for regaining adequate bone height before implant placement. Commonly, the sinus floor is augmented with autogenous bone or biomaterials or a combination of both.¹

Autogenous bone has long been considered the gold standard grafting material because of its osteoinductive and osteoconductive properties. In general, bone substitutes have no osteoinductive potential but are considered to provide a scaffold for optimal bone growth.² In a recent literature review, different materials used in SFE procedures were examined.¹ It was noted that intra-oral donor sites are convenient but yield limited volume. Extra-oral donor sites increase surgical complexity and are associated with significant (and underreported) morbidity and scarring.¹ Therefore alternative grafting materials have been developed. Because of the human and animal origin of allografts and xenografts, alloplasts are alternatively used.³ Of those alloplasts, calcium phosphate bioceramics, e.g. hydroxyapatite (HA) or beta-tricalciumphosphate (Beta-TCP) or a combination of both, are frequently employed. Because of high temperature processing, these materials present increased density and less porosity. This could negatively influence their potential osteoconductivity.⁴

A nano-crystalline HA embedded in silica gel matrix (NanoBone[®], Artoss, Rostock, Germany) was developed.^{5,6} This material presents a large internal surface (about 84 m²/g) due to the interconnecting pores between 10 and 20 nm of the silica gel. In addition, the HA

granules show a rough surface leading to a porous structure ranging from micrometer to millimeter in dimension. An animal study showed a significantly better biological behavior of the new high-porous bone replacement material (NanoBone[®]) in comparison with the conventionally sintered ceramics.⁷ Furthermore, the authors noted that bone formation and resorption rates after implantation of the nano-crystalline HA were higher compared with other commercial available HAs, TCPs, or gelatine sponges (control group). Other studies revealed signs of osteoconduction as well as osteoinduction in the histological and immunohistochemical investigations of human and animal biopsies.^{4,7,8} Additionally, high levels of biocompatibility and angiogenic response were reported.⁹ In recent histological investigations of human biopsies from sinus augmentations using the nanocrystalline HA, newly formed bone although in limited quantities was already found at 3 months of healing,^{10,11} and new trabecular bone was found at 6 months of healing.^{10,12} Well-mineralized regenerated bone with lamellar parallel-fibred structure and Haversian systems surrounded the residual NanoBone[®] particles.¹¹ Moreover, it was observed that NanoBone[®] has osteoconductive and biomimetic properties and is integrated into the host's physiological bone turnover at a very early stage.⁴

Clinical and radiographic outcomes of sinus grafts have been studied.¹³⁻²⁴ Of particular interest is whether graft height and volume are maintained over the long term. A clinical study was conducted to evaluate the factors affecting changes in sinus graft height between and above implants.²³ It concluded that the type of the grafting material is the main factor affecting changes in height.

Therefore, the first aim of the present prospective study was to evaluate the vertical shrinkage percentage of nano-crystalline HA embedded in silica gel (NanoBone[®]), twelve months after

maxillary SFE and before implant placement. The second aim of the study was to determine the survival rate of the implants at one-year post placement in the healed grafted sinuses.

Materials and methods

Patient selection

Between July 2006 and July 2009, eight partially edentulous patients scheduled for a two-stage SFE procedure were admitted to the study. Patients were referred to the Department of Oral Surgery and Oral Medicine by their private dentist or by another department at the University of Geneva. Patient selection included candidates presenting bone defects requiring SFE, and only excluded patients with severe health problems. All included patients had a remaining alveolar bone height of ≤ 3 mm determined by panoramic radiographs. All patients signed an informed consent and were treated according to the guidelines of the World Medical Association (WMA) in the declaration of Helsinki (2008). The group comprised 5 women and 3 men with a mean age of 53 years (range 37-65 years).

Surgical procedures

The surgical procedures were carried out under local anesthesia (Ubistesin™, 3M ESPE AG, Germany) by either one of three experienced surgeons. All patients received perioperative antibiotic prophylaxis with Clindamycine (Dalacin® C; Pfizer SA, Zürich, Switzerland) 3 x 300 mg/day for 5 days, starting with 2 x 300 mg, 1 h before surgery.

Maxillary SFE

A mucoperiosteal flap was elevated after a crestal incision and two vertical releasing incisions were performed to expose the lateral wall of the sinus. A lateral bony window was

outlined and completely removed with a 3 mm diameter round diamond bur. The Schneiderian membrane was carefully reflected, a bioresorbable porcine collagen membrane (Bio-Gide[®], Geistlich Pharma AG, Switzerland) was placed along it, and the space was filled with 0.6 ml to 2.4 ml of 0.6 mm granules of NanoBone[®]. Blood was previously collected from the surgical site and mixed with the grafting material. The grafted area was then covered with a Bio-Gide[®] membrane. Tension-free closure was accomplished with interrupted polyamide 5.0 sutures (Suturamid[®], B. Braun Aesculap, Sempach, Switzerland).

Implant insertion

After an average healing period of 14.42 months (± 3.69), transmucosal Straumann[®] implants (Institute Straumann AG, Basel, Switzerland) were placed. Implant bed preparations and biopsies were realized in the grafted area using a trephine drill with an external diameter of 3.5 mm (Straumann[®] Trephine Drill, Institute Straumann AG, Basel, Switzerland). The results from the histological analysis of the biopsies are the subject of a separate study.

Prosthetic treatment

Eight weeks after placement, implant stability was measured with an electromechanical Periotest device (Periotest Classic[®], Medizintechnik Gulden, Bernsheim, Germany), according to the manufacturer's working instructions. The device measuring values ranging from -8 (solid osseointegration) to +50 (poor osseointegration). Subsequently, prosthetic rehabilitation was initiated.

Survival criteria

Implant survival was assessed at the 1-year control following the criteria proposed by Buser

et al.²⁵ and Cochran et al.²⁶ These criteria included the following: (1) absence of clinically detectable implant mobility, (2) absence of pain or any subjective sensation, (3) absence of recurrent peri-implant infection and (4) absence of continuous radiolucency around the implant.

Radiographic analysis

The aim of the radiographic analysis was to evaluate the post augmentation graft shrinkage percentage. During the follow-up period, at least four radiographic examinations were made in each patient. For the grafted volume evaluation, panoramic radiographs were taken immediately after surgery (T_{0s}) and 12 months (range 11.3 - 13.3 months) after surgery (T_{1s}). All the panoramic radiographs were taken using a Scanora[®] unit (Soredex, Orion Corporation Ltd, Helsinki, Finland). For implant control, either panoramic or periapical radiographs with the paralleling technique were taken at the time of implant placement (T_{0i}) and 1 year after placement (T_{1i}). All radiographs were scanned in a digital format by a flatbed scanner (Epson Expression 1680 Pro, Wadenswil, Switzerland) at a resolution of 600 dpi and were saved as *.tiff* format files. They were then analyzed by a computerized measuring technique with an image editing software (Adobe[®] Photoshop[®] CS4 Extended, Adobe Systems Incorporated, Washington, USA). "Adobe product screenshot(s) reprinted with permission from Adobe Systems Incorporated".

Image processing

The following digital procedures were applied to all examined radiographs. Image mode was set to grayscale and 8 Bits / Channel. Both the T_{0s} and T_{1s} panoramic radiographs were copied on a single *.psd* file and separated as two layers. The region of interest (ROI) was then outlined on each radiograph using the crop tool. It was defined as follows: mesially, two neighboring teeth to the grafted sinus; distally, a vertical line passing 2 mm beyond the

maxillary tuberosity; crestally, the occlusal plane of the neighboring teeth; apically, a horizontal line passing 1 cm above the grafted sinus floor (Fig. 1). The two layers were only then superposed and equalized in order to discard grayscale variation outside the ROI. The superposition was done following the anterior and posterior sinus walls, the neighboring teeth and the maxillary tuberosity (Fig. 2, a).

Measurements

Three horizontal lines were set on the T_{0s} and T_{1s} layers. The first two lines were set on layer T_{0s}, one passing through the highest point of the crestal bone (CB) and the other passing through the highest point of the augmented floor (AF₀) (Fig. 2, b). The third line was set on layer T_{1s}, passing through the highest point of the actual augmented floor (AF₁) (Fig. 2, c). The T_{0s} and T_{1s} layers being superposed, measurement of the distance in pixels between CB and AF₀ (AF_{0d}) and CB and AF₁ (AF_{1d}) were taken with the ruler tool (Fig. 2, d). The ratio AF_{1d}/AF_{0d} was then calculated for each SFE case. A ratio value less than 1.0 indicates that the grafted sinus floor is more cervically positioned at T_{1s} than at T_{0s}, and that the graft shrank during this period. The graft shrinkage percentage was obtained by multiplying the ratio by 100.

Results

Eleven SFE procedures were conducted in eight patients. A total of nineteen implants were placed in 10 sinuses. Of those nineteen implants, 17 implants were placed in distally shortened arches, and 2 implants in single tooth gaps. Four implants were rehabilitated with single crowns, 13 implants were rehabilitated with splinted crowns and one implant was rehabilitated with a tooth-to-implant fixed partial denture. Implant length was 10 mm in all the cases (Table 1).

Complications and morbidity

During the SFE procedures, no macroscopic perforation of the sinus membrane was noted in any of the cases. Two postoperative wound infections occurred after the augmentation procedures. In the first case, painful swelling of the posterior maxillary area appeared 7 weeks after augmentation and was treated with Clindamycin (Dalacin® C; Pfizer SA, Zürich, Switzerland) at 300 mg 3 times daily for 5 days and local irrigation with 3% hydrogen peroxide (H₂O₂). Nonetheless, residual swelling remained for 6 months with no painful symptomatology. During surgical re-entry, a macroscopic perforation surrounded by granulation tissue was noted and re-augmentation was conducted. Implant insertion took place 8 months later. Consequently, this case was excluded from the study. In the second case, the patient also complained of painful swelling at the surgical area 3 weeks after sinus augmentation. The infectious incident was treated with Clindamycin (Dalacin® C; Pfizer SA, Zürich, Switzerland) at 300 mg 3 times daily for 5 days and local irrigation with 3% hydrogen peroxide (H₂O₂). The infection being successfully treated, two implants were placed 10 months later. Radiographic control 4 months after implant placement revealed that one of the implants (site 26) had migrated apically. Re-entry was conducted for the removal of the failed implant. No implant replacement was scheduled, and a tooth-to-implant fixed partial denture was made.

Radiographic analysis

The mean graft height shrinkage percentage at 12 months (range 11.3 – 13.3 months) after surgery was 8.84% (\pm 5.32) (Table 2).

Implant survival

Of 19 placed implants, 18 survived (Table 3). The cumulative survival rate at the one-year

interval was 94.74%. All 18 implants received the prosthetic rehabilitation and were controlled after 3 months of functional loading.

Discussion

Various radiographic methods were used to assess the position of the maxillary sinus floor. Most authors used panoramic radiographs.^{13,16,17,19-24} Tomographic Scanora[®],¹⁶ magnetic resonance imaging^{27,28} and computed tomography (CT) scanning^{15,17,18,20} were also employed. Studying graft sinus height in 3-dimensions can be carried out with a CT-scan or cone beam CT (CBCT).²² However, the same authors state that this is a more expensive radiographic technique that considerably increases the level of radiation for the patient. The dose given to patients with a CT-scan is evaluated as roughly 150–300 times that of a panoramic radiograph.^{27,29} On the other hand, panoramic radiographs can be used for bone height measurements but do not allow for volume measurements.²¹ Consequently, bone height measurement with panoramic radiographs has been conducted in this study to evaluate graft height shrinkage. This technique seemed sufficient since no three-dimensional volume evaluation was sought.

Radiographic evaluation of graft height changes after maxillary SFE was addressed in the literature through a few short-term studies^{15,17} and some long-term studies.^{13,14,16,18-24} In a study including a total of 191 patients who underwent maxillary SFE and were radiographically followed for up to about 10 years, it was noted that the ratio of grafted sinus height to original sinus height (GSH/OSH) significantly decreased between 0–6 months and 7–12 months, displaying no significant change thereafter.¹⁹ A study compared the vertical dimensional changes regarding graft height with a long-term follow-up of at least 4.5 years, in patients treated with two different grafting materials used in maxillary SFE procedures.²¹

The authors noted that after an initial height reduction in the first 1.5 year, subsequent changes were minimal. They added that most shrinkage took place in the first time period (< 7.5 months). Another study showed that after a mean vertical bone loss of 1.3 mm during the first year post grafting, only minimal loss was observed during the second and the third year.¹⁸ In this study, the aim was to evaluate the graft shrinkage percentage relative to the specific grafting material, in the absence of implants. The literature shows that graft shrinkage takes place mainly in the first year, thus the 12-months timeframe set for this study seemed justifiable.

In a study,²³ the authors reviewed different published data^{15-18,21,23} and calculated the corresponding shrinkage percentages of several graft types. A shrinkage percentage of 48% was noted during the first 6 months when autogenous bone was used for maxillary SFE.¹⁵ Other authors evaluated autogenous bone graft shrinkage and noted a value of 28.95% (27.8% near implant and 30.1% between implants)²¹ and 18.2% (13% above and 23.4% between implants).²³ Another study noted a 7% initial vertical shrinkage during the first year after grafting and before implant placement.¹⁸ Bone substitutes shrinkage percentages were also the subject of some studies.^{17,21,23} A radiographic and histomorphometric study was conducted to evaluate various SFE procedures and grafting.¹⁷ Results showed that bone substitutes (BHA, HA, and beta-TCP) presented shrinkage percentages of 6.19% (range 4.6-7.7 %). Other authors estimated a graft height reduction of 3.25% for bovine xenograft (6.5% between and 0% above implants).²³ Another study noted a shrinkage percentage of 39.55% for bone substitutes (38.9% near implant and 40.2% between implants).²¹ In two different studies aiming at evaluating the radiographic dimensional changes of the bone graft in maxillary sinuses augmented with autogenous bone and bovine HA in a 20:80 mixture, the authors estimated the shrinkage percentage as less than 10%¹⁶ and of 9.4 (6.1% above and

12.7% between the implants)²³. In the present study, our main objective was to determine the height shrinkage percentage of 100% NanoBone[®] alloplastic graft used for maxillary SFE. Our results show that the estimated mean graft height shrinkage percentage ($8.84\% \pm 5.32$) corresponds to the values cited in the literature. Thus, the material seems to maintain its volume in the first critical year of bone remodeling.

Two trials were conducted to evaluate whether autogenous bone could be replaced by bone substitutes to reduce surgical morbidity.^{30,31} It is suggested that autogenous bone can be substituted with 80% (mixed with autogenous bone) to 100% BHA when used for maxillary SFE.³⁰ Results from the same study indicate that similar short-term results can be expected when using autogenous bone, BHA, or a mixture of both for maxillary SFE and delayed placement of dental implants. In a recent review, it is acknowledged that autogenous bone might be replaced by bone substitutes for SFE, however the authors advise that larger trials with longer follow-up should be conducted to validate these preliminary findings.¹ Accordingly, our study protocol consisted of using 100% NanoBone[®] for maxillary SFE with residual bone heights ≤ 3 mm. Implants were then mainly placed in augmented volumes with minimal native crestal bone. Apart from the excluded case where persistent infection could be attributed to an undetected sinus membrane perforation during the initial SFE noted on surgical re-entry, our short-term results showed that 100% NanoBone[®] could replace autogenous bone in staged maxillary SFE procedures.

Implant survival rates similar to the results in this study have been reported in the literature when rough-surfaced implants are placed following staged SFE procedures. A review aimed to evaluate implant survival rates in the grafted sinus versus survival rates of implants placed in the non-grafted posterior maxilla.³² Results showed that the survival rate of implants

placed in sinuses augmented with the lateral window technique varied between 61.7% and 100%, with an average survival rate of 91.8%. Rough-surfaced implants showed a higher survival rate than machine-surfaced implants when placed in grafted sinuses. In another review,³³ the authors evaluated implant survival rates in the grafted sinus taking into account the influence of the implant surface, graft material, and implant placement timing. Results showed that machine-surfaced implants placed in the grafted maxillary sinus displayed a mean survival rate of 85.64%, and rough-surfaced implants exhibited a mean survival rate of 95.98%.³⁴ A prospective study evaluated the 5-year performance and success rate of implants with titanium plasma spray (TPS) or sand-blasted, large grit, acid-etched (SLA) surface inserted in a two-stage maxillary SFE procedure.³⁴ All 98 implants were considered successfully integrated, resulting in a 5-year success rate of 98% (for TPS implants 89%, for SLA implants 100%). Another review stated that, independently of the graft material used for lateral SFE, a mean survival rate of 86.3% was noted for machine-surfaced implants compared to 96.7% for rough-surfaced implants.² In the present study, implant apical migration and its subsequent failure could be explained by an extended implant bed preparation beyond the augmented sinus floor. Consequently, the implant survival rate (94.74%) obtained in the present study is consistent with published results reported for rough-surfaced implants placed in grafted sinuses. Furthermore, it can be concluded that NanoBone[®] in a 100% ratio could provide a viable augmented bone volume for implant placement with a short-term survival rate in accordance with published data.

Conclusions

The present 1-year prospective study indicates that a 100% NanoBone[®] alloplastic graft used in lateral SFE procedures presented limited height shrinkage. Implants placed in these grafted

sinuses showed survival rates similar to that found in published data. These results should be interpreted cautiously considering the study's reduced sample size.

Acknowledgements

The authors wish to thank Dr Paul M. KHOURY for his valuable assistance and help during the preparation of this article.

References

1. Esposito M, Grusovin MG, Rees J, et al. Interventions for replacing missing teeth: augmentation procedures of the maxillary sinus. *Cochrane Database Syst Rev.* 2010;CD008397.
2. Del Fabbro M, Rosano G, Taschieri S. Implant survival rates after maxillary sinus augmentation. *Eur J Oral Sci.* 2008;116:497-506.
3. Heinemann F, Mundt T, Biffar R, et al. A 3-year clinical and radiographic study of implants placed simultaneously with maxillary sinus floor augmentations using a new nanocrystalline hydroxyapatite. *J Physiol Pharmacol.* 2009;60 Suppl 8:91-97.
4. Gotz W, Gerber T, Michel B, et al. Immunohistochemical characterization of nanocrystalline hydroxyapatite silica gel (NanoBone[®]) osteogenesis: a study on biopsies from human jaws. *Clin Oral Implants Res.* 2008;19:1016-1026.
5. Gerber T, Holzhüter G, Knoblich B, et al. Development of bioactive sol-gel material template for in vitro and in vivo synthesis of bone material. *J Sol-Gel Sci Techn.* 2000 ;19:441-445.
6. Gerike W, Bienengraber V, Henkel KO, et al. The manufacture of synthetic non-sintered and degradable bone grafting substitutes. *Folia Morphol (Warsz).* 2006;65:54-55.
7. Henkel KO, Gerber T, Lenz S, et al. Macroscopical, histological, and morphometric studies of porous bone-replacement materials in minipigs 8 months after implantation. *Oral Surg Oral Med Oral Pathol Oral Radiol Endod.* 2006;102:606-613.
8. Henkel KO, Gerber T, Dorfling P, et al. Repair of bone defects by applying biomatrices with and without autologous osteoblasts. *J Craniomaxillofac Surg.* 2005;33:45-49.

9. Abshagen K, Schrodi I, Gerber T, et al. In vivo analysis of biocompatibility and vascularization of the synthetic bone grafting substitute NanoBone. *J Biomed Mater Res A*. 2009;91:557-566.
10. Canullo L, Dellavia C. Sinus lift using a nanocrystalline hydroxyapatite silica gel in severely resorbed maxillae: histological preliminary study. *Clin Implant Dent Relat Res*. 2009;11 Suppl 1:e7-13.
11. Canullo L, Dellavia C, Heinemann F. Maxillary sinus floor augmentation using a nano-crystalline hydroxyapatite silica gel: Case series and 3-month preliminary histological results. *Ann Anat*. 2011.
12. Stubinger S, Ghanaati S, Orth C, et al. Maxillary sinus grafting with a nano-structured biomaterial: preliminary clinical and histological results. *Eur Surg Res*. 2009;42:143-149.
13. De Leonardis D, Pecora GE. Augmentation of the maxillary sinus with calcium sulfate: one-year clinical report from a prospective longitudinal study. *Int J Oral Maxillofac Implants*. 1999;14:869-878.
14. Geurs NC, Wang IC, Shulman LB, et al. Retrospective radiographic analysis of sinus graft and implant placement procedures from the Academy of Osseointegration Consensus Conference on Sinus Grafts. *Int J Periodontics Restorative Dent*. 2001;21:517-523.
15. Johansson B, Grepe A, Wannfors K, et al. A clinical study of changes in the volume of bone grafts in the atrophic maxilla. *Dentomaxillofac Radiol*. 2001;30:157-161.
16. Hallman M, Hedin M, Sennerby L, et al. A prospective 1-year clinical and radiographic study of implants placed after maxillary sinus floor augmentation with bovine hydroxyapatite and autogenous bone. *J Oral Maxillofac Surg*. 2002;60:277-284; discussion 285-276.

17. Ozyuvaci H, Bilgic B, Firatli E. Radiologic and histomorphometric evaluation of maxillary sinus grafting with alloplastic graft materials. *J Periodontol.* 2003;74:909-915.
18. Reinert S, Konig S, Bremerich A, et al. Stability of bone grafting and placement of implants in the severely atrophic maxilla. *Br J Oral Maxillofac Surg.* 2003;41:249-255.
19. Hatano N, Shimizu Y, Ooya K. A clinical long-term radiographic evaluation of graft height changes after maxillary sinus floor augmentation with a 2:1 autogenous bone/xenograft mixture and simultaneous placement of dental implants. *Clin Oral Implants Res.* 2004;15:339-345.
20. Velich N, Nemeth Z, Toth C, et al. Long-term results with different bone substitutes used for sinus floor elevation. *J Craniofac Surg.* 2004;15:38-41.
21. Zijderveld SA, Schulten EA, Aartman IH, et al. Long-term changes in graft height after maxillary sinus floor elevation with different grafting materials: radiographic evaluation with a minimum follow-up of 4.5 years. *Clin Oral Implants Res.* 2009;20:691-700.
22. Lindgren C, Mordenfeld A, Hallman M. A Prospective 1-Year Clinical and Radiographic Study of Implants Placed after Maxillary Sinus Floor Augmentation with Synthetic Biphasic Calcium Phosphate or Deproteinized Bovine Bone. *Clin Implant Dent Relat Res.* 2010.
23. Mardinger O, Chaushu G, Sigalov S, et al. Factors affecting changes in sinus graft height between and above the placed implants. *Oral Surg Oral Med Oral Pathol Oral Radiol Endod.* 2011;111:e6-11.
24. Sbordone L, Levin L, Guidetti F, et al. Apical and marginal bone alterations around implants in maxillary sinus augmentation grafted with autogenous bone or bovine

- bone material and simultaneous or delayed dental implant positioning. *Clin Oral Implants Res.* 2011;22:485-491.
25. Buser D, Mericske-Stern R, Bernard JP, et al. Long-term evaluation of non-submerged ITI implants. Part 1: 8-year life table analysis of a prospective multi-center study with 2359 implants. *Clin Oral Implants Res.* 1997;8:161-172.
 26. Cochran DL, Buser D, ten Bruggenkate CM, et al. The use of reduced healing times on ITI implants with a sandblasted and acid-etched (SLA) surface: early results from clinical trials on ITI SLA implants. *Clin Oral Implants Res.* 2002;13:144-153.
 27. Gray CF, Staff RT, Redpath TW, et al. Assessment of maxillary sinus volume for the sinus lift operation by three-dimensional magnetic resonance imaging. *Dentomaxillofac Radiol.* 2000;29:154-158.
 28. Senel FC, Duran S, Icten O, et al. Assessment of the sinus lift operation by magnetic resonance imaging. *Br J Oral Maxillofac Surg.* 2006;44:511-514.
 29. Gray CF, Redpath TW, Smith FW, et al. Assessment of the sinus lift operation by magnetic resonance imaging. *Br J Oral Maxillofac Surg.* 1999;37:285-289.
 30. Hallman M, Sennerby L, Lundgren S. A clinical and histologic evaluation of implant integration in the posterior maxilla after sinus floor augmentation with autogenous bone, bovine hydroxyapatite, or a 20:80 mixture. *Int J Oral Maxillofac Implants.* 2002;17:635-643.
 31. Szabo G, Huys L, Coulthard P, et al. A prospective multicenter randomized clinical trial of autogenous bone versus beta-tricalcium phosphate graft alone for bilateral sinus elevation: histologic and histomorphometric evaluation. *Int J Oral Maxillofac Implants.* 2005;20:371-381.
 32. Wallace SS, Froum SJ. Effect of maxillary sinus augmentation on the survival of endosseous dental implants. A systematic review. *Ann Periodontol.* 2003;8:328-343.

33. Del Fabbro M, Testori T, Francetti L, et al. Systematic review of survival rates for implants placed in the grafted maxillary sinus. *Int J Periodontics Restorative Dent.* 2004;24:565-577.
34. Bornstein MM, Chappuis V, von Arx T, et al. Performance of dental implants after staged sinus floor elevation procedures: 5-year results of a prospective study in partially edentulous patients. *Clin Oral Implants Res.* 2008;19:1034-1043.

Figures and tables

Fig. 1.

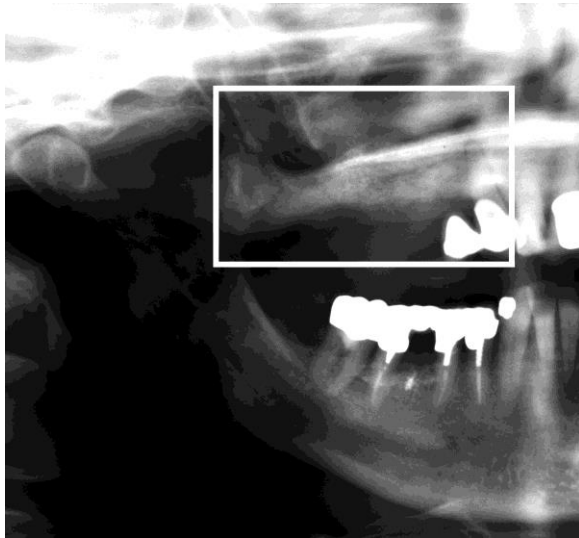


Fig. 2.

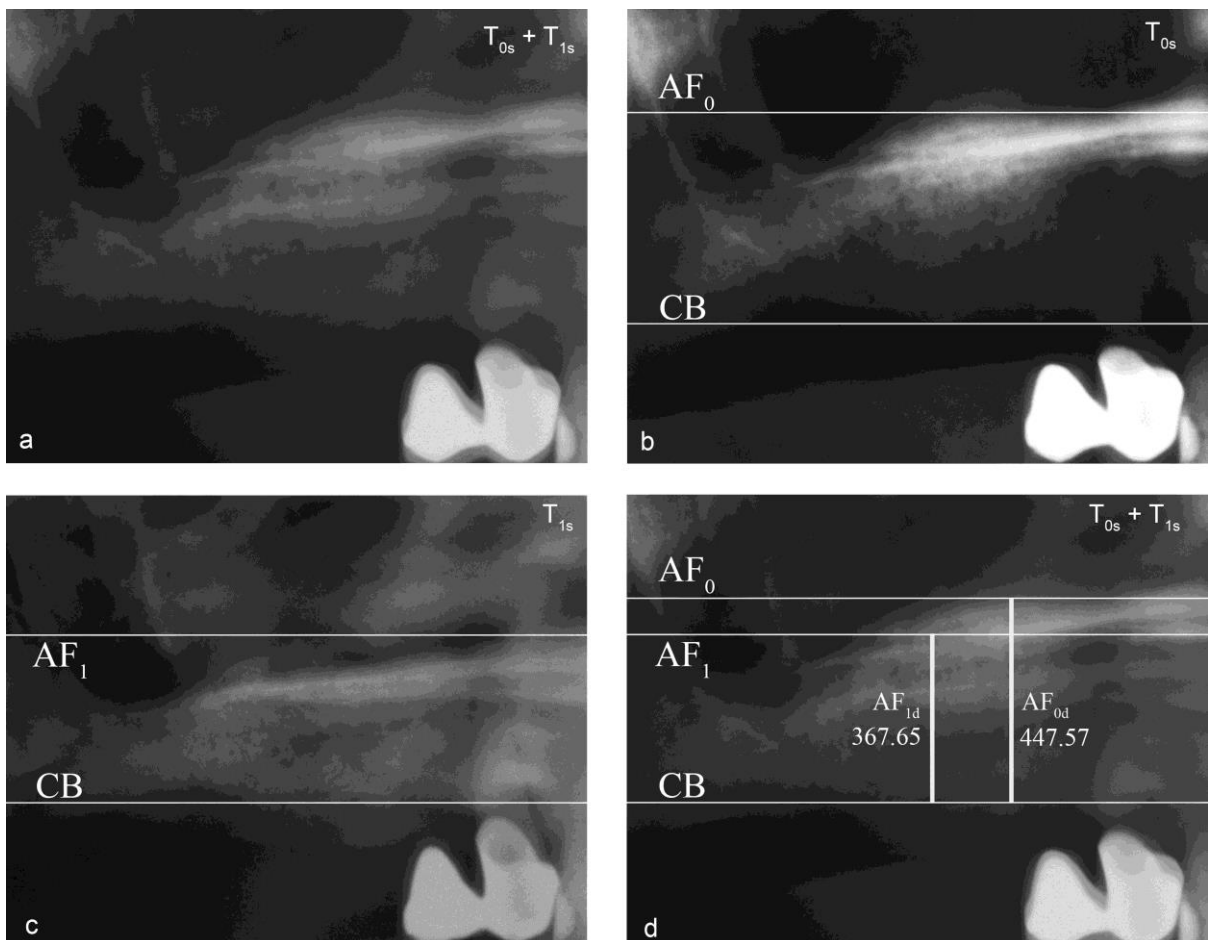


Table 1. Patient / implant characteristics and type of received fixed partial dentures (FPDs).

Patients				Implants					
No.	Sex	Age (years)	Smoker	No.	Position	Diameter (mm)	Length (mm)	Type	FPD
1	Female	37	No	1	26	4.1	10	Standard Plus RN	i
2	Female	60	No	2	15	4.1	10	Standard Plus RN	i-i
				3	16	4.1	10	Standard Plus RN	i-i
				4	17	4.1	10	Standard Plus RN	i-i
				5	26	4.1	10	Tapered Effect RN	Failed
				6	27	4.1	10	Standard Plus RN	i-t
3	Female	63	No	7	16	4.1	10	Bone Level RC	i
				8	26	4.1	10	Bone Level RC	i
4	Female	53	No	9	15	4.1	10	Standard Plus RN	i-i
				10	16	4.1	10	Standard Plus RN	i-i
				11	17	4.1	10	Standard Plus RN	i-i
				12	24	4.1	10	Tapered Effect RN	i-i
				13	25	4.1	10	Standard Plus RN	i-i
				14	26	4.1	10	Standard Plus RN	i-i
5	Male	46	No	15	15	4.1	10	Standard Plus RN	i-i
				16	16	4.1	10	Standard Plus RN	i-i
6	Male	42	No	17	16	4.8	10	Standard Plus WN	Excluded
7	Male	65	No	18	26	4.8	10	Standard Plus WN	i
8	Female	59	Yes	19	16	4.1	10	Standard Plus RN	i-i
				20	17	4.1	10	Standard Plus RN	i-i

Table 2. Radiographic measurements and graft shrinkage percentages

Patient	Sinus	T _{0s} -T _{1s} * (months)	AF _{0d} * (pixels)	AF _{1d} * (pixels)	AF _{1d} /AF _{0d} *	GH Remaining %	GH Shrinkage %
1	1	12.32	457.8	445.81	0.974	97.4	2.6
2	2	11.94	524.41	474.8	0.905	90.5	9.5
	3	11.32	418.11	396.85	0.949	94.9	5.1
3	4	13.32	429.92	411.02	0.956	95.6	4.4
	5	11.97	538.58	507.87	0.943	94.3	5.7
4	6	11.84	447.57	367.65	0.821	82.1	17.9
	7	11.94	342.52	314.17	0.917	91.7	8.3
5	8	11.84	422.83	401.57	0.950	95.0	5
6	9				Excluded		
7	10	11.35	566.93	479.53	0.846	84.6	15.4
8	11	11.55	779.53	666.14	0.855	85.5	14.5
Mean		11.94				91.16	8.84
± SD		± 0.57				± 5.32	± 5.32

Table 3. Life-table of implant survival rates and cumulative survival rates

Time	Total No.	No. Failed	SR (%)	CSR (%)
At abutment connection	19	1	94.74	94.74
After 1 year of placement	19	0	100	94.74

Figure and table legends

Fig. 1. ROI definition.

Fig. 2. (a) T_{0s} and T_{1s} layers superposed. (b) CB and AF_0 set on layer T_{0s} . (c) AF_1 set on layer T_{1s} . (d) Measurements (in pixels) of AF_{0d} and AF_{1d} with the ruler tool.

Table 1. i: single crown; i-i: splinted crowns; i-t: implant-to-tooth supported fixed partial denture; RN: Regular Neck; RC: Regular CrossFit™; WN: Wide Neck. Teeth numbering according to the World Health Organization (WHO) site classification.

Table 2. *: refer to the text; GH: graft height.

Table 3. SR: survival rate; CSR: cumulative survival rate.