

Osteotome Sinus Floor Elevation Procedure for First Molar Single-Gap Implant Rehabilitation: A Case Series.

AUTHORS: Rabah NEDIR, DMD,* Nathalie NURDIN, PhD,† Marc EL HAGE, DMD, MS,‡
Mark BISCHOF, DMD,§

ABSTRACT (173 WORDS)

Introduction: This case series describes single implant rehabilitation in the maxillary first molar sites. It aims to show the surgical approaches carried out vs. the residual bone height (RBH), and to evaluate implant success rate and bone anchorage height after 1 year.

Materials and Methods: Placement of 10-mm-long tapered bone level implants was carried out according to the RBH: when $RBH \geq 10$ mm, standard implant placement; when $6 \text{ mm} < RBH < 10$ mm, osteotome sinus floor elevation procedure (OSFE) without graft; and, when $RBH \leq 6$ mm, OSFE with graft.

Results: Fourteen patients received 15 implants in a mean RBH of 5.0 ± 2.4 mm (range 2.0 - 11.0 mm). One implant was placed with a standard placement technique, 4 using OSFE without graft and 10 using OSFE with graft. The 1-year success rate was 100% and mean bone anchorage height reached at least 9.5 mm.

Conclusion: Almost all cases of maxillary single implant rehabilitation might be performed by using OSFE. In the extremely atrophic maxilla, simultaneous grafting ensures implant embedding in bone.

KEY-WORDS: atrophic maxilla, osteotome sinus floor elevation, bone graft, sinus-lift

*Clinical Director, Swiss Dental Clinics Group, Ardentis Clinique Dentaire Vevey, Vevey, Switzerland.

†Senior Scientist, Swiss Dental Clinics Group, Ardentis Clinique Dentaire Vevey, Vevey, Switzerland.

‡Oral Surgeon, Swiss Dental Clinics Group, Ardentis Clinique Dentaire Lausanne, Lausanne, Switzerland. Lecturer, Department of Oral and Maxillofacial Surgery, Oral Surgery and Implantology Unit, Geneva University Hospitals, Geneva, Switzerland.

§Clinical Director, Swiss Dental Clinics Group, Ardentis Clinique Dentaire Lausanne, Lausanne, Switzerland.

Reprint requests and correspondence to: Rabah Nedir, DMD, Ardentis Clinique Dentaire Vevey, Rue du Collège 3, 1800 Vevey, Switzerland.

Phone: +41 58 234 00 10. Email: rabah.nedir@ardentis.ch

Maxillary first molars are the most common teeth lost by adults, in contrast to cuspids, which survive for longer time.^{1,2} Along with the maxillary second molars, they are more vulnerable to decay and to periodontal disease than other teeth.³ This greater vulnerability seems to be multifactorial, including the anatomy of the tooth, functional forces, local variations in bacterial flora, and genetic predisposition. Furthermore, upper first molars are essential for occlusion and mastication.⁴

The sinus floor is convex, and generally reaches its deepest point in the first molar region. Therefore, molar roots are frequently protruding within the sinus.⁵ Factors such as tooth loss, periodontal disease, pneumatization of the maxillary sinus, or a combination of these, can often lead to a lack of sufficient alveolar bone height for implant anchorage in the posterior maxilla. Successful standard dental implant placement in the posterior maxilla usually requires vertical bone height of at least 10 mm. However, at molar sites, residual bone height (RBH) often ranges between 4.4 mm and 8.9 mm,⁶ and bone density in the posterior maxilla is poor. Reduced bone volume and low bone density are challenging for implant placement and long-term success.

In first molar single gaps with a RBH of less than 10 mm, three treatment options may be considered, depending on the anatomy of site, status of adjacent teeth, financial situation, education of the referring dentist and surgeon's skills.

First, a fixed partial denture may be undertaken. This will correct the problem of the missing tooth with respect to appearance and function. However, this option is invasive and aggressive, particularly towards the adjacent teeth. Single-tooth replacement with fixed partial denture exposes the abutment teeth as well as the reconstruction to several biological and technical risks such as endodontic complications, secondary caries, difficult access for plaque control resulting in periodontal complications, loss of retention, fractures of teeth supports and denture.⁷ Although implant placement represents the most conservative option for single tooth replacement,⁸ fixed partial dentures is proposed when an implant cannot be placed due to medical reasons, compromised anatomical situations, or financial concerns.⁹ It

is an easy solution for the general dentist. Furthermore, it might show high success rate over at least 18 years.¹⁰

Second, a lateral window sinus-lift may be considered. It comprises a bone augmentation procedure and the placement of a single implant. This treatment with delayed implant placement is the classical method. It is complex, invasive, and time-consuming; total treatment duration is at least 1 year.¹¹ The posterior teeth are supplied by neurovascular branches coming from the maxillary tuberosity. Obviously this anatomical aspect has its repercussions for the small gaps where sinus lifting is indicated. Surgical approach apically of vital neighboring teeth might devitalize them.⁵ According to authors' experience and because of economic concerns, improper dental implant education, prosthetic procedure difficulties,^{7,12} general dentists rarely refer single implant placement with sinus augmentation. The three-unit bridge solution is often selected. The sinus-lift and implant placement are postponed for a few years when a multiple tooth loss occurs.

Third, osteotome sinus floor elevation (OSFE) can be performed. The OSFE technique through a crestal approach is surgically less invasive and less time-consuming than the lateral window sinus-lift, and there is less postoperative discomfort.¹¹ Preoperative radiographic assessment can include only an orthopantomograph and a periapical radiograph. The use of Cone Beam Computed Tomography (CBCT) is recommended for all implant sites and particularly for bone grafting zone evaluation. This consensus was supported by the International Congress of Oral Implantologists and the American Association of Oral Maxillofacial Radiology.^{13,14} However, from authors' opinion, in case of negative sinus history and absence of further interrogations after pre-operative 2D imaging, the pre-operative 3D radiographs are not warranted for a single-gap implant placement because of the very localized sinus augmentation performed by the OSFE procedure.

With OSFE, the implant is placed at the same time as the sinus floor is elevated. The procedure improves implant primary stability and bone-to-implant contact.¹⁵ Grafting material can be placed to

promote osteogenesis and maintain the bone volume around the implants. The choice of the most suitable grafting material for sinus augmentation has been a subject of controversy over the years.¹⁶ Xenograft materials of bovine origin are most often used and documented. The use of alloplastic materials is also possible. This is offered to patients who are averse or reluctant to the use of animal-derived products. Some fully synthetic materials have shown good osteoconduction properties with favorable resorption rates.¹⁷ However, the need to use grafting material has been questioned in the recent years. When the space between the sinus membrane and the sinus floor is maintained, bone can form and fill the graft-free volume.¹⁸⁻²⁵

This case series describes a selection of consecutive patients who requested single implant placement in maxillary first molar sites. It shows the distribution of cases according to maxillary RBH and the different surgical approaches that can be conducted. Furthermore, implant success rate and bone anchorage height (radiographic bone-to-implant contact) around implants were evaluated after one year.

MATERIALS AND METHODS

Inclusion criteria

Patients attending a private practice (Ardentis Clinique Dentaire Vevey, Vevey, Switzerland) were consecutively recruited over a 24-month period (September 2008 to October 2010). Inclusion criteria for patient enrollment were as follows:

- (1) Indication for unitary implant placement in the maxillary site #16 and/or site #26;
- (2) Absence of medical history of acute or chronic sinusitis;
- (3) Absence of active periodontal disease, diabetes, and metabolic bone disease;
- (4) Healthy maxillary sinuses and edentulous site, as judged from radiographic and clinical examinations; a period of at least 4 months between tooth extraction and implant placement was required;

- (5) Placement of 10-mm-long tapered bone level implant (Straumann® Bone Level with SLActive® surface; 4.1/4.8 mm diameter; Straumann AG, Basel, Switzerland); shorter implants (8 mm) were used only in the case of membrane perforation;
- (6) Sufficient implant primary stability in the residual bone;
- (7) No use of a removable partial denture during the healing period.

Surgery and prosthetic procedures

Surgery was performed under antibiotic prophylaxis initiated on the day before (Amoxi-Mepha, Mepha Pharma SA, Aesch Basel, Switzerland; 750 mg, 3 times/day for 6 days; or Dalacin C, Pfizer, Zürich, Switzerland; 300 mg, 3 times/day for 5 days, in case of penicillin allergy). Preoperative orthopantomograph and apical radiograph were performed to determine the maxillary RBH at the edentulous site. The surgical procedure selected for the placement of a 10-mm-long implant depended on the RBH measured at the edentulous site and intended augmentation height:

- For sites presenting a RBH ≥ 10 mm, the implant was placed according to standard surgical procedure.
- For sites with $6 \text{ mm} < \text{RBH} < 10 \text{ mm}$, the implant was placed by OSFE without grafting material. A mid-crestal incision was performed for flap elevation, without any vertical or periosteal releasing incisions. To get access to the sinus floor, the cortical bone was marked using round burs of increasing diameter (Ø 1.4–3.1 mm). Drilling up to 1 mm away from the floor was then further continued with the Ø 2.8 and 3.5 mm drills. A Ø 2.8 mm sinus floor elevation osteotome (Straumann AG) was first utilized. Careful light tapping with a mallet pushed the bony sinus floor into the sinus cavity, which elevated the Schneiderian membrane. The osteotomy site was then enlarged with a Ø 3.5 mm osteotome; integrity of the membrane was controlled by using the Valsalva maneuver and with an undersized Ø 2.1 mm depth gauge.²⁶ The implant was placed without grafting material and without tapping.
- For sites with RBH ≤ 6 mm, the same one-stage procedure as previously described for the implants placed in sites with $6 \text{ mm} < \text{RBH} < 10 \text{ mm}$ was performed. To increase the primary stability in low-density bone, the use of osteotomes is more relevant than the use of drills. The elevated sinus was filled

with 0.5 cm³ (0.25 g) of Bone Ceramic® graft substitute (particle diameter 400-700 µm; Straumann AG). The implant was then inserted immediately.

All implants were inserted in the prepared site until their shoulder was no longer visible on the mesial and distal sides, in a non-submerged position. Primary stability was assessed by finger pressure exerted on the implant, and by resonance frequency analysis (RFA) measurements (Osstell®; Integration Diagnostics AB, Gothenburg, Sweden). After a 12-week healing period, the clinical stability of the implants was assessed by RFA and by resistance to tightening with a 15-Ncm torque. When the implant was determined to be stable, impression was carried out. At 14 weeks after implant placement, the abutment was tightened with a 35-Ncm torque and the implant was loaded with a porcelain-fused-to-gold prosthesis.

Success criteria

The implants were controlled at 1 week, 12 weeks (i.e., at impression time), 14 weeks (i.e., at prosthetic delivery) after implant placement, and then 1 year after implant loading. The success criteria included: (1) absence of clinically detectable implant mobility; (2) absence of pain or any subjective sensation; (3) absence of recurrent peri-implant infection; and (4) absence continuous radiolucency around the implant.²⁷

Radiographic analysis

Standardized periapical radiographs were taken immediately after surgery, 12 weeks and 14 weeks after implant placement, and 1 year after loading. Net bone anchorage height-or radiographic bone-to-implant contact- was measured at the mesial and distal implant sides using 1-year radiographs. Internal calibration was realized on each radiograph by measuring three inter-thread distances (2.4 mm). Fig. 1 shows the radiographic landmarks. The mean and standard deviation were used to assess measured radiographic lengths.

RESULTS

Fifteen patients were included in this case series, but one dropped out because of unwillingness to visit the clinic during the follow-up period. Therefore, 14 patients (7 men and 7 women, mean age 47.5 ± 18.4 years) received 15 implants. The mean preoperative RBH at the sites to be treated was 5.0 ± 2.4 mm (range 2.0-11.0 mm). The crestal bone and sinus floor at the implant sites did not appear to be merged. One implant was placed using standard procedures in a maxillary site with RBH = 11.0 mm; four implants were placed in sites that showed $6 \text{ mm} < \text{RBH} < 10 \text{ mm}$ (mean 7.0 ± 1.1 mm, range 6.0-8.4 mm) using OSFE without grafting material; and 10 implants were placed in sites that showed $\text{RBH} \leq 6$ mm (mean 3.6 ± 0.8 mm, range 2.0–5.0 mm) using OSFE with grafting material. The negative outcome obtained with the Valsava procedure associated with the resistance to probing in the implant bed preparations have assessed the integrity of Schneiderian membranes. No Schneiderian membrane perforation was observed. All placed implants were 10 mm in length. Only one patient complained about common postoperative events such as tenderness and headache, but suffered no further consequences.

At 1 year after loading, all implants were clinically stable with their definitive prosthesis functionally loaded. The implant success rate was 100%. Fig. 2 shows the radiographic follow-up of all the implants before and after surgery, and at 1 year after implant loading with the prosthesis in place. Fig. 3 details the follow-up of one implant placed using OSFE without grafting, with radiographs and photographs. At 1 year, all implants gained endo-sinus bone, with limited crestal bone loss; all radiographs showed endo-sinus lamina dura relocation. The mean net bone anchorage height after 1 year for all implants was 10.0 ± 1.3 mm. It was 10.3 ± 0.4 mm for the site presenting a $\text{RBH} \geq 10$ mm, 9.5 ± 1.0 mm for the sites with $6 \text{ mm} < \text{RBH} < 10 \text{ mm}$, and 10.1 ± 1.5 mm for the sites with $\text{RBH} \leq 6$ mm.

DISCUSSION

The consensus conference held in 1996 on sinus lifting procedures resulted in recommendations on the surgical approach as a function of the RBH.²⁸ When the maxillary RBH is ≥ 10 mm, a standard implant procedure should be performed. When the RBH is < 10 mm, sinus elevation to increase the initial bone height is indicated before or at implant placement. When the RBH is < 6 mm, the use of the lateral window sinus-lift technique is recommended.

It has been shown that grafting material is not needed to gain endo-sinus bone.¹⁸⁻²⁵ In a retrospective study assessing radiographically sinus floor remodeling after implant insertion using a modified transalveolar technique without grafting material, 24 patients (24 implants) were available for follow-up. The mean height of the newly formed bone was 2.2 ± 1.7 mm mesially and 2.5 ± 1.5 mm distally.²⁰ In a clinical study reporting the follow-up of 25 implants placed in 17 patients by using OSFE without grafting, the mean endo-sinus bone gain after 1 year reached 2.5 ± 1.2 mm when 10-mm-long implants were placed in mean RBH of 5.4 ± 2.3 mm.¹⁹ Pjetursson et al reported a mean radiographic bone gain for 164 implants placed using the OSFE without grafting material of 1.7 ± 2 mm.²³ However, the insertion of grafting material promotes more bone gain. The probability of gaining 2 mm or more of new bone was 77.9% when the implants were installed with grafting material whereas it decreased to 39.1% when no grafting material was used.²³ Bone substitutes can fill large volumes beyond the physiological limits of the sinus. Their insertion increases the tenting effect of the implant apex by further elevating the Schneiderian membrane and allows the elevated membrane to be better maintained. After an average follow-up time of 3.2 years, the mean bone gain reached 4.1 ± 2.4 mm when grafting material was used (88 implants) compared to 1.7 ± 2 mm without grafting (164 implants).²² Therefore, the advantage of using bone grafting material in the osteotome technique remained an open-question²⁹ or was evident for other authors²³. A systematic review on transalveolar sinus augmentation technique reported that only two out of the 19 included studies did not use any grafting material.³⁰ It might indicate that clinicians preferred the application of grafting material when augmenting posterior maxilla using OSFE.²³

The OSFE technique yields predictable results, with success rates reaching 95%.³¹⁻³³ For Calin et al, RBH values above 4 mm did not seem to influence implant failure and sinus floor elevation using osteotomes is more predictable.²⁹ Implant success was reduced with a lower bone quantity.³¹ The implant survival rates reached 96% in RBH \geq 5 mm but was 85.7% with RBH of 3 and 4 mm.³⁴ In the reported studies, most OSFE procedures were performed when RBH > 3mm.³¹ In low RBH, standard parallel-walled implants, with a large thread pitch, cannot engage into bone more than a single row of threads. In the presence of bicortical residual bone, sufficient primary stability can be attained using tapered implants with a reduced thread pitch.³¹ Through compressive insertion, these implants provide sufficient primary stability in soft bone.³⁵

The OSFE has gained increasing popularity with a growing number of reports on the subject.³⁶ Although less invasive than the lateral window sinus-lift procedure, it is technically-demanding and requires surgical skills. The most frequent intra-operative complication related to this procedure is membrane perforation resulting from limited visibility during surgery.³⁷ Mallets blows to the osteotomes, necessary to fracture the sinus floor, are uncomfortable for patients and trauma can be induced by the percussive force. Cases of paroxysmal positional vertigo of the posterior semicircular canal contralateral to the implanted side, occurring 1 or 2 days after the surgical procedure, have been reported. The Epley re-positioning maneuver solves this problem in a few hours.³⁸ The insertion of implants without an adequate primary stability can lead to accidental displacement of implants through the maxillary sinus and migration to upper craniofacial structures.^{39,40}

It is very infrequent that crestal bone fuses with the sinus floor in cases of single gaps in the posterior maxilla because of the presence of bone supported by the adjacent teeth. As a result, two distinct areas of bone support are present; implants are anchored bicortically, hence increasing primary stability.²² Furthermore, because of the presence of adjacent teeth, the sinus floor adopts a convoluted shape that fits well with an augmentation procedure. The tenting effect induced by the membrane elevation during

the OSFE procedure can be maintained by the walls formed by the cortical and bundle bone surrounding the roots of the adjacent teeth. Thus, a favorable healing environment is formed with a four-wall cavity.

In the posterior region, tissue-level implants are currently used in daily practice. The primary stability is improved for those featuring a tapered shape, with threads up to the top of the rough surface and a reduced thread pitch. Although they were developed to be placed into fresh extraction sockets⁴¹, indications for the tapered implants have been safely extended to placement in the atrophic posterior maxilla.²⁰ In addition, the presence of a chemically-enhanced rough hydrophilic surface might significantly modify and accelerate osseointegration.⁴² The bone-level implants used hereby present tapered morphology and hydrophilic surface, with connection between the implant and the abutment placed at the level of the bone crest. These characteristics offer minimal peri-implant bone resorption following restoration. These implants are predominantly used in esthetic indications.⁴³ Therefore, particularly for demanding patients, the bone-level implants can be used during rehabilitation of the first molar sites that are sometimes visible when smiling. The cut-off neck configuration can also be useful when an inter-arch distance for crown placement is reduced, particularly in the posterior maxilla.

The choice of implant length should depend of preoperative measurement of RBH and desired postoperative protrusion of the implant within the sinus. Nedir et al noted a positive correlation between the postoperative implant protrusion and peri-implant *de novo* bone formation after 5 years of implant follow-up.⁴⁴ With respect to the Schneiderian membrane mechanical properties, the membrane is mostly intact up to 4 mm of implant protrusion within the sinus; it remains level with the implant apex after 6 months when no grafting material was used.⁴⁵ In the present case series, the mean measured RBH before implant placement was low (5.0 ± 2.4 mm). Of the total of 15 first molar sites that were treated, 10 had an RBH ≤ 6 mm. Although the sample size was small, the values and distribution of RBH agreed with that reported in the literature for molar sites.⁶ The implantation procedures were selected according to the RBH at the implant site and the intended augmentation height, in order to embed 10-mm-long implants within maxillary bone after 1 year. A biphasic calcium phosphate graft substitute was added

when RBH was ≤ 6 mm. Standard implant insertion was carried out when RBH ≥ 10 mm. For $6 \text{ mm} < \text{RBH} < 10 \text{ mm}$, implants were placed using OSFE without grafting. This is believed to be the first report of the use of a fully synthetic biomaterial for endo-sinus bone augmentation via a crestal approach. All implants healed successfully, and no adverse effects were induced by the bone level implants. Furthermore, there was no evidence indicating that there was a threshold in residual alveolar bone height critical for survival of implants simultaneously placed with augmentation procedure.⁴⁶ The mean net bone anchorage height was >9.5 mm after 1 year. This means that, in all cases, the bone volume was sufficient to cover the implant surface.

The use of 10-mm-long implants yielded successful results after 1 year, even without grafting. Longer implants might improve the tenting effect and then increase volume for neo-bone modeling. However, they could also increase the risk of Schneiderian membrane perforation. The grafting material protects the Schneiderian membrane from perforation.²² Its presence increases hard tissue volume around the implant apex by enhancing the tenting effect above the implant. At least 4 mm of bony composite can be gained along the implants. About 6 mm of bone anchorage might be sufficient to ensure implant function in the posterior area after 1 year.²⁴ Therefore, the utility of achieving complete implant bone coverage by adding a grafting material within the sinus can be questioned. From the authors' point of view, the bone tissue above the implant (dome) might not contribute to the anchorage of the implant in the maxilla. When bone anchorage was limited, a fully synthetic graft, such as biphasic calcium phosphate material, has shown good clinical performance. It showed the same amount of newly formed bone, with the same histological appearance, as inorganic bovine bone substitutes.⁴⁷

CONCLUSION

In recent years, there has been a willingness to propose simplified treatment in order to rehabilitate the edentulous posterior maxilla. Treatment needs to be rapid, minimally invasive, affordable, and reliable. Simplification of treatment leads to increased patient acceptance, and practitioners may then provide implant treatment to more people. Therefore, the management of the posterior maxilla should now push

the limits that were accepted 15 years ago. The invasive bridge solution leading few years later to a wide edentulous space should be almost completely discarded. Additional studies with larger sample size and longer follow-up duration are needed, but within its limitation, this case series has shown that most cases of maxillary implant rehabilitation might be performed by using sinus elevation via a crestal approach and implant ≤ 10 mm. When the RBH of maxillary single gap is less than 10 mm, the augmentation technique via a crestal approach and the use of tapered short implants allow implant treatment in a single intervention. As a result of osseous regeneration below the Schneiderian membrane, endo-sinus bone gain can be achieved without graft when moderate height of new bone is sufficient. Grafting material is inserted when an endo-sinus bone gain of at least 4 mm is needed.

DISCLOSURE

REFERENCES

1. Hujoel PP, Loe H, Anerud A, et al. Forty-five year tooth survival probabilities among men in Oslo, Norway. *J Dental Res.* 1998;77:2020–2027.
2. Paulander J, Axelsson P, Lindhe J, et al. Intra-oral pattern of tooth and periodontal bone loss between the age of 50 and 60 years. A longitudinal prospective study. *Acta Odontol Scand.* 2004;62:214–222.
3. Hirschfeld L, Wasserman B. A long-term survey of tooth loss in 600 treated periodontal patients. *J Periodontol.* 1978;49:225–237.
4. Gotfredsen K, Walls AWG. What dentition assures oral function? *Clin Oral Implants Res.* 2007;18(Suppl. 3):34–45.
5. Van den Bergh JP, ten Bruggenkate CM, Disch FJ, et al. Anatomical aspects of sinus floor elevations. *Clin Oral Implants Res.* 2000;11:256–265.
6. Pramstraller M, Farina R, Franceschetti G, et al. Ridge dimensions of the edentulous posterior maxilla: a retrospective analysis of a cohort of 127 patients using computerized tomography data. *Clin Oral Implants Res.* 2011;22:54–61.
7. Brägger U, Krenander P, Lang NP. Economic aspects of single-tooth replacement. *Clin Oral Implants Res.* 2005;16:335–341.
8. Priest GF. Failure rates of restorations for single-tooth replacement. *Int J Prosthodont.* 1996;9:38–45.
9. Pjetursson BE, Tan K, Lang NP, et al. A systematic review of the survival and complication rates of fixed partial dentures (FPDs) after an observation period of at least 5 years. *Clin Oral Implants Res.* 2004;15:667–676.
10. Palmqvist S, Swartz B. Artificial crowns and fixed partial dentures 18 to 23 years after placement. *Int J Prosthodont.* 1993;6:279–285.
11. Brägger U, Gerber C, Joss A, et al. Patterns of tissue remodeling after placement of ITI® dental implants using an osteotome technique: a longitudinal radiographic case cohort study. *Clin Oral Implants Res.* 2004;15:158–166.

12. Levin RP. Determining factors for implant referral rates. *Implant Dent.* 2002;11:312–314.
13. Benavides E, Rios HF, Ganz SD, et al. Use of cone beam computed tomography in implant dentistry: the International Congress of Oral Implantologists consensus report. *Implant Dent.* 2012;21:78–86.
14. Tyndall DA, Price JB, Tetradis S, et al. Position statement of the American Academy of Oral and Maxillofacial Radiology on selection criteria for the use of radiology in dental implantology with emphasis on cone beam computed tomography. *Oral Surg Oral Med Oral Pathol Oral Radiol.* 2012;113:817–826.
15. Zitzmann NU, Schärer P. Sinus elevation procedures in the resorbed posterior maxilla. Comparison of the crestal and lateral approaches. *Oral Surg Oral Med Oral Pathol Oral Radiol Endod.* 1998;85:8–17.
16. Del Fabbro M, Testori T, Francetti L, et al. Systematic review of survival rates for implants placed in the grafted maxillary sinus. *Int J Periodontics Restorative Dent.* 2004;24:565–577.
17. Dietze S, Bayerlein T, Proff P, et al. The ultrastructure and processing properties of Straumann Bone Ceramic and NanoBone. *Folia Morphol.* 2006;65:63–65.
18. Lundgren S, Andersson S, Gualini F, Sennerby L. Bone reformation with sinus membrane elevation: A new surgical technique for maxillary sinus floor augmentation. *Clin Implant Dent Relat Res.* 2004;6:165–173.
19. Nedir R, Bischof M, Vazquez L, et al. Osteotome sinus floor elevation without grafting material. A 1-year prospective pilot study with ITI implants. *Clin Oral Implants Res.* 2006;17:678–685.
20. Schmidlin P, Muller J, Bindl A, Imfeld T. Sinus floor elevation using an osteotome technique without grafting materials and membranes. *Int J Periodontics Restorative Dent.* 2008;23:609–617.
21. Nedir R, Nurdin N, Szmukler-Moncler S, et al. Placement of tapered implants using an osteotome sinus floor elevation technique without bone grafting: 1-year results. *Int J Oral Maxillofac Implants.* 2009;24:727–733.
22. Gabbert O, Koob A, Schmitter M, et al. Implants placed in combination with internal sinus lift without graft material: an analysis of short-term failure. *J Clin Periodontol.* 2009;36:177–183.

23. Pjetursson BE, Ignjatovic D, Matuliene G, et al. Transalveolar maxillary sinus floor elevation using osteotomes with or without grafting material. Part II: radiographic tissue remodeling. *Clin Oral Implants Res.* 2009;20:677–683.
24. Nedir R, Nurdin N, Khoury P, et al. Osteotome sinus floor elevation with and without grafting material in the severely atrophic maxilla. A one-year prospective randomized controlled study. *Clin Oral Implants Res.* 2013;24:1257–1264.
25. Si MS, Zhuang LF, Gu YX, et al. Osteotome sinus floor elevation with or without grafting: a 3-year randomized controlled clinical trial. *J Clin Periodontol.* 2013;40:396–403.
26. Watzek G, Pommer B, Strbac G. Status quo analysis. In: Watzek G, ed. *The percrestal sinus lift - from illusion to reality.* New Malden, UK. Quintessence Publishing: 2012:82-83.
27. Buser D, Mericske-Stern R, Bernard JP, et al. Long-term evaluation of nonsubmerged ITI implants. Part 1: 8-year life table analysis of a prospective multi-center study with 2359 implants. *Clin Oral Implants Res.* 1997;8:161–172.
28. Jensen OT, Shulman LB, Block MS, et al. Report of the sinus consensus conference of 1996. *Int J Oral Maxillofac Implants.* 1998;13(special suppl):11–32.
29. Călin C, Petre A, Drafta S. Osteotome-mediated sinus floor elevation: a systematic review and meta-analysis. *Int J Oral Maxillofac Implants.* 2014;29:558–576.
30. Tan WC, Zwahlen M, Lang NP, Pjetursson BE. A systematic review of the success of sinus floor elevation and survival of implants inserted in combination with sinus floor elevation. Part II – transalveolar technique. *J Clin Periodontol.* 2008;35(Suppl. 8):241–254.
31. Emmerich D, Att W, Stappert C. Sinus floor elevation using osteotomes: a systematic review and meta-analysis. *J Periodontol.* 2005;76:1237–1251.
32. Esposito M, Grusovin MG, Rees J, et al. Interventions for replacing missing teeth: Augmentation procedures of the maxillary sinus. *Cochrane Database Syst Rev.* 2010;CD008397.
33. Shalabi MM, Manders P, Mulder J, et al. A meta-analysis of clinical studies to estimate the 4.5-year survival rate of implants placed with the osteotome technique. *Int J Oral Maxillofac Implants.* 2007;22:110–116.

34. Rosen PS, Summers R, Mellado JR, et al. The bone-added osteotome sinus floor elevation technique: multicenter retrospective report of consecutively treated patients. *Int J Oral Maxillofac Implants*. 1999;14:853–858.
35. Sakoh J, Wahlmann U, Stender E, et al. Primary stability of a conical implant and a hybrid, cylindrical screw-type implant in vitro. *Int J Oral maxillofac Implants*. 2006;21:560–566.
36. Watzek G. Preface. In: Watzek G, ed. *The percrestal sinus lift - from illusion to reality*. New Malden, UK. Quintessence Publishing: 2012:v.
37. Al-Almaie S, Kavarodi AM, Al Faidhi A. Maxillary sinus functions and complications with lateral window and osteotome sinus floor elevation procedures followed by dental implants placement: a retrospective study in 60 patients. *J Contemp Dent Pract*. 2013;14:405–413.
38. Peñarrocha M, Pérez H, Garcíá A, Guarinos J. Benign paroxysmal positional vertigo as a complication of osteotome expansion of the maxillary alveolar ridge. *J Oral Maxillofac Surg*. 2001;59:106–107.
39. González-García A, González-García J, Diniz-Freitas M, et al. Accidental displacement and migration of endosseous implants into adjacent craniofacial structures: A review and update. *Med Oral Patol Oral Cir Bucal*. 2012;17:e769–774.
40. Griffa A, Viterbo S, Boffano P. Endoscopic-assisted removal of an intraorbital dislocated dental implant. *Clin Oral Implants Res*. 2010;21:778–780.
41. Fugazzotto PA. Implant placement at the time of maxillary molar extraction: Technique and report of preliminary results of 83 sites. *J Periodontol*. 2006;77:302–309.
42. Rocuzzo M, Wilson TG Jr. A prospective study of 3 weeks' loading of chemically modified titanium implants in the maxillary molar region: 1-year results. *Int J Oral Maxillofac Implants*. 2009;24:65–72.
43. Buser D, Schmid B, Belser UC, et al. The new bone level implants - Clinical rationale for the development and current indications for daily practice. *Int Dent SA*. 2010;12:58–66.
44. Nedir R, Nurdin N, Vazquez L, et al. Osteotome sinus floor elevation technique without grafting material: A five-year prospective study. *J Clin Periodontol*. 2010;37:1023–1028.

45. Sul SH, Choi BH, Li J, et al. Effects of sinus membrane elevation on bone formation around implants placed in the maxillary sinus cavity: an experimental study. *Oral Surg Oral Med Oral Pathol Oral Radiol Endod.* 2008;105:684–687.
46. Fenner M, Vairaktaris E, Stockmann P, et al. Influence of residual alveolar bone height on implant stability in the maxilla: an experimental animal study. *Clin Oral Implants Res.* 2009;20:751–755.
47. Cordaro L, Bosshardt DD, Palattella P, et al. Maxillary sinus grafting with Bio-Oss or Straumann Bone Ceramic: histomorphometric results from a randomized controlled multicenter clinical trial. *Clin Oral Implants Res.* 2008;19:796–803.

LEGENDS

Fig. 1. One-year radiographic measurements.

Distances **A** and **B** were measured along a parallel line of the implant axis on both implant sides. **A**: distance between the most coronal bone-implant contact and the most apical implant-bone contact; it expresses net bone anchorage height after 1 year for the implants placed without grafting material. **B**: distance between the most coronal bone-implant contact and the apical grafted dome; it expresses net bone anchorage height after 1 year for the implants placed with grafting material.

Fig. 2. Pre-surgery, post-surgery, and 1-year follow-up radiographs.

After one year, all implants were successful. All sites with RBH <10 mm gained endo-sinus bone.

Fig. 3. Radiographs and clinical views of posterior area of Patient 12.

The implant was placed using OSFE without grafting material (site 26, RBH = 7 mm).

Radiographic follow-up:

(a) Tooth 26 was extracted 9 months before implant placement. The site was completely healed at the time of implant placement. (b) Implant apex was embedded in the dome formed by the bone graft substitute. (c) Bone formation along implant sides was clearly visible at the 12-weeks after implant placement. (d, e) Bone densification was observable by radiographic contrast increase. (f) Computed tomography 1-year after loading.

Clinical follow-up:

(a) Situation before implant placement. (b-g) Surgery: (b) Flap elevation after mid-crestal incision and cortical bone marking with 3 round burs of increasing diameters; (c) Breaking of the sinus floor by light strokes on sinus osteotome with a mallet; (d) Control of the membrane integrity with an undersized depth gauge; (e) Filling of bone graft substitute; (2f) Placement of implant; (g) RFA measurements for primary stability assessment; coverscrews were then placed and flap was sutured.

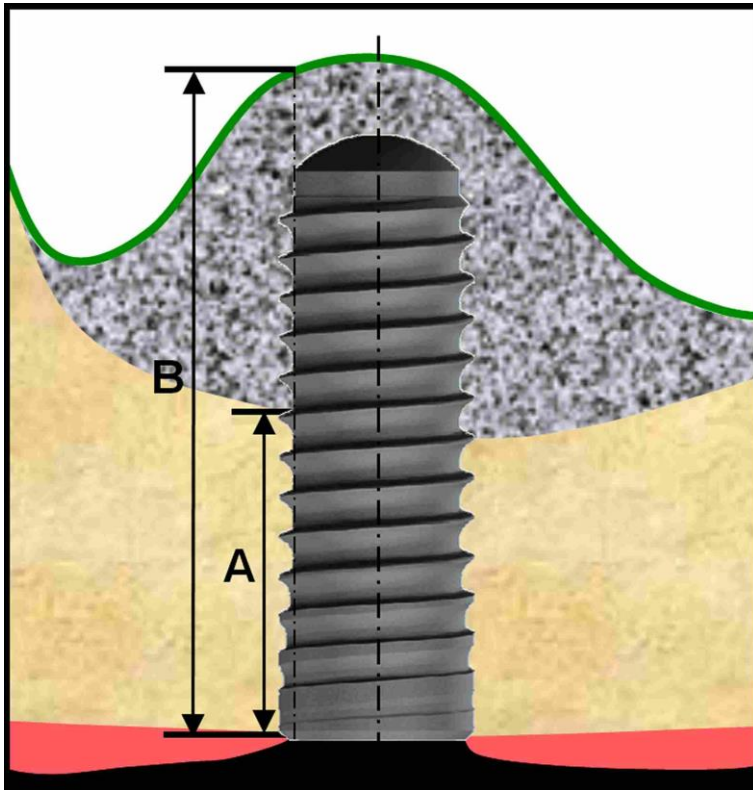

















Fig. 1. One-year radiographic measurements.

Distances **A** and **B** were measured along a parallel line of the implant axis on both implant sides. **A**: distance between the most coronal bone-implant contact and the most apical implant-bone contact; it expresses net bone anchorage height after 1 year for the implants placed without grafting material. **B**: distance between the most coronal bone-implant contact and the apical grafted dome; it expresses net bone anchorage height after 1 year for the implants placed with grafting material.

RBH (mm)	N° patient	Pre-surgery	Post-surgery	1-year
RBH \geq 10 mm	11			
6 < RBH < 10	3			
	6			
	9			
	15			































RBH ≤ 6	1			
	2			
	5			
	7			
	8			
	10			
	12			
				
	13			
	14			

Fig. 2. Pre-surgery, post-surgery, and 1-year follow-up radiographs.

After one year, all implants were successful. All sites with RBH <10 mm gained endo-sinus bone.

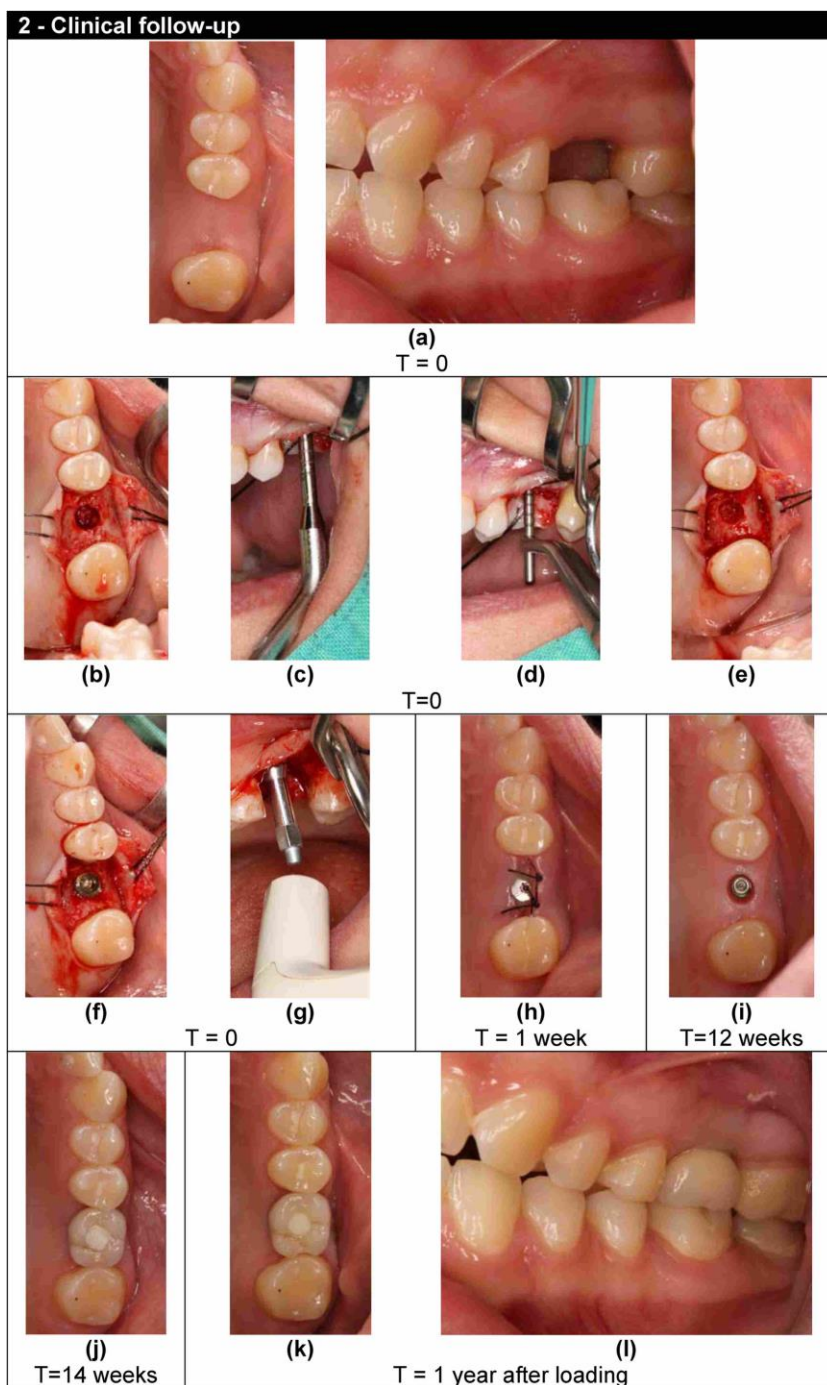
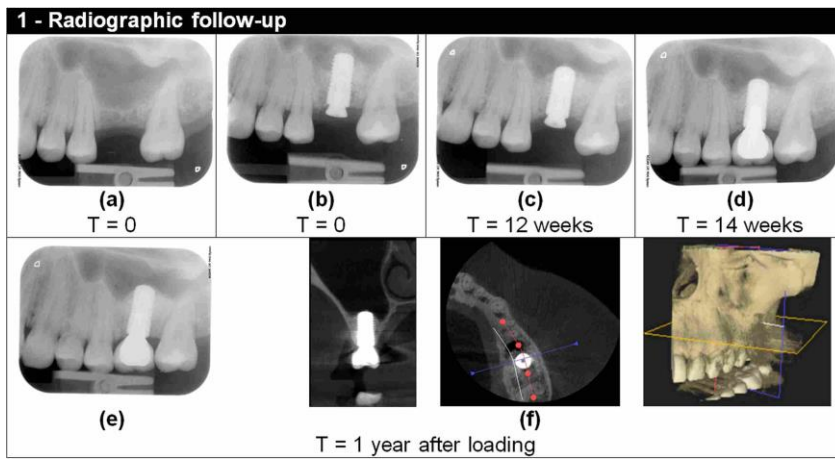


Fig. 3. Radiographs and clinical views of posterior area of Patient 12.

The implant was placed using OSFE without grafting material (site 26, RBH = 7 mm).

Radiographic follow-up:

(a) Tooth 26 was extracted 9 months before implant placement. The site was completely healed at the time of implant placement. (b) Implant apex was embedded in the dome formed by the bone graft substitute. (c) Bone formation along implant sides was clearly visible at the 12-weeks after implant placement. (d, e) Bone densification was observable by radiographic contrast increase. (f) Computed tomography 1-year after loading.

Clinical follow-up:

(a) Situation before implant placement. (b-g) Surgery: (b) Flap elevation after mid-crestal incision and cortical bone marking with 3 round burs of increasing diameters; (c) Breaking of the sinus floor by light strokes on sinus osteotome with a mallet; (d) Control of the membrane integrity with an undersized depth gauge; (e) Filling of bone graft substitute; (2f) Placement of implant; (g) RFA measurements for primary stability assessment; coverscrews were then placed and flap was sutured.