

Osteotome Sinus Floor Elevation without Grafting: A 10-Year Study of Cone-Beam Computerized Tomography versus Periapical X-Rays

Marc El Hage, DMD, MS¹, Nathalie Nurdin, PhD², Semaan Abi Najm, DMD, MS³
Mark Bischof, DMD⁴, RabahNedir, DMD⁵

¹Clinical Director, Swiss Dental Clinics Group, Ardentis Clinique Dentaire Lausanne, Lausanne, Switzerland.

²Senior Scientist, Swiss Dental Clinics Group, Ardentis Clinique Dentaire Vevey, Vevey, Switzerland.

³Clinical Director, Swiss Dental Clinics Group, Ardentis Clinique Dentaire Genève, Geneva, Switzerland.

⁴Clinical Director, Swiss Dental Clinics Group, Ardentis Clinique Dentaire Lausanne, Lausanne, Switzerland.

⁵Clinical Director, Swiss Dental Clinics Group, Ardentis Clinique Dentaire Vevey, Vevey, Switzerland.

Correspondence to: Dr Marc El Hage, Swiss Dental Clinics Group, Ardentis Clinique Dentaire Lausanne, Voie du Chariot 6, 1003 Lausanne, Switzerland.

E-mail: marc.elhage@ardentis.ch

Acknowledgements

The authors thank Dr Marc Carpentier (Clinical Research Center, University Hospitals of Geneva, Switzerland) for statistical assistance. They reported no conflicts of interest related to this study.

ABSTRACT

This article aims to evaluate and compare the 10-year bone anchorage and protrusion of implants into the sinus using cone-beam computerized tomography (CBCT) and periapical X-rays. Implants (≤ 10 mm) were placed with osteotome sinus floor elevation (OSFE) without grafting in maxillae of bone height ≤ 8 mm. After 10 years, the CBCT analysis showed bone at the buccal and palatal implant sides and corroborated the results obtained using periapical X-rays. In the absence of any symptom or complication, the use of two-dimensional radiography is sufficient for routine long-term follow-up of implants after OSFE without grafting.

INTRODUCTION

Implant rehabilitation in the posterior maxilla is a challenging procedure because the residual bone height (RBH) available for implant anchorage is reduced. At the majority of edentulous maxillary molar sites, the residual bone height is <7 mm.¹ Sinus elevation procedures increase bone volume by grafting the sinus cavity with autogenous bone and/or biomaterials.² The osteotome sinus floor elevation procedure (OSFE) was introduced by Summers.³ It involves the elevation of the Schneiderian membrane through a crestal access after the upwards fracturing of the sinus floor. The bone grafting material is then inserted in the space created and the implant is placed simultaneously. Together with the placement of short implants, the use of OSFE minimizes the need for extensive elevation of the sinus membrane and large volumes of graft material.⁴

As an alternative to OSFE with grafting material, graft-free sinus elevation was developed in order to decrease invasiveness and simplify treatments.⁵⁻⁹ The long-term predictability of OSFE without grafting and simultaneous implant placement has been recently demonstrated.¹⁰⁻¹² Published data favour the conclusion that the simultaneous use of grafting materials with the OSFE procedure has no significant advantage in terms of implant outcome, but this is usually based on two-dimensional radiographic analyses.^{9,12-14} Bone heights along osseointegrated implants protruding into the sinus are mainly assessed using periapical X-rays. Measurements are usually taken along the distal and mesial sides of the implant. The two-dimensional technique gives no information on bone presence or height at the buccal and palatal sides of the implants. Cone-beam computerized tomography (CBCT) allows cross-sectional imaging and three-dimensional reconstruction. However, recommendations for its use are established for diagnostic purposes

rather than follow-up examinations because of radiation exposure risks.¹⁵

Some short-term studies have used CBCT to assess the presence of bone around implants after OSFE without grafting.¹⁶⁻¹⁸ However, no evaluation comparing CBCT and periapical X-rays has been found in the literature for implants placed 10 years earlier. The aims of this study were to evaluate and compare, using CBCT and periapical X-rays, the 10-year bone anchorage and protrusion into the sinus of implants placed using OSFE without grafting.

Materials and Methods

Ethics Committee

The protocol of the 10-year study was approved by the Ethics Committee for Human Research of Vaud (Switzerland; protocol amendment number 393/12). In 2003, 17 patients were included in the study, according to the criteria presented in Table 1.⁶

Surgical and Prosthetic Procedures

Twenty-five cylindrical implants (Standard and Standard Plus SLA implants, Straumann AG, Basel, Switzerland) were placed simultaneously with an OSFE procedure without bone grafting. The surgical procedures and prosthetic rehabilitation have been reported previously.⁶

Radiographic Evaluation

The study hypotheses were:

- At 10 years, bone is present at the buccal and palatal sides of the implant and is sufficient to achieve long-term implant survival according to the criteria described

by Buser et al.;¹⁹ and,

- At 10 years, measurements of bone anchorage and implant protrusion obtained from CBCT images corroborate those obtained from periapical X-rays.

Radiographic data were collected by two investigators who were not involved in patient selection and surgery. The CBCT examinations were performed using CS 9300 apparatus (Carestream Health, Rochester, NY, USA) with the following settings: field-of-view: 10 x 5 cm², voxel size: 90 µm, tube voltage: 90 kV and tube current: 4 mA. Measurements on CBCT images were made using the open-source DICOM viewer OsiriX (version 1.2 64-bit; Pixmeo, Geneva, Switzerland). A 21.5 inch (diagonal) iMac monitor with a LED-backlit display of 1920-by-1080 resolution (Apple Inc, Copertino, USA) was used. Slices passing through the longitudinal hollow centre of each implant were chosen for the measurements.

Periapical X-rays were taken using the long-cone technique immediately after implant placement, at 3 and 6 months, and at 1, 3, 5 and 10 years.^{6,10,11} The radiographs were scanned in a digital format by a flatbed scanner (Epson Expression 1680 Pro, Wädenswil, Switzerland) at a resolution of 600 dpi. They were analyzed by a computerized measuring technique with image analysis software (Digora, Soredex, Helsinki, Finland) that measures the distance between two points. Internal calibration was performed for each radiograph on three inter-thread distances (3.75 mm), given that the tips of two consecutive threads are separated by 1.25 mm.

The bone anchorage and implant protrusion were recorded and then averaged at the mesial, distal, buccal and palatal sides of each implant on 10-year CBCT images (Fig 1) and at the mesial and distal sides on 10-year periapical X-rays (Fig 2).

Statistical Analysis

Descriptive statistics, mean and standard deviation, were used to assess the 10-year bone anchorage and protrusion of implants into the sinus. Mesial and distal bone levels measured using CBCT images and periapical X-rays was compared by means of a Student's t test. The threshold value for statistical significance was set at a P -value < 0.05. Bland–Altman analysis was used for comparison of the measurements obtained using the two radiographic techniques. The mean difference between measurements made using CBCT and periapical X-rays at the distal and mesial implant sides was plotted as a function of the average of the two measurements obtained with each technique.

Results

Two patients (two implants) died before the 10-year examination and two patients (two implants) refused the 10-year CBCT examination. The 13 remaining patients (13 women, mean age: 57.2 ± 6.4 years; 21 implants) attended the 10-year examination. For these patients, the mean residual bone height was 5.6 ± 1.9 mm at the time of surgery. Sinus perforation occurred in two implant sites. Figure 3 shows post-operative periapical X-rays of the 21 studied implants.

All 21 implants were functional and clinically stable at 10 years. They were reliably assessed on periapical X-rays (Fig 3), whereas CBCT image quality for eight out of the 21 implants was not sufficient to allow bone height measurements in at least one dimension. Table 2 shows mean bone anchorage and protrusion values measured at each side of the implants. On the 10-year CBCT images, bone was present not only at the mesial and distal sides of the implants but also at the

palatal and buccal sides. The mean bone anchorage was 7.8 ± 1.4 mm and the mean length of implant protrusion was 1.4 ± 1.0 mm. The apex of eight implants was completely embedded in bone on at least one side.

The mean bone anchorage measured on the 10-year periapical X-rays was 7.7 ± 1.3 mm and the mean length of implant protrusion into the sinus was 1.8 ± 1.1 mm after 10 years. The apex of three implants was completely embedded in bone on at least one side. There was no significant difference between the mean values of mesial and distal bone anchorage and protrusion measured on periapical X-rays and CBCT images. The two sites in which sinus perforation occurred showed a mean bone anchorage of 7.1 ± 1.2 mm at the buccal side and 6.1 ± 1.3 mm at the palatal side, respectively. The mean protrusion into the sinus was 0.3 ± 0.5 mm and 1.0 ± 0.1 mm, respectively.

When comparing the measurements obtained with CBCT and periapical X-rays, the agreement between them ranged from -2.3 to 2.2 mm for the measurement of bone anchorage and from -2.4 mm to 1.7 mm for the measurement of implant protrusion (Fig 4). Data of two implants (two patients) were outside the limits of agreement for the measurement of protrusion. They were overestimated when measured with periapical X-rays. In the first case, implant protrusion on the distal side was 4.4 mm on the periapical X-ray and 1.4 mm on CBCT. In the second case, implant protrusion on the mesial side was 3.9 mm and 0.65 mm, respectively (Fig 5).

Discussion

In dentistry, CBCT is used for multiple indications including the assessment of impacted teeth and osseous lesions, the localization of vital structures and the

evaluation of periapical lesions.^{20,21} In implant dentistry, CBCT is justified as a pre-operative examination in the presence of bone defects, for the examination of intra-oral donor sites, in cases requiring computer-assisted planning and placement, as well as those with post-operative complications.¹⁵ The technique is recommended particularly when the clinical examination and conventional X-rays are not sufficient to evaluate the edentulous sites completely and accurately.^{22,23} For sinus grafting procedures in the posterior maxilla, the use of preoperative CBCT provides information on sinus anatomy and allows precise measurement of the residual bone height in the region of interest.¹⁵

Few studies have evaluated the posterior maxilla with CBCT long after insertion of the implant. In order to assess the buccal bone, CBCT was used at the 10-year examination of implants placed with an early, delayed, or late implant placement protocol.²⁴ Aparicio et al. used CBCT to evaluate the 10-year outcomes of zygoma implants placed in 22 patients.²⁵ To the authors' knowledge, no long-term (>5 years) CBCT follow-up evaluation has ever been carried out for implants placed with sinus grafting. The present study is believed to be the first to involve assessment on CBCT images of implants placed 10 years earlier using a sinus floor elevation procedure.

Three studies have evaluated implants with CBCT after OSFE without grafting.¹⁶⁻¹⁸ However, the reported follow-up periods did not extend more than two years after implant placement. In a one-year study of 21 implants, Fornell et al. reported a mean bone gain of 3.0 ± 2.1 mm and a mean implant protrusion of 2.1 ± 1.7 mm (range 0–5.7 mm), measured in the mesial, distal, buccal and palatal dimensions.¹⁶ He et al. performed CBCT examinations post-operatively and six months after implant placement.¹⁷ Bone levels were measured only at the mesial

and distal sides of the implant. The mean bone gain was 2.5 ± 1.5 mm at six months, and the mean implant protrusion was reduced from 3.8 mm post-operatively to 1.3 mm after 6 months. Marković et al. compared osteotome sinus floor elevation with and without bone grafting. Shrinkage of the endo-sinus bone volume between six months and two years was recorded post-operatively. It was more pronounced for β -tricalcium phosphate (61.44%) and deproteinized bovine bone (66.34%) alone than for their combination (33.47%). In the absence of grafting, bone loss was 53.02%. About 52% of implants showed a denuded palatal side or a thinner bone layer on this side.¹⁸

In the present study, bone anchorage was defined as the effective implant length in contact with surrounding bone. Therefore, this measurement took into account the endo-sinus bone gain maintained over the 10 years after implant insertion as well as the crestal bone loss occurring over the same period. Bone anchorage was shown to be sufficient, on the four sides of the implants, to achieve long-term implant survival. The measurements performed at the buccal and palatal sides of the implants were of the same order of magnitude as those at the mesial and distal sides. The values obtained on all sides of implants for which membrane perforation occurred during placement were of the same order of magnitude. The mean bone anchorage and implant protrusion into the sinus measured on CBCT images were similar to those measured using periapical X-rays. Evaluation of buccal and palatal bone anchorage does not provide additional information to the practitioner that is useful for long-term clinical assessment of an implant. Therefore, CBCT examination does not seem to be critical for the radiological follow-up evaluation of implants placed with OSFE without grafting.

The protrusion measurements conducted on CBCT images were in the same

range as those obtained by Fornell et al.¹⁶ Furthermore, only three implants appeared to be completely embedded in bone on at least one side on the periapical X-rays, while eight appeared so on the CBCT images. In two cases, implant protrusion into the sinus was overestimated on periapical X-rays. Although strong conclusions cannot be drawn from such a limited number of cases, apical X-rays seem to overestimate implant protrusion into the sinus. This should be taken into consideration when conducting routine apical follow-up assessments using X-rays. One must note that the use of a medical diagnostic monitor for the radiographic measurements would have been more appropriate. In the present study, a commercial monitor was used and thus might be a source of bias regarding the identification of subtle lesions. However, since this study doesn't aim to diagnose specific lesions but to perform measurements, the effect of the monitor type has low incidence. Furthermore, it has been reported that using commercial color LCDs may not compromise the diagnostic accuracy.²⁶

Metallic objects such as dental implants generate artifacts that reduce CBCT image quality.²⁷ In the present study, this drawback interfered with the mesial and distal measurements for adjacent implants. About 8% of measurements were not obtained because of insufficient CBCT image quality, whereas periapical X-rays had no sites classified as unreadable. In contrast with a previous report,¹⁶ the missing CBCT measurements were not replaced with the corresponding values obtained on periapical X-rays. The issue of artifacts observed on CBCT images would be improved by more advanced software programs.²⁷ These software programs filter the region of artifacts by adjusting grayscale values of voxels according to the outside of this region. However, the images obtained are the result of gray scale homogenization but not the true representation of the studied area.²⁷

The initial prospective study was a pilot one, having thus a small number of included patients.⁶ At 10 years, drop-out has furthermore limited the number of remaining implants to examine since two patients died and two refused the CBCT examination. This should be clearly taken into consideration when analysing the results of this study. More and more patients are reluctant to undergo diagnostic and follow-up X-ray examination. This is in line with an observed trend of patients being more conscious of medical radiation exposure.²⁹

Conclusions

The use of CBCT showed that OSFE without grafting induced bone formation not only at the mesial and distal sides of the implants but also at the buccal and palatal sides. The bone present along the implants might be sufficient to ensure long-term implant survival over 10 years. Within the limits of this study, the values of bone anchorage and implant protrusion into the sinus measured on CBCT images corroborated the results obtained with periapical X-rays. In the absence of any symptom or complication, the use of two-dimensional radiography may be sufficient for routine long-term follow-up of implants after OSFE without grafting.

References

1. Pramstraller M, Farina R, Franceschetti G, Pramstraller C, Trombelli L. Ridge dimensions of the edentulous posterior maxilla: a retrospective analysis of a cohort of 127 patients using computerized tomography data. *Clin Oral Implants Res* 2011;22:54–61.
2. Esposito M, Grusovin MG, Rees J, et al. Interventions for replacing missing teeth: Augmentation procedures of the maxillary sinus. *Cochrane Database Syst Rev* 2010;17:CD008397.
3. Summers RB. The osteotome technique. Part 3. Less invasive methods in elevation of the sinus floor. *Compend Contin Educ Dent* 1994;15:698–708.
4. Toffler M. Treating the atrophic posterior maxilla by combining short implants with minimally invasive osteotome procedures. *Pract Proced Aesthet Dent*. 2006;18:301–308.
5. Leblebicioglu B, Ersanli S, Karabuda C, Tosun T, Gokdeniz H. Radiographic evaluation of dental implants placed using an osteotome technique. *J Periodontol* 2005;76:385–390.
6. Nedir R, Nurdin N, Vazquez L, Szmukler-Moncler S, Bischof M, Bernard JP. Osteotome sinus floor elevation without grafting material: a 1-year prospective pilot study with ITI implants. *Clin Oral Implants Res* 2006;17:679–686.
7. Pjetursson BE, Rast C, Brägger U, Schmidlin K, Zwahlen M, Lang NP. Maxillary sinus floor elevation using the (transalveolar) osteotome technique with or without grafting material. Part I. Implant survival and patients' perception. *Clin Oral Implants Res* 2009;20:667–676.
8. Lai HC, Zhuang LF, Lv XF, Zhang ZY, Zhang YX, Zhang ZY. Osteotome sinus floor elevation with or without grafting: a preliminary clinical trial. *Clin Oral*

- Implants 2010;21:520–526.
9. Nedir R, Nurdin N, Khoury P, et al. Osteotome sinus floor elevation with and without grafting material in the severely atrophic maxilla. A 1-year prospective randomized controlled study. *Clin Oral Implants Res* 2013;24:1257–1264.
 10. Nedir R, Nurdin N, Vazquez L, Szmukler-Moncler S, Bischof M, Bernard JP. Osteotome sinus floor elevation technique without grafting: a 5-year prospective study. *J Clin Periodontol* 2010;37:1023–1028.
 11. Nedir R, Nurdin N, Vazquez L, Abi Najm S, Bischof M. Osteotome sinus floor elevation without grafting: A 10-year prospective study. *Clin Implant Dent Relat Res* 2016;18:609–617.
 12. Nedir R, Nurdin N, Abi Najm S, El Hage M, Bischof M. Short implants placed with or without grafting into atrophic sinuses: the 5-year results of a prospective randomized controlled study. *Clin Oral Implants Res* 2017;28:877–886.
 13. Si MS, Zhuang LF, Gu YX, Mo JJ, Qiao SC, Lai HC. Osteotome sinus floor elevation with or without grafting: a 3-year randomized controlled clinical trial. *J Clin Periodontol* 2013;40:396–403.
 14. Nedir R, Nurdin N, Khoury P, Bischof M. Short implants placed with or without grafting in atrophic sinuses: the 3-year results of a prospective randomized controlled study. *Clin Implant Dent Rel Res* 2016;18:10–18.
 15. Harris D, Horner K, Gröndahl K, et al. E.A.O. guidelines for the use of diagnostic imaging in implant dentistry 2011. A consensus workshop organized by the European Association for Osseointegration at the Medical University of Warsaw. *Clin Oral Implants Res* 2012;23:1243–1253.
 16. Fornell J, Johansson LA, Bolin A, Isaksson S, Sennerby L. Flapless, CBCT-

- guided osteotome sinus floor elevation with simultaneous implant installation. I: radiographic examination and surgical technique. A prospective 1-year follow-up. *Clin Oral Implants Res* 2012;23:28–34.
17. He LL, Chang X, Liu Y. Sinus floor elevation using osteotome technique without grafting materials: a 2-year retrospective study. *Clin Oral Implants Res* 2013;24 (Suppl. A100):63–67.
 18. Marković A, Mišić T, Calvo-Guirado JL, Delgado-Ruíz RA, Janjić B, Abboud M. Two-center prospective, randomized, clinical, and radiographic study comparing osteotomes inus floor elevation with or without bone graft and simultaneous implant placement. *Clin Implant Dent Relat Res* 2016;18:873–882.
 19. Buser D, Mericske-Stern R, Bernard JP, et al. Long-term evaluation of non-submerged ITI implants. Part 1: 8-year life table analysis of a prospective multi-center study with 2359 implants. *Clin Oral Implants Res* 1997;8:161–172.
 20. Patel S, Durack C, Abella F, Shemesh H, Roig M, Lemberg K. Cone beam computed tomography in Endodontics - a review. *Int Endod J* 2015;48:3–15.
 21. AAE and AAOMR Joint Position Statement. Use of Cone Beam Computed Tomography in Endodontics 2015 Update. *Oral Surg Oral Med Oral Pathol Oral Radiol* 2015;120:508–512.
 22. Bornstein MM, Al-Nawas B, Kuchler U, Tahmaseb A. Consensus statements and recommended clinical procedures regarding contemporary surgical and radiographic techniques in implant dentistry. *Int J Oral Maxillofac Implants* 2014;29 (Suppl):78–82.
 23. Bornstein MM, Scarfe WC, Vaughn VM, Jacobs R. Cone beam computed

- tomography in implant dentistry: a systematic review focusing on guidelines, indications, and radiation dose risks. *Int J Oral Maxillofac Implants* 2014;29 (Suppl):55–77.
24. Schropp L, Wenzel A, Spin-Neto R, Stavropoulos A. Fate of the buccal bone at implants placed early, delayed, or late after tooth extraction analyzed by cone beam CT: 10-year results from a randomized, controlled, clinical study. *Clin Oral Implants Res* 2015;26:492–500.
 25. Aparicio C, Manresa C, Francisco K et al. The long-term use of zygomatic implants: a 10-year clinical and radiographic report. *Clin Implant Dent Relat Res* 2014;16:447-459.
 26. Wu J, Wu TH, Han RP, et al. Comparison of the commercial color LCD and the medical monochrome LCD using randomized object test patterns. *PLoS One*. 2012;7(5):e37769.
 27. Benavides E, Rios HF, Ganz SD, et al. Use of cone beam computed tomography in implant dentistry: the International Congress of Oral Implantologists consensus report. *Implant Dent* 2012;21:78–86.
 28. Makins SR. Artifacts interfering with interpretation of cone beam computed tomography images. *Dent Clin N Am* 2014;58:485–495.
 29. Dauer LT, Thornton RH, Hay JL, Balter R, Williamson MJ, St Germain J. Fears, feelings, and facts: interactively communicating benefits and risks of medical radiation with patients. *Am J Roentgenol* 2011;196:756–761.

Legends of figures

Fig 1 Parameters measured on CBCT images:

bone anchorage: distance from the most coronal to the most apical bone-implant contact, measured at the mesial (Am), distal (Ad), buccal (Ab) and palatal (Ap) sides, and

implant protrusion: length of the implant protruding into the sinus, measured at the mesial (Pm), distal (Pd), buccal (Pb) and palatal (Pp) sides.

Fig 2 Parameters measured on periapical X-rays:

bone anchorage: distance from the most coronal to the most apical bone-implant contact, measured at the mesial (Am) and distal (Ad) sides, and

implant protrusion: length of the implant protruding into the sinus, measured at the mesial (Pm) and distal (Pd) sides.

Fig 3 Post-operative and 10-year periapical radiographs of cases (a) 1-7, and (b) 8, 10, 11, 13, 15 and 17.

Fig 4 Agreement between measurements obtained using CBCT and periapical X-rays of bone anchorage and implant protrusion into the sinus at the mesial and distal side. The difference (mm) between CBCT and periapical X-ray measurements is plotted as a function of the average of the two measurements (mm) obtained with each technique.

The straight horizontal line represents the mean difference between the measurements made using CBCT and periapical X-rays. The dotted lines show the confidence interval and the dashed horizontal lines the limits of agreement. In red: protrusion measurements outside the limits of

agreement (patient 8, implant 26 and patient 4, implant 16).

Fig 5 Overestimation of implant protrusion into the sinus on periapical X-rays in comparison with CBCT images (patient 8, implant 26 and patient 4, implant 16).

Legends of tables

Table 1 Inclusion and Exclusion Criteria for Patient Participation in the Study.

Table 2 Mean Bone Anchorage and Implant Protrusion (Mean \pm Standard Deviation) Measured with Periapical X-rays and CBCT at the Mesial, Distal, Buccal and Palatal Sides of the Implants.

P-value expresses the significance of the difference in mean values measured using periapical X-rays and CBCT.

N is the number of implant sides analysed.

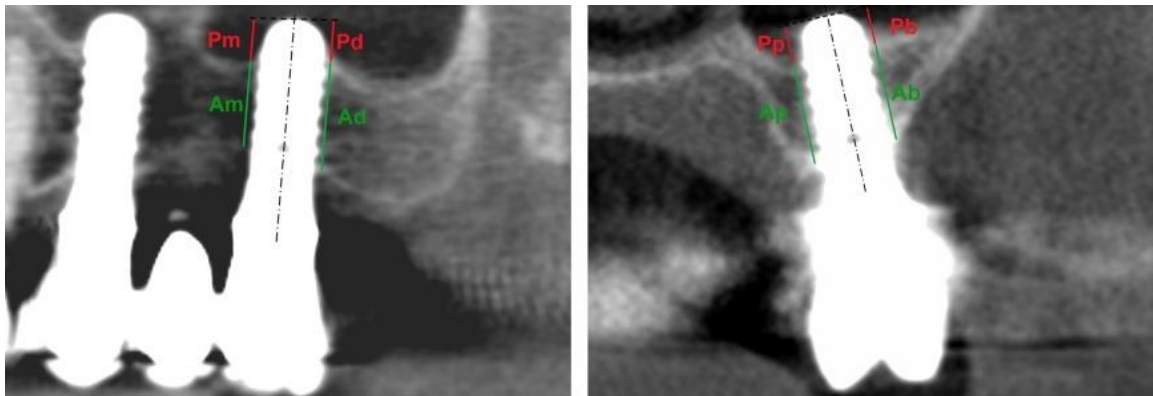


Fig 1 Parameters measured on CBCT images:

bone anchorage: distance from the most coronal to the most apical bone-implant contact, measured at the mesial (Am), distal (Ad), buccal (Ab) and palatal (Ap) sides, and

implant protrusion: length of the implant protruding into the sinus, measured at the mesial (Pm), distal (Pd), buccal (Pb) and palatal (Pp) sides.

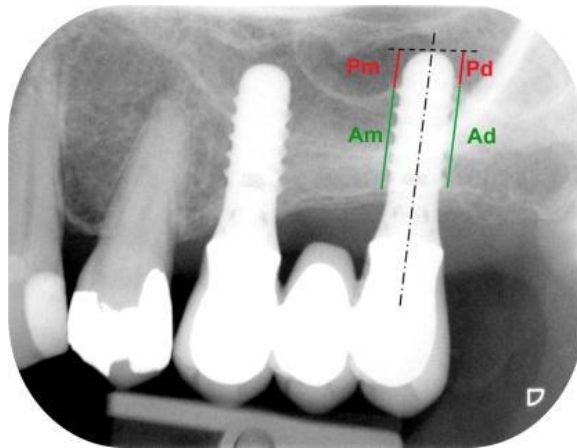





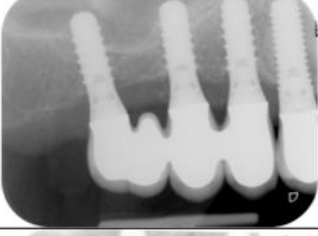










Fig 2 Parameters measured on periapical X-rays:

bone anchorage: distance from the most coronal to the most apical bone-implant contact, measured at the mesial (Am) and distal (Ad) sides, and implant protrusion: length of the implant protruding into the sinus, measured at the mesial (Pm) and distal (Pd) sides.

Patient number	Sites	Post-operative	Year 10
1	26		
2	14-16		
3	16, 17		
4	16		
5	16		
6	25		
7	15		

(a)


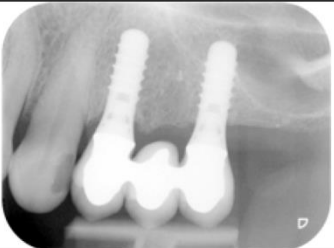
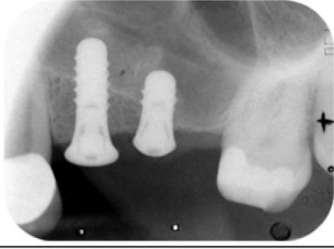


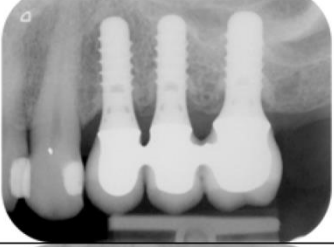


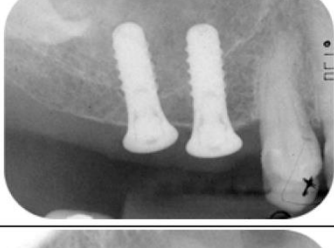

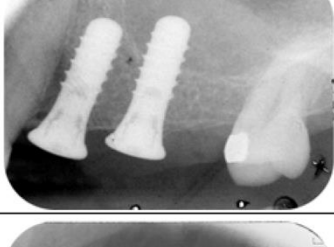

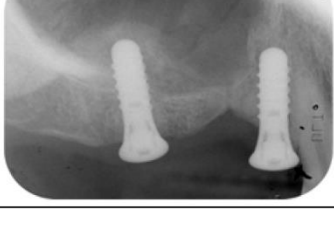
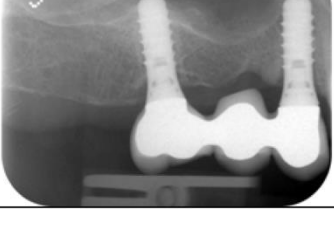
Patient number	Sites	Post-operative	Year 10
8	26		
10	24, 25		
11	25, 26		
13	25, 26		
15	15, 16		
	25		
17	16		

Fig 3 Post-operative and 10-year periapical radiographs of cases (a) 1-7, and (b) 8, 10, 11, 13, 15 and 17.

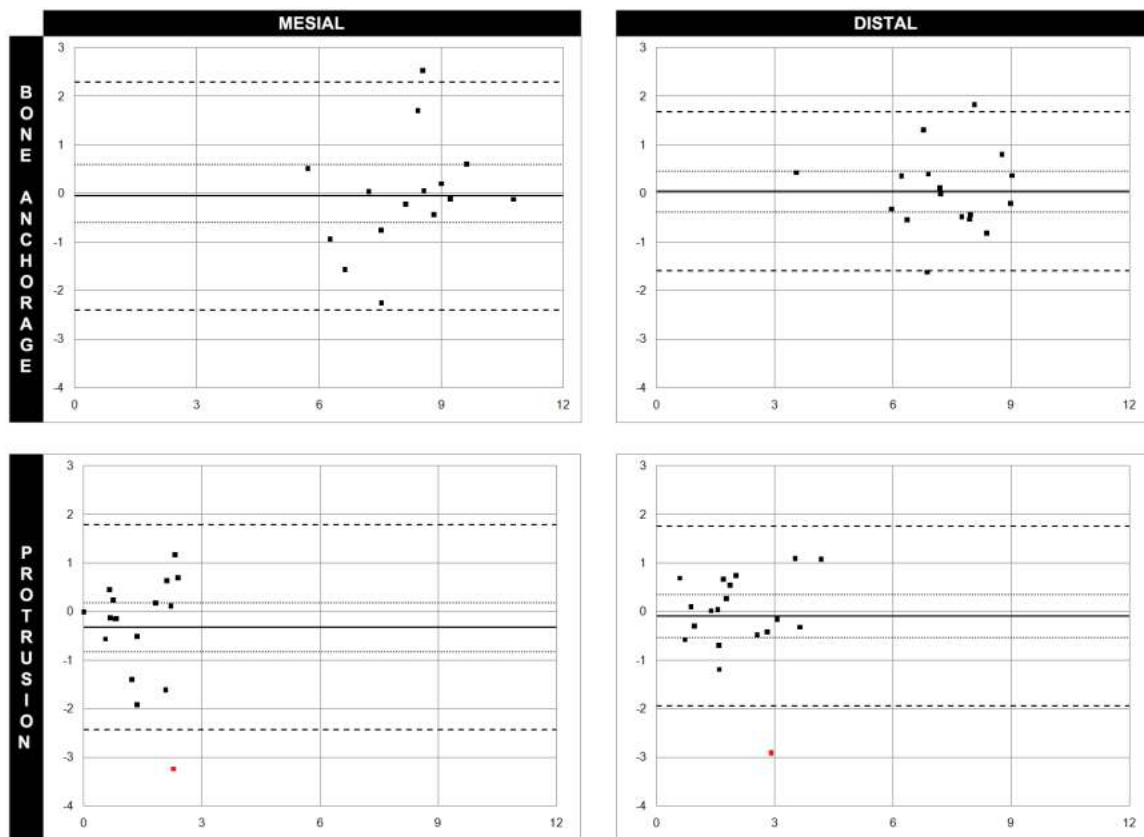


Fig 4 Agreement between measurements obtained using CBCT and periapical X-rays of bone anchorage and implant protrusion into the sinus at the mesial and distal side. The difference (mm) between CBCT and periapical X-ray measurements is plotted as a function of the average of the two measurements (mm) obtained with each technique. The straight horizontal line represents the mean difference between the measurements made using CBCT and periapical X-rays. The dotted lines show the confidence interval and the dashed horizontal lines the limits of agreement. In red: protrusion measurements outside the limits of agreement (patient 8, implant 26 and patient 4, implant 16).

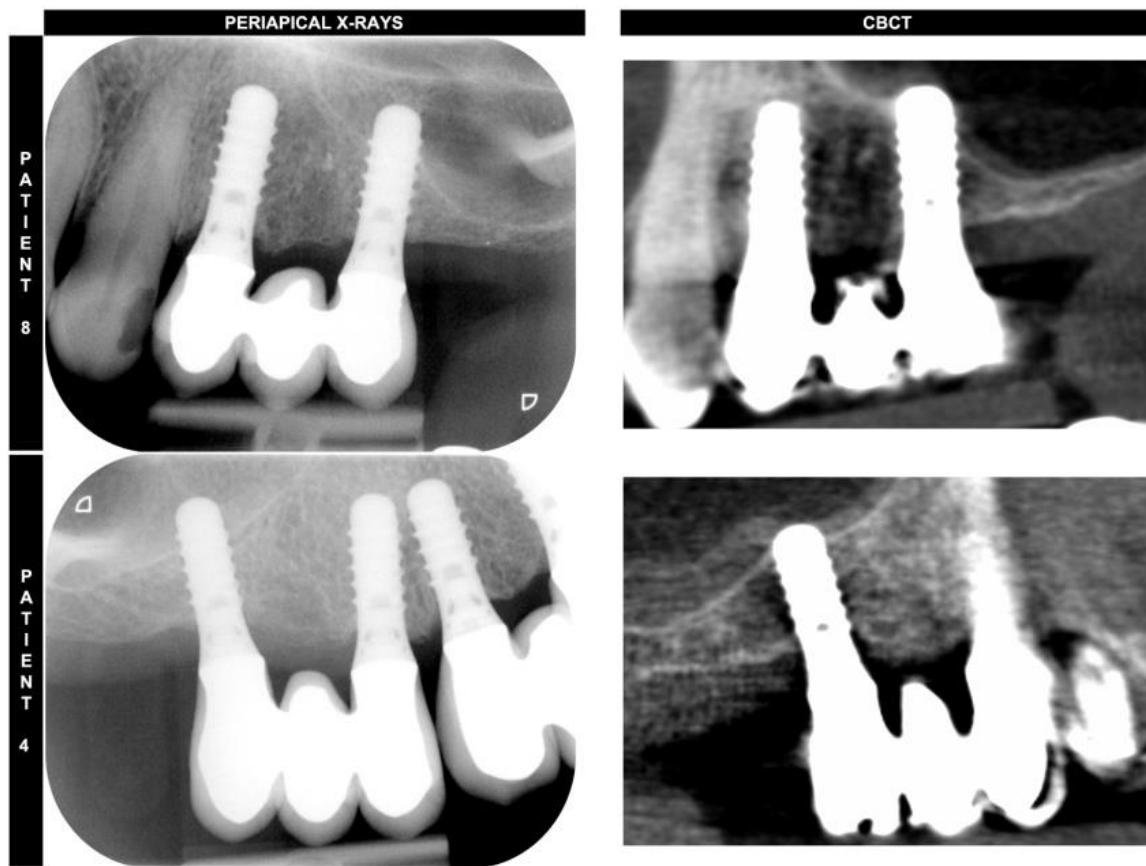


Fig 5 Overestimation of implant protrusion into the sinus on periapical X-rays in comparison with CBCT images (patient 8, implant 26 and patient 4, implant 16).

Inclusion criteria

Patients required implant treatment in the posterior maxilla (sites 14–17, 24–27).

The OSFE procedure was performed without grafting material.

Ten millimeter implants were used; shorter implants (6 and 8 mm) were inserted only in cases with sinus membrane perforation.

The residual bone height between the crest and the sinus floor, measured on a panoramic radiograph at each implant site, was ≤ 8 mm.

More than 1 mm of bone was present on the mesial and distal sides to ensure implant stability.

The implant penetrated at least 2 mm into the sinus on the mesial or distal implant sides.

Patients did not wear a removable partial denture during the healing period.

Patients attended the 10-year examination and consented to cone-beam computed tomography.

Exclusion criteria

Medical history of acute or chronic sinusitis.

Active periodontal disease, diabetes, or metabolic bone disease.

Lack of primary implant stability.

Table 1 Inclusion and Exclusion Criteria for Patient Participation in the Study.

		CBCT	Periapical X-rays	P-value
Mean bone anchorage (mm)	Mesial	8.1 ± 1.6 N=15	8.1 ± 1.2 N = 21	0.93
	Distal	7.3 ± 1.4 N=17	7.3 ± 1.3 N = 21	0.93
	Buccal	8.1 ± 1.4 N = 21	-	-
	Palatal	7.9 ± 1.3 N = 21	-	-
Mean implant protrusion (mm)	Mesial	1.1 ± 0.9 N = 19	1.5 ± 1.1 N = 21	0.32
	Distal	2.0 ± 1.1 N = 19	2.1 ± 1.1 N = 21	0.80
	Buccal	1.1 ± 0.8 N = 21	-	-
	Palatal	1.4 ± 1.1 N = 21	-	-

Table 2 Mean Bone Anchorage and Implant Protrusion (Mean ± Standard Deviation) Measured with Periapical X-rays and CBCT at the Mesial, Distal, Buccal and Palatal Sides of the Implants.

P-value expresses the significance of the difference in mean values measured using periapical X-rays and CBCT.

N is the number of implant sides analysed.