

*Osteotome Sinus Floor Elevation Without Grafting: A 10-Year Clinical and Cone-Beam Sinus Assessment*

**AUTHORS:** Semaan Abi Najm, DMD, MS\*, Nathalie Nurdin, PhD\*\*, Marc El Hage, DMD, MS\*\*\*, Mark Bischof, DMD#, and Rabah Nedir, DMD##

**ABSTRACT (180 WORDS)**

**Purpose:** To evaluate the thickness of the sinus membrane in contact with implants inserted 10 years before using an augmentation procedure without grafting material, and to identify adverse events correlated with implant protrusion in the sinus.

**Materials and Methods:** Osteotome sinus floor elevations (OSFE) were performed without grafting material. The implants (Straumann AG) were placed simultaneously. All protruded into the sinus. After 10 years, implants were considered viable in the absence of mobility, pain, infection or continued radiolucency. Sinus health was assessed in using cone-beam computed tomography (CBCT) and by the way of a questionnaire in which patients reported symptoms of sinusitis they might have had.

**Results:** Controlled implants (21 implants, 13 patients) were osseointegrated. The membrane thickness was <2 mm in 11 patients and 2–3 mm with flat thickening in two patients. No patients exhibited any clinical or radiographic signs of sinusitis.

**Conclusions:** No sinus complications were observed after 10 years. The initial protrusion of implants into the sinus did not influence long-term sinus health. The maintenance of successful integration is thus the key to avoiding sinus complication.

**KEY WORDS:** dental implant, Schneiderian membrane, maxillary sinusitis, cone-beam computed tomography

\* Clinical director, Swiss Dental Clinics Group, Ardentis Clinique Dentaire Geneva, Geneva, Switzerland; Senior lecturer, Department of Oral and Maxillofacial Surgery, Oral Surgery and Implantology Unit, Geneva University Hospitals, Geneva, Switzerland

\*\* Senior scientist, Swiss Dental Clinics Group, Ardentis Clinique Dentaire Vevey, Vevey, Switzerland.

\*\*\*Clinical director, Swiss Dental Clinics Group, Ardentis Clinique Dentaire Lausanne, Lausanne, Switzerland.

#Clinical director, Swiss Dental Clinics Group, Ardentis Clinique Dentaire Lausanne, Lausanne, Switzerland.

##Clinical director, Swiss Dental Clinics Group, Ardentis Clinique Dentaire Vevey, Vevey, Switzerland.

***Reprint requests and correspondence to:*** Simon Abi Najm, DMD, MS, Ardentis Clinique Dentaire Geneva, Rue Thomas-Mazaryk 1, 1202 Geneva, Switzerland,

Phone: +41 58 234 01 10

E-mail: [simon.abinajm@ardentis.ch](mailto:simon.abinajm@ardentis.ch)

Osseointegrated implants are now the therapy of choice for rehabilitating edentulous ridges.<sup>1-4</sup> Pneumatization of the sinus and resorption of the alveolar ridge causes the available bone height to be limited in the posterior maxilla. Therefore, to provide an adequate bone support for the placement of implants, many attempts have been made to improve bone augmentation techniques.<sup>5-7</sup> In 1994, Summers<sup>7</sup> introduced the osteotome sinus floor elevation (OSFE). This procedure involving the elevation of the sinus membrane using a transcrestal approach via implant bed preparation is considered simple, reliable and less invasive than the lateral sinus lift procedure. Furthermore, only one surgery is generally required to undertake the bone augmentation and place the implant. In using short implants, the membrane elevation is minimized and smaller volumes of graft are inserted.<sup>8</sup> Bone has been shown to form beneath the sinus membrane without the use of grafting material.<sup>9</sup> The survival or success rates of the implants were not significantly different, whether any grafting material was used or not.<sup>10-12</sup> Implant survival rates after 10 years can be as high as 95% using an OSFE procedure without grafting.<sup>13</sup>

When the implants are placed immediately after the OSFE without grafting, they come in direct contact with the Schneiderian membrane and penetrate the maxillary sinus. The long-term reaction of the sinus membrane after the use of OSFE is rarely reported in the literature. Where some attention has been paid to maxillary sinus symptoms related to implants and sinus grafting,<sup>14-20</sup> the incidence and clinical relevance of these symptoms are still debatable.<sup>21-27</sup>

The aim of this prospective study was to document the long-term outcomes of sinus health after the insertion of implants in atrophic posterior maxilla. Adverse events related to the protrusion in the sinus of implants inserted 10 years previously using OSFE without any grafting material were collected, and the thickness of the sinus membrane was assessed.

## **MATERIALS AND METHODS**

### **Ethics Committee and Patient Recruitment**

The protocol of the 10-year control received approval from the Ethics Committee for Human Research of Vaud (Switzerland) under reference number CER-VD 393/12. Figure 1 shows the inclusion and exclusion criteria for patient recruitment. In 2003, 17 patients (14 women and three men;  $54.2 \pm 9.6$  years, range: 38–69 years) were selected for implant surgery. Their posterior maxilla showed a mean maxillary residual bone height of  $5.4 \pm 2.3$  mm.<sup>28</sup>

### **Surgical and Prosthetic Procedures**

The procedures used were described previously.<sup>28</sup> OSFE without grafting was performed and 25 standard endosseous implants (Straumann AG, Basel, Switzerland) were placed simultaneously. The length of the implants was 10 mm except for three implants of 8 mm and one of 6 mm placed in sites where membrane perforation had occurred. Three months after surgery, the implants were osseointegrated and rehabilitated with single crowns and fixed partial dentures of two or three units.

### **Clinical and Radiographic Control**

Implants were considered viable in the absence of clinically detectable implant mobility, pain, or any subjective sensation, recurrent peri-implant infection, or continuous radiolucency around the implant.<sup>3</sup>

At the 10-year control, the patients were asked to fulfill a questionnaire on sinus events.<sup>29</sup> The questionnaire examined the following symptoms: mucopurulent drainage, nasal obstruction, facial pain-pressure fullness, and decreased sense of smell. Other factors -headache, dental pain, halitosis, fatigue, cough, ear pain, and fever- were also taken into consideration. Acute rhinosinusitis was diagnosed in cases of  $\leq 4$  weeks of purulent (not clear) nasal drainage, accompanied by nasal obstruction, facial pain-pressure fullness, or both. Chronic rhinosinusitis was diagnosed if two or more symptoms persisted beyond 12 weeks.<sup>22</sup>

Cone-beam computed tomography (CBCT) was performed using a CS 9300 CBCT unit (Carestream Health, Inc., Rochester, NY, USA). After exporting in DICOM format, analysis of the CBCT images was performed using OsiriX software (Pixmeo Sàrl, Geneva, Switzerland). On the sagittal section, membrane thicknesses were measured at the apex and on the mesial and distal sides of the implant whereas, on the coronal section, they were measured on the oral and buccal sides and also at the apex. They were measured

from the mucosal surface to underlying bone plate of the sinus along with the implant axis (Figures 2 and 3). The highest value of apex measurements was reported. The mean, standard deviation and range were calculated for the four implant sides and apex. Membranes were broadly categorized as either “normal” when all five measurements around the implant were less than or equal to 2 mm, or “flat thickening” when at least one measurement was greater than 2 mm (Figure 3).<sup>30–33</sup> Flat thickening can be described as a shallow thickening without well-defined outlines.<sup>31</sup> Radiographic analysis and measurements were performed twice, but not the same day, by one investigator not involved in the surgical procedure and follow-up of patients (SAN).

## RESULTS

During the 10-year follow-up period, two patients died. At the 10-year control, two patients refused CBCT examination. Therefore, of the 17 patients who underwent surgery and prosthetic restoration, 13 women (mean age:  $57.2 \pm 6.4$  years) were included. Two patients were smokers. The mean maxillary residual bone height at the time of surgery was  $5.6 \pm 1.9$  mm.

Twenty-one implants were placed in 14 sinuses. Sinus membrane perforation was clinically diagnosed at implant placement for three implant sites (two implants in one patient and one in another). The 10-year CBCT examination revealed that the membrane had healed over the three implants (Fig. 4).

At the 10-year examination, all implants were stable and functional, and all were osseointegrated. The survival rate was 100%. None of the patients showed any evident clinical or radiographic signs of sinusitis. However, four patients noted sinus-related symptoms that were not a consequence of implant placement in the maxillary sinus: two patients reported posterior flow that existed before the placement of implants; one described dry mouth and hyposmia related to Gougerot–Sjögren disease diagnosed after implant insertion; and another reported maxillary fullness due to one viral infection.

Table 1 shows values of membrane thickness for all examined implants. Membrane was not detectable thus not readable for six out of 105 measured sides of the 21 implants. The mean values of membrane thickness were  $0.66 \pm 0.30$  mm (range: 0.29–1.10) at the apex and  $1.29 \pm 0.39$  mm (range: 0.54–2.00),  $1.41 \pm 0.47$  mm (range: 0.67–2.90),  $1.40 \pm 0.63$  mm (range: 0.20–2.65) and  $1.24 \pm 0.55$  mm (range: 0.19–2.31), respectively, on the mesial, distal, oral and buccal sides, respectively. The thickness of the membrane was  $<2$  mm for 11 patients (18 implants), including one smoker and two patients with membrane perforation at time of surgery (Fig. 4). The thickness of the membrane was between 2 and 3 mm with flat thickening around three implants in two patients, including one smoker (Fig. 5).

## DISCUSSION

Sinusitis of dental origin is now well-recognized; it represents 10–12% of all cases of maxillary sinusitis. Unilateral infection is the only pathognomonic sign of its dental origin. Standard periapical and panoramic radiographs show less specificity and sensitivity than CBCT for analyzing sinus abnormalities.<sup>34</sup> Odontogenic maxillary sinusitis may originate from dental infection, oroantral fistulas, and foreign bodies (root fragments, fillings, or broken instruments pushed into the sinus).<sup>22</sup>

The complications encountered with implant placement in the atrophic posterior maxilla depend on the technique used. They include: Schneiderian membrane perforation, maxillary sinusitis, bone loss, massive intrasinus bleeding, sequestrum formation, and implant migration into the sinus.<sup>19,35</sup> Over a period of 10 years, Brånemark et al<sup>36</sup> showed an absence of symptoms or signs indicating an inflammatory process in the sinuses, both in the first few weeks postoperatively and during long-term clinical follow-up. Radiographic indications of bone or mucosal reactions were also absent. In a retrospective long-term study encompassing up to 20 years, Abi Najm et al<sup>22</sup> clinically and radiographically (two-dimensional X-rays) assessed 83 implants (70 patients) penetrating the sinus with membrane perforation. They reported no sinus complications because of the successful osseointegration of the implants over 20 years.

The present study is the first to assess the condition of the sinus after 10 years, based on clinical observations or conventional radiographs,<sup>13</sup> as well as three-dimensional radiological images. It confirms that implants in contact with sinus cavity do not lead to sinus complications. Ten years after implant placement, neither clinical examinations nor CBCT images showed any signs or symptoms of sinus infection.

It has been reported in mongrel dogs that implants protruding 2 mm in the sinus with membrane perforation can be newly covered by the sinus mucosa.<sup>24-26</sup> Jung et al<sup>26</sup> showed that implants, with > 4 mm protrusion, were not covered by the membrane. Although debris accumulated on their exposed surfaces, no sinus infection was seen over the observational period of 6 months. In a human study, the same authors showed that marked implant protrusion (>4 mm) can provoke thickening of the sinus mucosa.<sup>23</sup> Tabrizi et al<sup>27</sup> evaluated 18 implants (13 patients) with sinus floor perforation 12 months after their placement. Again, no sinus infection was diagnosed but the thickening of three membranes was noted on CT images. In the present study, the sinus membrane was perforated in two patients; shorter implants were then inserted, decreasing the protrusion in the sinus. The membrane healed completely over the implants without thickening.

Sinusitis is radiographically commonly identified in the dental literature as a thickening of the sinus membrane.<sup>32</sup> According to previous studies,<sup>32</sup> a membrane thickness below a threshold value of 2 mm was considered non-pathological radiographic mucosal thickening. However, a mucosa thickness measurement >2 mm may not necessarily be the sign of sinus pathology, particularly in the absence of coexisting sinusitis symptoms. Both membrane thickening and ostium obstruction may indicate in the majority of cases only transient (seasonal) phases of mucosal inflammation and not pathology.<sup>32</sup> Most of the morphologies of thicker membrane are flat, i.e. showing a shallow thickening without well-defined outlines.<sup>31</sup> Shanbhag et al<sup>32</sup> analyzed the membrane in 199 sinuses (128 patients) using CBCT. In their study, >2 mm membrane thickening was highly prevalent (61%). Membrane thickening of >5 mm and polypoid lesions were associated with an increased risk of ostium obstruction. The additional presence of ostium obstruction may warrant a preoperative ear, nose and throat referral. This is especially indicated for

symptomatic patients and those with a history of chronic sinusitis.<sup>32</sup> Using CBCT, Lin et al<sup>37</sup> measured a mean membrane thickness of  $1.32 \pm 0.87$  mm (range 0.3–7.9 mm). Consistent with other studies,<sup>38</sup> a flat membrane was the most common morphology (46.91%).<sup>38</sup> In the present study, two minor and uneventful cases of membranes with flat thickening (measured thickness: 2–3 mm) were observed without signs of sinus infection. Many factors are known to thicken the Schneiderian membrane. The most important are the presence of periodontal diseases and smoking.<sup>39</sup> In the present study, patients with active periodontitis were not included, and no patients presented with active periodontal disease at the time of the 10-year control. Two patients were smokers. Only one showed a slight membrane thickening.

## **CONCLUSION**

This study is an evaluation of implants that had been inserted 10 years previously in atrophic posterior maxillae using osteotome sinus floor elevation (OSFE) procedure without grafting material. It is believed to be the first long-term evaluation of the sinus condition using clinical examination and three-dimensional radiological imaging. None of the patients in the study presented with sinus infection. Two sinus membranes exhibited flat thickening, but no sinus complications were observed related to the implants, irrespective of whether membrane perforation had occurred or not. The findings demonstrate that implant protrusion in the sinus has no influence on long-term sinus health. Successful implant osseointegration over 10 years can be connected to the absence of clinical and radiographic symptoms of sinusitis. In view of the low number of patients, further studies are warranted to confirm the present findings.

**DISCLOSURE:** The authors declare that there is no conflict of interest regarding the publication of this article. This work was presented in oral communication and abstract format at the 24th Annual Meeting of EAO, Stockholm, Sweden, 2015.

**APPROVAL:** The protocol of the 10-year control received approval from the Ethics Committee for Human Research of Vaud (Switzerland) under reference number CER-VD 393/12.

**ROLE/CONTRIBUTION OF CO-AUTHORS:**

**Semaan Abi Najm:** Data analysis and interpretation, critical revision of the article, submission approval, article approval.

**Nathalie Nurdin:** Study design, data collection and interpretation, article writing, article submission, article approval.

**Marc El Hage:** Data interpretation, critical revision of the article, submission approval, article approval.

**Mark Bischof:** Study concept, critical revision of the article, submission approval, article approval.

**RabahNedir:** Study concept and design, patient enrolment and surgery, data collection, critical revision of the article, submission approval, article approval.

## REFERENCES

1. Adell R, Lekholm U, Rockler B, Branemark PI. A 15-year study of osseointegrated implants in the treatment of the edentulous jaw. *Int J Oral Surg.* 1981;10:387–416.
2. Adell R, Lekholm U, Rockler B, et al. Marginal tissue reactions at osseointegrated titanium fixtures (I). A 3-year longitudinal prospective study. *Int J Oral Surg.* 1986;15:39–52.
3. Buser D, Mericske-Stern R, Bernard JP, et al. Long-term evaluation of non-submerged ITI implants. Part 1: 8-year life table analysis of a prospective multi-center study with 2359 implants. *Clin Oral Implants Res.* 1997;8:161–172.
4. Romeo E, Ghisolfi M, Rozza R, et al. Short (8-mm) dental implants in the rehabilitation of partial and complete edentulism: a 3- to 14-year longitudinal study. *Int J Prosthodont.* 2006;19:586–592.
5. Tatum OH. Maxillary and sinus implant reconstructions. *Dent Clin North Am.* 1986;30:207–229.
6. Boyne PJ, James RA. Grafting of the maxillary sinus floor with autogenous marrow and bone. *J Oral Surg.* 1980;38:613–616.
7. Summers RB. A new concept in maxillary implant surgery: the osteotome technique. *Compendium.* 1994;15:152:154–156.
8. Toffler M. The clinical and practical benefits of combining short implants with minimally invasive osteotome sinus floor elevation in the treatment of the atrophic posterior maxilla. *Pract Proced Aesthet Dent.* 2006;18:185–192.
9. Lundgren S, Andersson S, Gualini F, Sennerby L. Bone reformation with sinus membrane elevation: a new surgical technique for maxillary sinus floor augmentation. *Clin Implant Dent Relat Res.* 2004;6:165–173.
10. Nedir R, Nurdin N, Khoury P, et al. Osteotome sinus floor elevation with and without grafting material in the severely atrophic maxilla. A one-year prospective randomized controlled study. *Clin Oral Implants Res.* 2013;24:1257–1264.
11. Nedir R, Nurdin N, Khoury P, Bischof M. Short implants placed with or without grafting in atrophic sinuses: the 3-year results of a prospective randomized controlled study. *Clin Implant Dent Relat Res.* 2016;18:10–18.

12. Nedir R, Nurdin N, Abi Najm S, et al. Short implants placed with or without grafting into atrophic sinuses. The 5-year results of a prospective randomized controlled study. *Clin Oral Implants Res.* 2017;28:877–886.
13. Nedir R, Nurdin N, Vazquez L, et al. Osteotome sinus floor elevation without grafting: A 10-year prospective study. *Clin Implant Dent Relat Res.* 2016;18:609–617.
14. Hong YH, Mun SK. A case of massive maxillary sinus bleeding after dental implant. *Int J Oral Maxillofac Surg.* 2011;40:758–760.
15. Hunter WL 4th, Bradrick JP, Houser SM, et al. Maxillary sinusitis resulting from ostium plugging by dislodged bone graft: case report. *J Oral Maxillofac Surg.* 2009;67:1495–1498.
16. Lida S, Tanaka N, Kogo M, Matsuya T. Migration of a dental implant into the maxillary sinus. A case report. *Int J Oral Maxillofac Surg.* 2000;29:358–359.
17. Quiney RE, Brimble E, Hodge M. Maxillary sinusitis from dental osseointegrated implants. *J Laryngol Otol.* 1990;104:333–334.
18. Raghoobar GM, van Weissenbruch R, Vissink A. Rhino-sinusitis related to endosseous implants extending into the nasal cavity. A case report. *Int J Oral Maxillofac Surg.* 2004;33:312–314.
19. Regev E, Smith RA, Perrott DH, Pogrel MA. Maxillary sinus complications related to endosseous implants. *Int J Oral Maxillofac Implants.* 1995;10:451–461.
20. Ueda M, Kaneda T. Maxillary sinusitis caused by dental implants: report of two cases. *J Oral Maxillofac Surg.* 1992;50:285–287.
21. Brånemark PI, Adell R, Albrektsson T, et al. An experimental and clinical study of osseointegrated implants penetrating the nasal cavity and maxillary sinus. *J Oral Maxillofac Surg.* 1984;42:497–505.
22. Abi Najm S, Malis D, El Hage M, et al. Potential adverse events of endosseous dental implants penetrating the maxillary sinus: long-term clinical evaluation. *Laryngoscope.* 2013;123:2958–2961.
23. Jung JH, Choi BH, Jeong SM, et al. A retrospective study of the effects on sinus complications of exposing dental implants to the maxillary sinus cavity. *Oral Surg Oral Med Oral Pathol Oral Radiol Endod.* 2007;103:623–625.
24. [Zhong W](#), [Chen B](#), [Liang X](#), [Ma G](#). Experimental study on penetration of dental implants into the maxillary sinus in different depths. *J Appl Oral Sci.* 2013;21:560–566.

25. [Elhamruni LM](#), [Marzook HA](#), [Ahmed WM](#), [Abdul-Rahman M](#). Experimental study on penetration of dental implants into the maxillary sinus at different depths. *Oral Maxillofac Surg*. 2016;20:281–287.
26. Jung JH, Choi BH, Zhu SJ, et al. The effects of exposing dental implants to the maxillary sinus cavity on sinus complications. *Oral Surg Oral Med Oral Pathol Oral Radiol Endod*. 2006;102:602–605.
27. Tabrizi R, Amid R, TahaOzkan B, et al. Effects of exposing dental implant to the maxillary sinus cavity. *J Craniofac Surg*. 2012;23:767–769.
28. [Nedir R](#), [Bischof M](#), [Vazquez L](#), et al. Osteotome sinus floor elevation without grafting material: a 1-year prospective pilot study with ITI implants. *Clin Oral Implants Res*. 2006;17:679–686.
29. Rosenfeld RM, Andes D, Bhattacharyya N, et al. Clinical practice guideline: adult sinusitis. *Otolaryngol Head Neck Surg* 2007;137:S1–S31.
30. Soikkonen K, Ainamo A. Radiographic maxillary sinus findings in the elderly. *Oral Surg Oral Med Oral Pathol Oral Radiol Endod*. 1995;80:487–491.
31. [Schneider AC](#), [Bragger U](#), [Sendi P](#), et al. Characteristics and dimensions of the sinus membrane in patients referred for single-implant treatment in the posterior maxilla: a cone beam computed tomographic analysis. *Int J Oral Maxillofac Implants*. 2013;28:587–596.
32. [Shanbhag S](#), [Karnik P](#), [Shirke P](#), [Shanbhag V](#). Cone-beam computed tomographic analysis of sinus membrane thickness, ostium patency, and residual ridge heights in the posterior maxilla: implications for sinus floor elevation. *Clin Oral Implants Res*. 2014;25:755–760.
33. Cagici CA, Yilmazer C, Hurcan C, et al. Appropriate interslice gap for screening coronal paranasal sinus tomography for mucosal thickening. *Eur Arch Otorhinolaryngol*. 2009;266:519–525.
34. Brook I. Sinusitis. *Periodontol 2000* 2009;49:126–139.
35. Galindo-Moreno P, Padial-Molina M, Avila G, et al. Complications associated with implant migration into the maxillary sinus cavity. *Clin Oral Implants Res*. 2012;23:1152–1160.
36. Brånemark PI, Adell R, Albrektsson T, et al. An experimental and clinical study of osseointegrated implants penetrating the nasal cavity and maxillary sinus. *J Oral Maxillofac Surg*. 1984;42:497–505.
37. Lin YH, Yang YC, Wen SC, Wang HL. The influence of sinus membrane thickness upon membrane perforation during lateral window sinus augmentation. *Clin Oral Implants Res*. 2016;27:612–617.

38. Janner SF, Caversaccio MD, Dubach P, et al. Characteristics and dimensions of the Schneiderian membrane: a radiographic analysis using cone beam computed tomography in patients referred for dental implant surgery in the posterior maxilla. *Clin Oral Implants Res.* 2011;22:1446–1453.
39. [Monje A](#), [Monje-Gil F](#), [Burgueño M](#), et al. Incidence of and factors associated with sinus membrane perforation during maxillary sinus augmentation using the reamer drilling approach: A double-center case series. *Int J Periodontics Restorative Dent.* 2016;36:549–556.

## LEGENDS

**Fig. 1.**Inclusion and exclusion criteria for patient recruitment.

**Fig. 2.**Cone-beam computed tomography images. Patient #5, site 16. (A) Axial section. Two perpendicular axes were positioned at the middle of the implant. They allowed defining sagittal (blue axis) and coronal (yellow axis) sections. The yellow axis was positioned in taking into consideration the long axes of the neighboring teeth. (B) Sagittal section. Membrane thicknesses (red landmarks) were measured on the mesial (m) and distal (d) sides and at the apex (a) of the implant. (C) Coronal section. Membrane thicknesses were measured on the oral (o) and buccal (b) sides and at the apex (a) of the implants.

**Fig. 3.** Cone-beam computed tomography images. Patient #15, site 25. Sagittal section. (d) Membrane thickness on the implant distal side of 2.9 mm. Case of membrane with a flat thickening.

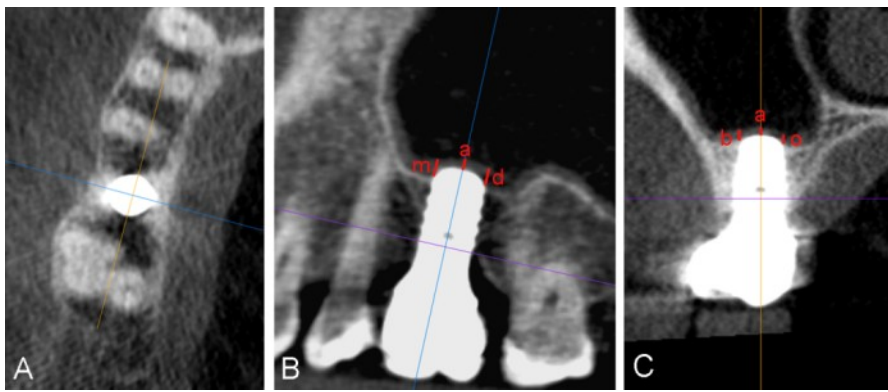
**Fig. 4.**Cone-beam computed tomography image. Patient #5, site 16. Although the Schneiderian membrane was perforated at the time of surgery, the 10-year CBCT image didn't show membrane thickening. The membrane covered completely the implant dome.

**Fig. 5.**Cone-beam computed tomography images. (A) Patient #15, site 25. (B) Patient #2, smoker, sites 14, 15 and 16. For these two patients, CBCT images showed membrane thickening. The thickness of the membranes was between 2 and 3 mm with flat thickening.

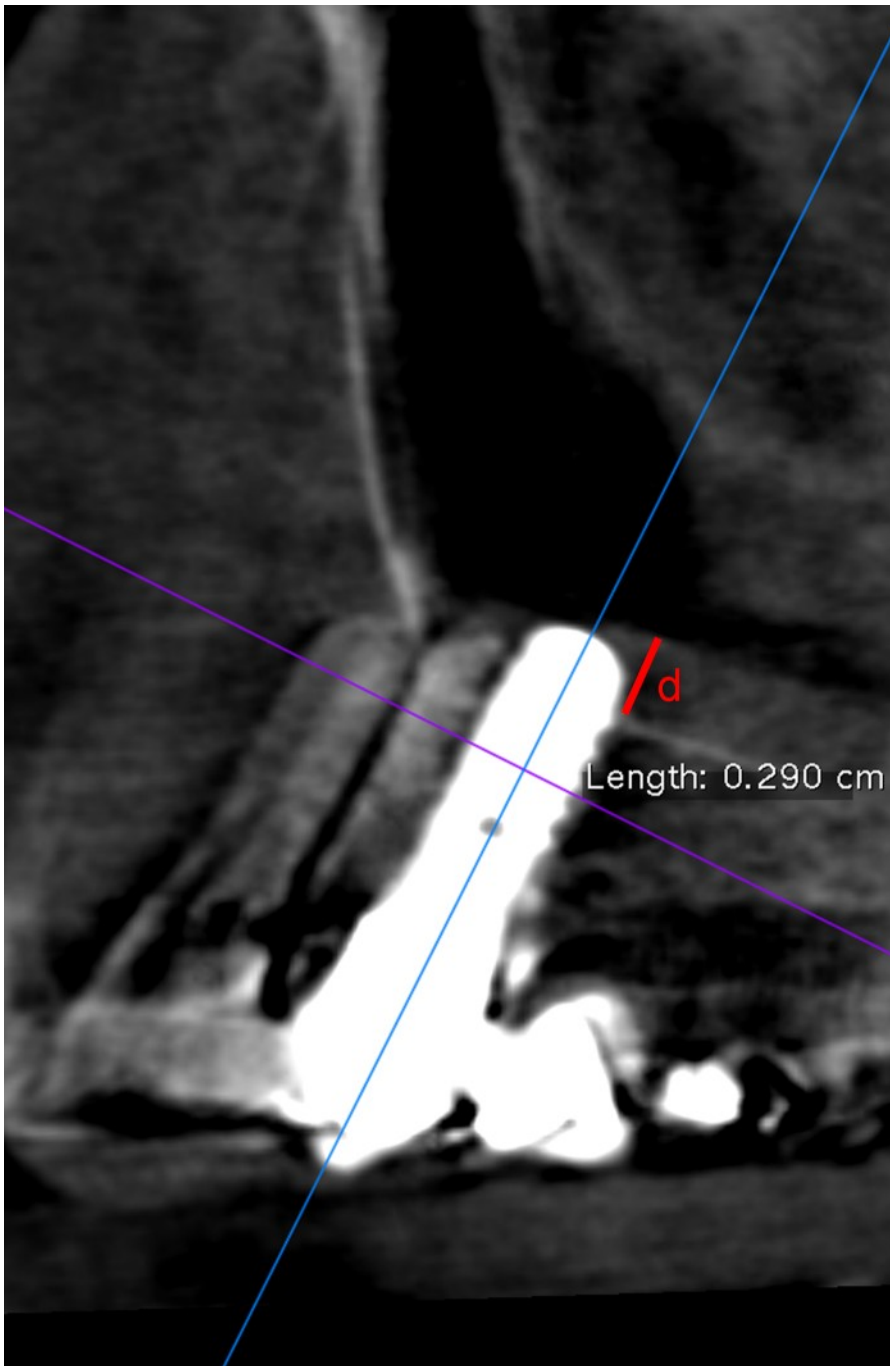
**Table 1.** List of all the implants that were analyzed using CBCT. Membrane thickness was measured at the apex and on the mesial, distal, oral and buccal sides (mm). It was not readable for six out 105 sides of the 21 analyzed implants. The highest value of apex measurements performed on sagittal and coronal sections was reported. nr indicates data non readable.

<b>Inclusion criteria</b>
<ul style="list-style-type: none"> <li>• Patients required implant treatment in the posterior maxilla (sites 14–17, and/or 24–27).</li> </ul>
<ul style="list-style-type: none"> <li>• The OSFE was performed without grafting material.</li> </ul>
<ul style="list-style-type: none"> <li>• Implants of 10-mm in length were used; shorter implants (6 and 8 mm) were inserted only in cases of sinus membrane perforation.</li> </ul>
<ul style="list-style-type: none"> <li>• The ridge bone height between the crest and sinus floor, measured on panoramic radiographs at each implant site, was <math>\leq 8</math> mm.</li> </ul>
<ul style="list-style-type: none"> <li>• More than 1 mm of bone was present on the mesial and distal sides to ensure implant stability.</li> </ul>
<ul style="list-style-type: none"> <li>• Implants penetrated at least 2 mm into the sinus on the mesial or distal implant sides.</li> </ul>
<ul style="list-style-type: none"> <li>• Patients did not wear a removable partial denture during the healing period.</li> </ul>
<ul style="list-style-type: none"> <li>• Patients attended the 10-year control and consented to cone-beam computed tomography (CBCT).</li> </ul>
<b>Exclusion criteria</b>
<ul style="list-style-type: none"> <li>• Medical history of acute or chronic sinusitis.</li> </ul>
<ul style="list-style-type: none"> <li>• Active periodontal disease, diabetes, or metabolic bone disease.</li> </ul>
<ul style="list-style-type: none"> <li>• Lack of primary implant stability.</li> </ul>

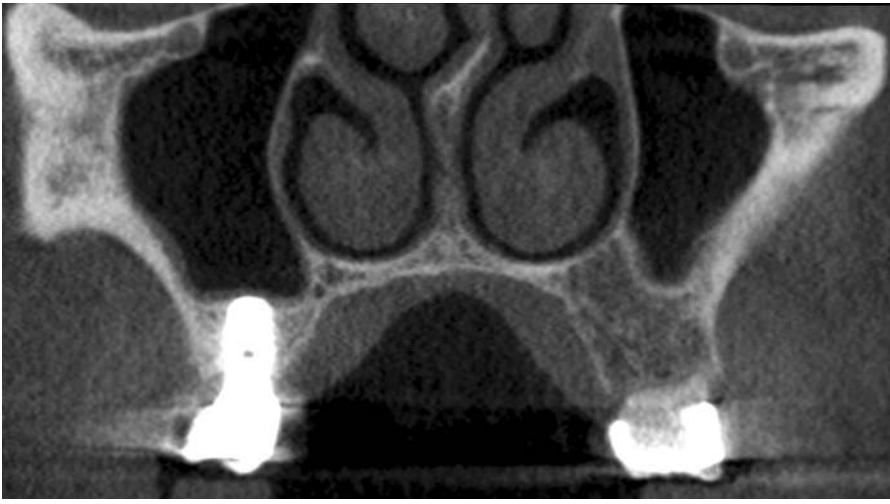
**Fig. 1.** Inclusion and exclusion criteria for patient recruitment.



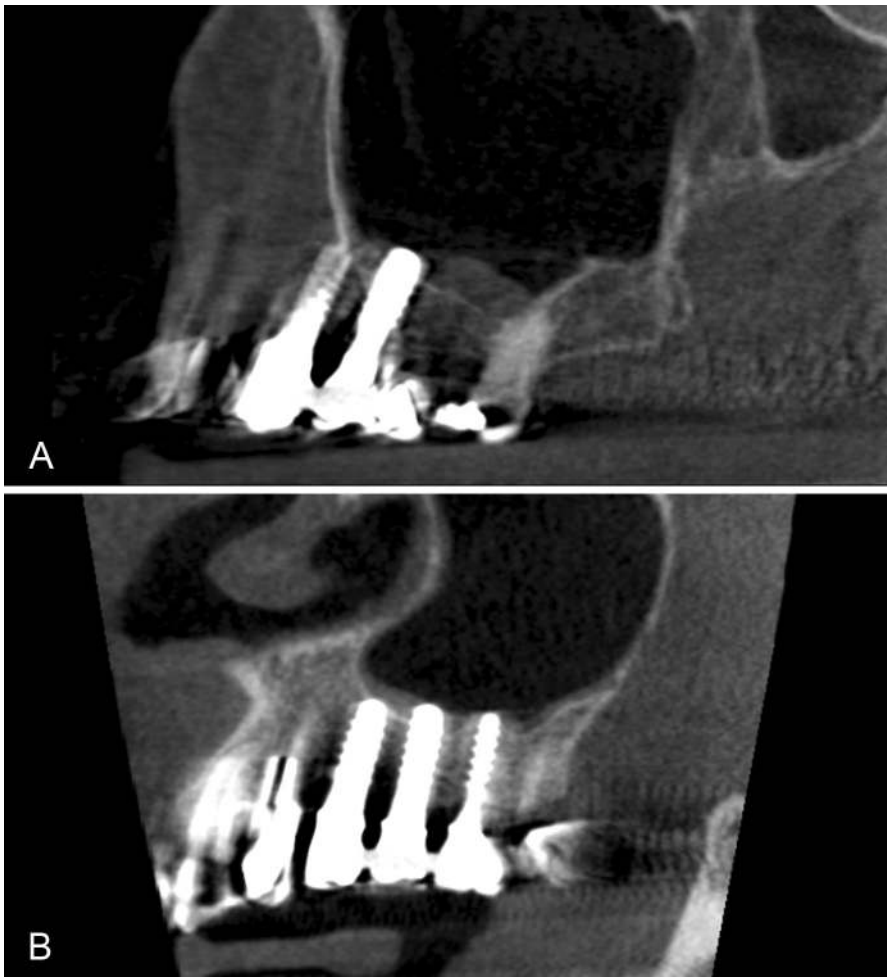
**Fig. 2.** Cone-beam computed tomography images. Patient #5, site 16. (A) Axial section. Two perpendicular axes were positioned at the middle of the implant. They allowed defining sagittal (blue axis) and coronal (yellow axis) sections. The yellow axis was positioned in taking into consideration the long axes of the neighboring teeth. (B) Sagittal section. Membrane thicknesses (red landmarks) were measured on the mesial (m) and distal (d) sides and at the apex (a) of the implant. (C) Coronal section. Membrane thicknesses were measured on the oral (o) and buccal (b) sides and at the apex (a) of the implants.



**Fig. 3.** Cone-beam computed tomography images. Patient #15, site 25. Sagittal section. (d) Membrane thickness on the implant distal side of 2.9 mm. Case of membrane with a flat thickening.



**Fig. 4.** Cone-beam computed tomography image. Patient #5, site 16. Although the Schneiderian membrane was perforated at the time of surgery, the 10-year CBCT image didn't show membrane thickening. The membrane covered completely the implant dome.



**Fig. 5.** Cone-beam computed tomography images. **(A)** Patient #15, site 25. **(B)** Patient #2, smoker, sites 14, 15 and 16. For these two patients, CBCT images showed membrane thickening. The thickness of the membranes was between 2 and 3 mm with flat thickening.

Patient number	Implant site	Apex	Mesial	Distal	Oral	Buccal
1	26	nr	0.98	1.15	1.91	0.77
2	14	0.86	1.50	1.78	0.20	0.19
	15	nr	1.23	1.20	0.87	1.56
	16	nr	0.84	0.67	1.38	1.02
3	16	nr	1.24	1.48	0.93	1.00
	17	0.55	1.08	1.46	0.62	0.46
4	16	0.29	1.03	1.45	1.49	0.83
5	16	0.82	1.44	1.48	1.31	0.90
6	25	0.29	0.99	1.57	1.25	1.58
7	15	nr	1.09	1.12	0.75	1.07
8	26	1.10	1.67	1.80	1.63	1.88
10	24	0.44	1.54	1.75	<b>2.65</b>	1.02
	25	0.31	0.54	1.27	1.45	1.59
11	25	nr	0.89	0.75	0.94	1.08
	26	0.50	1.68	1.81	1.53	1.46
13	25	0.77	1.08	1.10	0.98	1.17
	26	0.65	1.03	0.90	1.38	1.59
15	15	0.83	1.91	1.53	2.41	<b>2.11</b>
	16	1.08	1.40	1.09	1.93	1.89
	25	1.10	<b>2.00</b>	<b>2.90</b>	<b>2.57</b>	<b>2.31</b>
17	16	0.36	1.92	1.36	1.19	0.63

**Table 1.** List of all the implants that were analyzed using CBCT. Membrane thickness was measured at the apex and on the mesial, distal, oral and buccal sides (mm). It was not readable for six out 105 sides of the 21 analyzed implants. The highest value of apex measurements performed on sagittal and coronal sections was reported. nr indicates data non readable.