


# PROSTHETIC MAINTENANCE AND COMPLICATIONS OF IMPLANT-SUPPORTED REHABILITATIONS. RESULTS FROM AN 8-YEAR EXPERIENCE IN A PRIVATE PRACTICE WITH ITI IMPLANTS

**Nedir R<sup>1,2</sup>, Bischof M<sup>1,2</sup>, Beyer<sup>1</sup>, Briaux JM<sup>1</sup>, Butticaz G<sup>1</sup>, Szmukler-Moncler S<sup>2,3</sup>, Bernard JP<sup>2</sup>**

<sup>1</sup> CdR, Clinique Dentaire, rue du Collège 3, CH-1800, Vevey  
<sup>2</sup> Dpt of Oral Surgery, School of Dental Medicine, University of Geneva, CH  
<sup>3</sup> Dpt of Odontology, Galeazzi Institute, University of Milano, I



Université de Genève



## INTRODUCTION

The outcome of dental implant therapy has been extensively documented through the last 25 years. Less is known on the prosthetic complications, especially in private practice.

In a previous paper (Nedir et al. COIR, 2003), ITI implants placed in a private practice have been followed-up in a 7-year Life Table Analysis. All implants were in function for at least 1 year and the cumulative implant survival rate was 99.40 %.

The present study documents the prosthetic complications, type and frequency that have happened during 8 years of practice. Presently, all implants have been loaded for at least 2 years.

## MATERIAL & METHODS

Between 1995 and 2000, 528 implants rehabilitated 235 patients (mean 57.5 years). The mandible-maxilla implant distribution was 327/201. The posterior region received 66.5 % implants as shown

in figure 1. Figure 2 shows that implants supported single crowns (32.5 %), short-span 2 to 5-unit bridges supported by 2-3 implants (38.7 %), full-arch bridges (1.2 %) and overdentures (27.6 %). Most implants (57.6%) supported cemented prosthesis.

Implants supported fixed bridges with 1 or 2 pontics, with 1 or 2 cantilevers or were splinted together (fig 3). The recorded prosthetic complications included, major and minor problems of prosthesis and components.

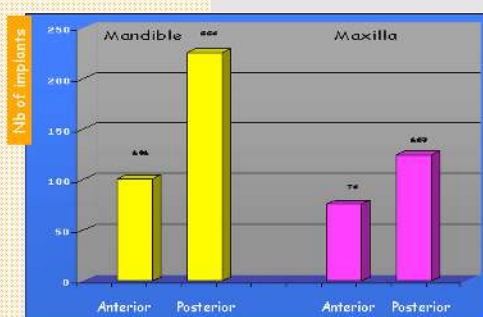


Fig 1 : Implants distribution by quadrant. Most implants rehabilitated the mandible and the posterior region.

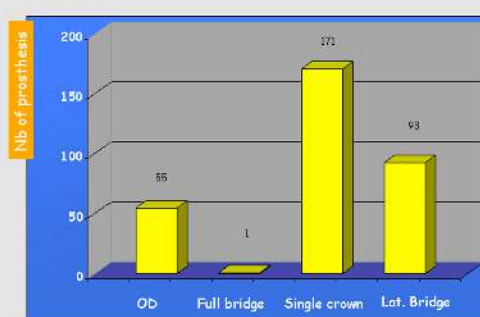

Fig 2 : Distribution of the prosthesis. Single crowns were the majority, 156 were placed in the posterior area.

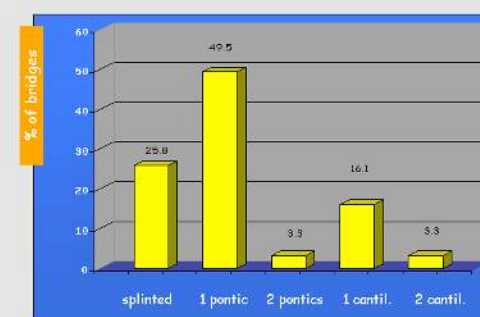


Fig 3 : Type of fixed bridges. Most bridges had 1 pontic, 25.8 % of the bridges were supported by 2 splinted implants.

## RESULTS

In the removable prosthesis group, 88 maintenance actions and 29 complications were recorded for the 55 OD/145 implants (fig 4, 6). Maintenance actions concerned the female attachment, the bar riders

and prosthesis relining. 7 fractured prostheses were repaired, another one was replaced. In the fixed rehabilitation group, 26 events were recorded for 265 prostheses and 383 implants (fig 5, 6).

Among them, 16 complications including 15 minor veneer fractures. In addition, 10 prostheses had to be replaced (3.8 %). Some of the complications are shown in figures 7-9.

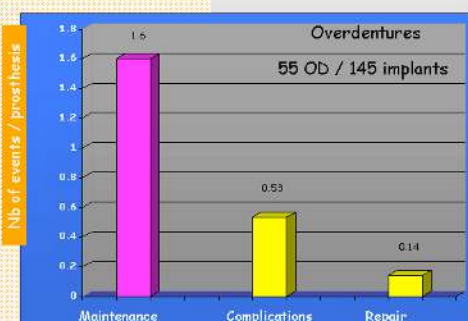


Fig 4 : Distribution of events in the OD group. The number of maintenance operations was high, 1.6/prostheses.

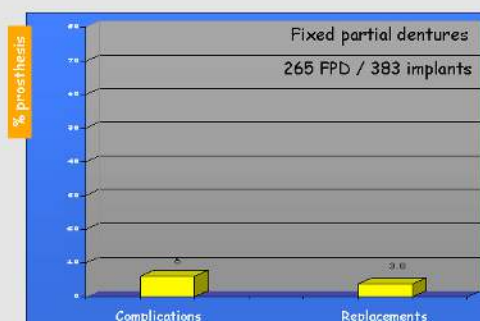


Fig 5 : Distribution of events in the fixed group. Maintenance operations number was low, 10/265 prostheses were replaced.

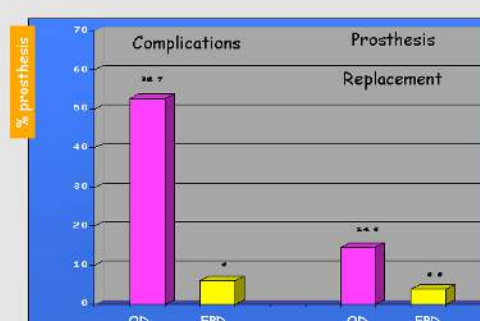


Fig 6 : OD and FPD groups comparison. More complications occurred in the OD group, replacement in the FPD was more expensive.

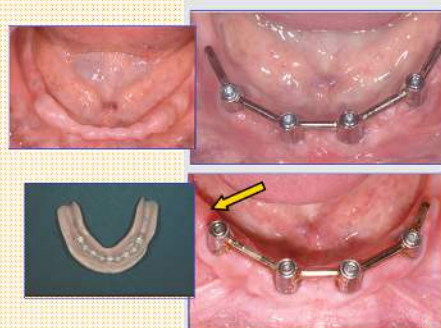

Fig 7 : OD complications. The overdenture was supported by 4 implants and 2 extensions. The right extension fractured (arrow).

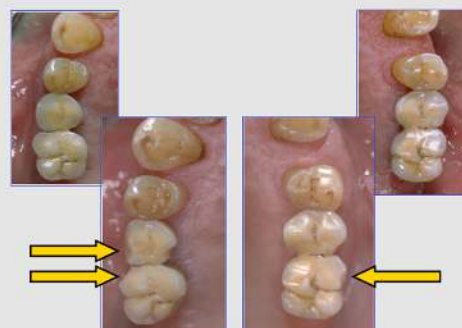

Fig 8 : Complications at a FPD. Cuspid fractures of 15, 16 and 26 (arrows) in a bruxer's mouth. Replacement was not requested on left side.

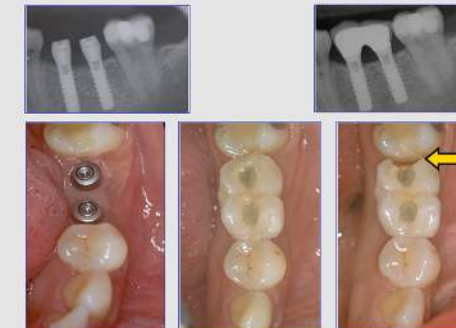

Fig 9 : Prosthesis replacement of a FPD. Major fracture of the distal part of a molar crown (arrow). The crown was replaced.

## DISCUSSION & CONCLUSION

The fixed prosthesis group had a lower complication rate and a lower replacement rate than the removable prosthesis group. In the fixed prosthesis group, 38.5 % of the events led to prosthesis

replacement and to high costs of the replaced prostheses. On the other hand, more time was spent on the removable prostheses because of an extended number of maintenance problems (1.6 event/prostheses)

and overdenture repair, prosthesis replacement was a rare event (1/55 OD). Our results are in line with other reports on ITI implants (Brägger et al., COIR 2001).