

# Oroantral fistula: a complication of late implant failure

R. NEDIR<sup>1</sup>, N. NURDIN<sup>1</sup>, M. EL HAGE<sup>2</sup>, S. ABI NAJM<sup>3</sup>, M. BISCHOF<sup>2</sup>  
(1) Ardentis Clinique Dentaire Vevey, Swiss Dental Clinics Group, Switzerland  
(2) Ardentis Clinique Dentaire Lausanne, Swiss Dental Clinics Group, Switzerland  
(3) Ardentis Clinique Dentaire Geneva, Swiss Dental Clinics Group, Switzerland

Topic: Treatment of technical and biological complications

## Abstract

**Aim:** Oroantral fistula (OAF) occurs most frequently after tooth extraction but rarely after implant placement. This report describes an OAF occurring 10 years after implant placement with sinus grafting.

**Case report:** In April 2003, a woman presented for implant placement in the left posterior maxilla. A sinus-lift with Bio-Oss® (Geistlich AG) was performed with the simultaneous placement of implants (≤10 mm; Straumann AG). The implants were functionally loaded with a screw-retained fixed partial denture (FPD). In 2013, crestal bone loss around implant 25 was observed and CBCT revealed opacity of the left sinus. At bridge unscrewing, implant 25 appeared mobile and was removed, revealing thus an OAF. The sinus was rinsed through the fistula and the FPD was re-screwed. The procedure was repeated until disappearance of the infection and the AOF was then surgically closed. In 2015, control showed that the OAF remains successfully closed with total healing of the sinus.

**Results:** The bone loss was first diagnosed as peri-implantitis but not as loss of osseointegration. Although CBCT showed unilateral sinusitis, only the clinical control has revealed the OAF. At the end of the treatment, the patient retained the same FPD alongside a healthy condition.

**Conclusions:** The loss of posterior maxillary implant osseointegration may cause OAF.

## Background and Aim

Oroantral fistula (OAF) is a communication between the oral cavity and the maxillary sinus. It occurs most frequently as a result of maxillary tooth extraction (Norman 1977) and following removal of maxillary cysts, benign or malignant tumors or complex facial traumas. It rarely occurs after long-term implant placement.

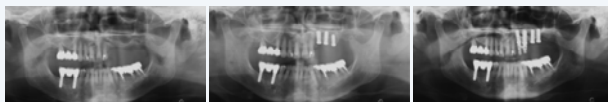Patients with OAF are prone to sinus infections due to the persistent communication between the maxillary sinus and the oral cavity. Complications may include sinusitis and, in rare cases, pansinusitis and central nervous system infections.

This report describes a case of uncommon OAF occurring 10 years after the placement of implants which were inserted simultaneously with sinus grafting using lateral sinus floor elevation technique. It shows the complexity of the diagnosis and the step-by-step management.

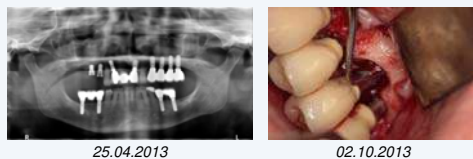## Case Report

In April 2003, a 62-year-old Caucasian woman presented for implant placement in sites 23, 24 and 25 (residual bone height: 12, 5, and 2 mm, respectively).

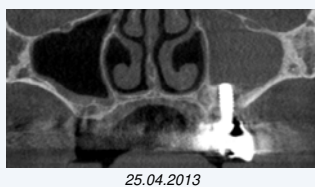A lateral sinus floor augmentation with Bio-Oss® (Geistlich AG) was performed with the simultaneous placement of three standard endosseous implants (≤10 mm; Straumann AG; sites 23-25). In July 2003, implant 25 was removed because of mobility. In November, two implants (10 mm) were placed in sites 25 and 26, without further augmentation. Four months later, the implants were functionally loaded with a screw-retained fixed partial denture (FPD).



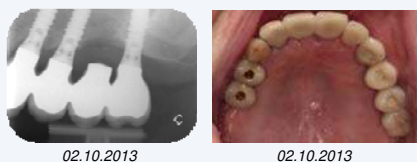
In 2013, a peri-apical radiograph showed crestal bone loss around implant 25. A flap confirmed the bone loss up to the implant apex.



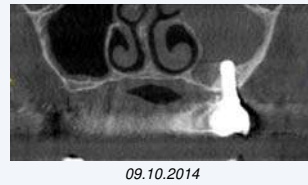The patient did not complain about pain or sinus discharge but CBCT showed an opaque left sinus:



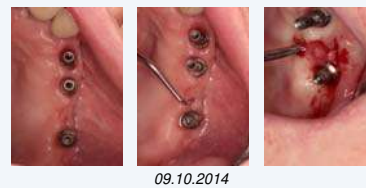The FPD was unscrewed revealing the mobility of implant 25 which was then removed. An OAF at the site 25 was clinically identified. The FPD was re-screwed and antibiotics were administered to the patient.



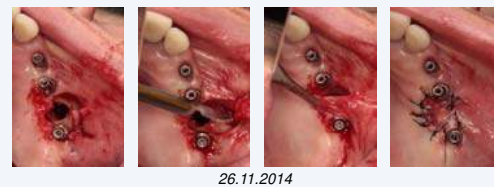
In 2014, one year later, the sinusitis was still observed on CBCT:



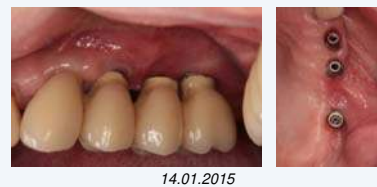The FPD was unscrewed; the sinus was rinsed through the fistula with NaCl and H<sub>2</sub>O<sub>2</sub> solutions and the FPD was re-screwed. The procedure was repeated until the sinus showed no more presence of pus.



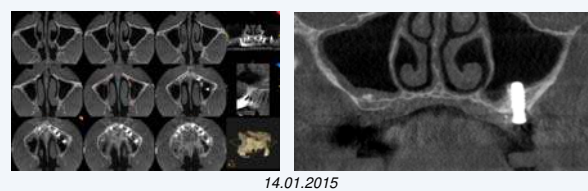
The AOF was closed with a buccal advanced flap. The healing was uneventful.



In 2015, the FPD was unscrewed. Clinical control showed that the OAF remains successfully closed.



CBCT images confirmed the total healing of the sinus:



## Discussion

The bone loss around the implant was detected during routine implant control. It was first diagnosed as peri-implantitis but not as a loss of implant osseointegration. The CBCT has revealed unilateral sinusitis but did not detect the OAF. The implant failure was difficult to diagnose because the four implants were splinted on one FPD. The unscrewing of the FPD was needed to further identify implant mobility and OAF. The case management has included the implant removal and OAF surgical closure. At the end of the treatment, the patient retained the same FPD on a healthy situation of the oral cavity and sinus.

## Conclusion

**The loss of posterior maxillary implant osseointegration may cause OAF and thus sinusitis. This report reflects the importance of the sinus check during a routine implant control. Unilateral radiopaque maxillary sinus images may indicate implant failure and related OAF.**

## References

Norman JE. Oro-antral fistula. *Aust Dent J* 1977;22:248-258.