

Osteotome sinus floor elevation without grafting material. A 1-year prospective pilot study with ITI implants.

Nedir Rabah ^{1,2}, Bischof Mark ^{1,2}, Vazquez Lydia ², Szmukler-Moncler Serge ^{1,2},
Bernard Jean-Pierre ²

¹ Swiss Dental Clinics Group, CdR Clinique de Soins Dentaires, Rue du Collège 3,
1800 Vevey, Switzerland

² Department of Stomatology and Oral Surgery, School of Dental Medicine
University of Geneva, Rue Barthélemy-Menn 19, 1205 Geneva, Switzerland

Running title:

Osteotome sinus elevation without grafting material

Key words:

Sinus osteotome, osteotome, sinus lift, dental implants, ITI implants, grafting
material, posterior maxilla

Correspondence addressed to:

Dr Nedir Rabah, Swiss Dental Clinics Group, CdR, Clinique de Soins Dentaires
Rue du Collège 3, 1800 Vevey, Switzerland

Tel. / Fax : + 41 21 923 52 31 / 922 22 98

E-mail : rabah.nedir@swissdentalclinics.ch

Nedir R, Bischof M, Vazquez L, Szmukler-Moncler S, Bernard JP

Osteotome sinus floor elevation without grafting material. A 1-year prospective pilot study with ITI implants

Clin Oral Impl Res

Abstract

Objective: The aim of the present pilot study was to evaluate: 1) the predictability of an osteotome sinus floor elevation procedure with ITI-SLA implants without placing a bone grafting material, 2) the possibility to gain bone height without filling the created space with a bone grafting material.

Material and Methods: Seventeen patients received 25 implants protruding in the sinus. Most implants (21/25) were 10 mm long, 8 were inserted in type 2 bone, 12 in type 3 and 5 in type 4 bone. At implant placement, the mean residual bone height under the maxillary sinus was 5.4 ± 2.3 mm; it was 5.7 ± 2.6 mm on the mesial side and 5.1 ± 1.9 mm on the distal side. Nineteen implants had less than 6 mm of bone on at least one side and 6 implants had less than 6 mm on both sides. A healing period of 3-4 months was allowed before abutment tightening at 35 Ncm. The percentage of stable implants at abutment tightening and at the 1-year control was calculated. The endo-sinus bone gain and the crestal bone loss at the mesial and distal sides were measured.

Results: Abutments were tightened after 3.1 ± 0.4 months. All implants but one (96.0 %) resisted the applied 35 Ncm torque. At the 1-year control, all implants were clinically stable and supported the definitive prosthesis. All showed endo-sinus bone gain; the mean gain was 2.5 ± 1.2 mm. The mean crestal bone loss was 1.2 ± 0.7 mm. Endo-sinus bone gain and residual bone height showed a strong negative

correlation ($r = -0.78$ on mesial and -0.80 on distal side). Good correlation ($r = 0.73$) was found between implant penetration in the sinus and endo-sinus bone gain.

Conclusion: Elevation of the sinus membrane alone without addition of bone grafting material can lead to bone formation beyond the original limits of the sinus floor. Despite a limited residual bone height at implant placement, a healing period of 3 months was sufficient to resist a torque of 35 Ncm and to lead to a predictable implant function at the 1-year control.

Introduction

In the posterior maxilla, the presence of the maxillary sinus often limits the available bone height for implant placement. For short machined-surface implants (7-10 mm), lower success rates have been reported (Esposito et al. 1998; Weng et al. 2003); however, this clinical observation was not confirmed for implants with a roughened surface (Testori et al. 2001, 2002; Nedir et al. 2004). Nevertheless, beneath a certain residual bone height, that is still open to discussion, sinus elevation to increase the initial bone height is indicated, before or at implant placement (Jensen et al. 1998). Elevation of the sinus membrane can be performed either through a lateral window (Boyne & James 1980; Chavanaz 1996; Jensen et al. 1998; Hatano et al. 2004), or via a crestal access (Tatum 1986; Summers 1994a, 1994b; Rosen et al. 1999; Cavicchia et al. 2001; Brägger et al. 2004). In the lateral sinus lift procedure, a window is created through the buccal plate of the maxilla; the membrane is elevated and a bone grafting material is placed in the created space. This bone augmentation procedure is considered to be invasive, time consuming and expensive (Jensen et al. 1998); therefore, every effort to reduce its indication span should be encouraged.

The osteotome sinus floor elevation (OSFE) procedure is less invasive; access to the sinus membrane is achieved through a crestal approach with sinus-osteotomes. The OSFE procedure involves drilling or trephining the residual bone up to the last millimeter (Summers 1994a, 1994b; Fugazzotto 2002). Classically, a bone grafting material is introduced in the osteotomy site with the osteotomes, the sinus floor is broken by light malleting and the membrane can be delicately elevated without perforation. Membrane elevation is achieved by placing a bone grafting material with

apical condensation. This results in a tented grafted area that may extend up to 6-8 millimeters in the sinus cavity (Reiser et al. 2001).

For some authors (Jensen et al. 1998; Schwarz-Arad & Dolev 2000; Toffler 2004), augmentation procedures are required when the residual bone height (RBH) left beneath the sinus cavity is less than 8-10 mm. For others, a bone height of 6 mm is still compatible with a standard implant placement procedure (Nedir et al. 2004). It is nevertheless accepted that the augmentation procedure may vary according to the RBH. The consensus conference held in 1996 on sinus lifting (Jensen et al. 1998) made recommendations on the surgical approach as a function of the RBH. When the RBH belongs to class A (RBH \geq 10 mm) a classical implant procedure is performed; when the RBH is of class B (RBH = 7-9 mm), the osteotome technique should be applied in combination with immediate implant placement. When the RBH is of class C (RBH = 4-6 mm), a lateral approach involving a grafting material with immediate or delayed implants is advocated. When the residual bone height belongs to class D (RBH = 1-3 mm), a lateral approach involving bone grafting material and delayed implant placement is recommended.

For sinus augmentation procedures, the grafting material that is introduced in the sinus can be either autologous bone gained intra-orally (Raghoobar et al. 2001; Nkenke et al. 2002) or harvested extra-orally (Reinert et al. 2003; Timmenga et al. 2003). It can be a material of human, animal (Piattelli et al. 1999; Berengo et al. 2004) or synthetic origin (Ozyuvaci et al. 2003; Zerbo et al. 2004) or a mixture of 2 of the above (Tidwell et al. 1992; Froum et al. 1998; Hatano et al. 2004). The created space is usually left to heal for at least 6-9 months, to allow bone formation (Jensen

et al. 1998). When primary stability is reached, simultaneous bone grafting and implant placement are highly predictable (Zitzmann & Schärer 1998; Rosen et al. 1999; Cavicchia et al. 2001; Brägger et al. 2004; Toffler 2004). With time, the grafted area transforms into bone (Brägger et al. 2004; John & Wentz 2004); radiographic documentation shows that the previous boundary of the sinus disappears and results into formation of a new floor that includes the grafted area (Brägger et al. 2004).

Recently, the relevance of placing a grafting material in sinus elevation procedures has been questioned (Bruschi et al. 1998; Haas et al. 1998; Lundgren et al. 2003, 2004; Winter et al. 2002, 2003; Leblebicioglu et al. 2005). It has been claimed that, according to the principles of guided bone regeneration, membrane elevation with space maintenance and blood clot formation might be sufficient to obtain a neo-formation of bone in this newly created space (Winter et al. 2003; Lundgren et al. 2004). Lundgren et al. (2004) treated 10 patients that presented an average RBH of 7 mm. They placed 19 implants protruding in the sinus through a direct vestibular approach; this involved elevation of the sinus membrane and suturing it to the sinus wall, without introduction of a grafting material. After 6 months of healing in the submerged way, abutments were tightened and the prosthetic steps were undertaken. All implants achieved osseointegration and were stable after 1 year of loading. The authors reported that all implants gained endo-sinus bone; unfortunately, no measurement of bone gain was provided.

The present protocol, conducted with ITI-SLA one-stage implants, evaluated the predictability of an OSFE procedure without the use of a grafting material. A standard healing period of 3-4 months was allowed before abutments were tightened at 35

Ncm and thereafter rehabilitated. We report here the implant survival rate with this procedure at the 1-year control, the gained endo-sinus bone and the crestal bone loss.

Material and Methods

Inclusion criteria

To enter this treatment, the inclusion criteria were:

- 1) patients had to require implant treatment in the posterior maxilla,
- 2) an OFSE procedure was performed without placing a grafting material,
- 3) 10 mm long implants were placed, shorter (6-8 mm) ones only in case of membrane perforation.
- 4) bone height between the crest and the sinus floor was ≤ 8 mm on at least one implant side, either mesial or distal,
- 5) at least 1 mm of bone was required on each side for implant stability,
- 6) implants penetrated at least 2 mm in the sinus on at least one side,
- 7) implant primary stability was obtained,
- 8) wearing a removable partial denture during the healing period was not permitted.

Surgical and prosthetic procedures

Between April and December 2003, 17 consecutive patients were included in the study after bone height measurement by the means of periapical radiographs. Patients were 14 females (82.3 %) and 3 males (17.7 %) with a mean age of 54.2 ± 9.6 years, varying from 38 to 69 years; they were treated with 25 implants fulfilling the inclusion criteria. Implants were inserted in 16 molar and 9 premolar sites under

clean but not sterile conditions as defined by Scharf & Tarnow (1993).

All surgical procedures were performed under antibiotic prophylaxis beginning the day before surgery (Amoxibasan, Schönenberger Pharma, Schönenwerd, CH; 750 mg, 3x/d during 6 days or Dalacin C, Pfizer, Zürich, CH; 300 mg, 3x/d during 5 days, in case of penicillin allergy). A mid-crestal incision was used for flap elevation, but no vertical or periosteal release incision was performed. To get access to the sinus floor, cortical bone perforation was performed with 3 round burs of increasing diameters from Ø 1.4 to 3.1 mm. In type 2 bone, drilling up to 1 mm away from the floor was continued with the Ø 2.1, 2.8 and 3.5 mm drills until final preparation. In type 3 and 4 bone, the ITI expansion-osteotomes were used instead of the drills. In all cases, independently of bone density, the Ø 2.8 mm ITI sinus-osteotome was used to push axially the sinus floor without contacting the walls of the osteotomy. The sinus floor was then broken by light malleting, it was carefully pushed into the sinus cavity over 3 mm, elevating the Schneiderian membrane. The osteotomy was then enlarged with the Ø 3.5 mm ITI sinus-osteotome and integrity of the membrane was controlled with an undersized ITI depth gauge of Ø 2.1 mm. Implants were placed in the prepared osteotomy site without tapping; this created a space delimited by the lifted Schneiderian membrane that was maintained by the implant apex. At seating, all implants achieved primary stability. Implant stabilization was achieved by the threads (7 implants) or was obtained by placing the implant deeper, resting against the flared neck (18 implants). The flap was sutured around the implant neck (non-submerged) and the area was maintained prosthesis-free over the whole healing period.

Most implants (21, 84.0 %) were 10 mm long, 3 (12.0 %) implants were 8 mm and 1

(4.0 %) implant was 6 mm. The 6 and 8 mm implants were placed when the Schneiderian membrane was perforated. 20 (80.0 %) implants were standard Ø 4.1 mm implants and 5 (20.0 %) were Ø 4.8 mm implants. During surgery, bone quality at implant sites was categorized according to Lekholm & Zarb (1985). No type I bone quality was identified, 8 (32.0 %) implants were inserted in type 2 bone, 12 (48.0 %) in type 3 bone and 5 (20.0 %) in type 4 bone.

The RBH was measured after implant placement on the radiographs on both implant sides. Average was 5.4 ± 2.3 mm; on the mesial side it was 5.7 ± 2.6 mm and 5.1 ± 1.9 mm on the distal side. The difference in bone height between the mesial and the distal sides varied substantially, up to 6 mm as shown in table 1. Table 2 details the RBH at implant sides; bone height was < 4 mm on both sides for 5 implants, 6 implants had less than 6 mm of bone on both sides. Implants that had less than 4, 6 and 9 mm of bone on one side at least have also been detailed in table 2.

After a 3 to 4-month healing period, implants were radiographed and clinical stability was assessed. When implants were stable, abutments were tightened with a 35 Ncm torque. In case of implant rotation, an additional 6 weeks of healing was allowed. When the implant resisted the applied torque, the classical prosthetic steps were conducted and porcelain fused to gold prosthesis (4 single crowns and 13 fixed partial dentures of 2-3 units) were prepared and cemented within 2 weeks.

Radiographic analysis

The aim of the radiographic analysis was to determine on consecutive radiographs, 1) the bone anchoring height immediately after implant placement, 2) the change of

endo-sinus bone level, 3) the change of the crestal peri-implant bone level. Periapical radiographs were taken with the long-cone technique immediately after implant placement, after 3 months, 6 months and 1 year. The radiographs were scanned in a digital format by a flatbed scanner (Epson Expression 1680 Pro, Wädenswil, Switzerland) at a resolution of 600 dpi. They were analyzed by a computerized measuring technique with an image analysis software (Digora, Soredex, Helsinki, Finland) that measures the distance between two points. Internal calibration was performed for each radiograph on 3 inter-thread distances (3.75 mm) given that the tips of 2 consecutive threads are separated by 1.25 mm. Precision of the measuring system is 0.01 mm. In order to improve the image analysis, image enhancement operations including sharpening, brightness, contrast and gamma adjustments were performed when necessary. Radiographic analysis and measurements were performed by an investigator not involved in the surgical procedure (VL).

The RBH was measured at the mesial and distal implant sides on the radiographs taken immediately after implant placement. It was determined by measuring the vertical distance between the most apical bone level contacting the implant and the alveolar crest level on each side (A in fig. 1).

The endo-sinus bone height change was measured on both sides of the implant in the following way: a line, parallel to implant axis, was drawn from the most coronal implant thread to the most apical visible implant-bone contact (B in fig. 1). This distance was consecutively measured post-operatively and at the 1-year control. Increase of the distance between the coronal reference point and the most apical bone contact at the 1-year control indicated endo-sinus bone gain.

Implant length protruding in the sinus was also measured on both sides, post-operatively and at the 1-year control. It was measured in the following way: a line, perpendicular to implant axis was drawn at the implant dome; the vertical distance between this line and the first most apical implant-bone contact was measured (C in fig. 1). Decrease of this distance at the 1-year control indicated a decrease of the protruding length.

The change at the crestal bone level was determined on the mesial and distal implant sides; the distance, parallel to the implant axis, between the most apical implant thread and the most coronal bone-implant contact was measured (D on fig.1). Decrease of this vertical distance between the reference point and the most coronal bone-implant contact on consecutive radiographs indicated a crestal bone loss (CBL). Increase of this distance indicated a crestal bone gain.

Survival criteria

The survival criteria proposed by Buser et al. (1997) and Cochran et al. (2002) were followed at abutment placement and at the 1-year control. They included: 1) absence of clinically detectable implant mobility, 2) absence of pain or any subjective sensation, 3) absence of recurrent peri-implant infection, 4) absence of continuous radiolucency around the implant.

Statistical analysis

Two hypotheses were set forth: 1) Implants should resist abutment tightening at 35 Ncm without rotation, when performed after a standard time of 3-4 months of healing, 2) implants placed with the OSFE procedure without bone grafting material in the sinus should gain bone at the 1 year control.

The survival rate at abutment tightening and at the 1-year control was calculated. Descriptive statistics, mean and standard deviation, were used to assess the endo-sinus and the crestal bone changes on the mesial and distal implant sides at the 1-year control. The Pearson linear correlation coefficient between 2 independent parameters was calculated for the following variables: RBH, protruding implant length, change of the endo-sinus bone level and change of the crestal bone level.

Results

Survival implant follow-up

Membrane perforation was recorded at 4 implant sites; this led to the placement of implants < 10 mm. After surgery, nasal bleeding was recorded for 1 patient; 2 patients had sensation of blocked-up nose that abated within a few days. Except the above episodes, healing was uneventful. The mean healing time for abutment tightening was 3.1 ± 0.4 months (2.8-4.1 months), by this time all implants were clinically stable. Only one implant rotated after a healing period of 3.5 months. It was a \varnothing 4.1 x 10 mm implant placed in type 4 bone with RBH of 3.0 and 4.2 mm on the mesial and distal sides. 96.0 % of the implants resisted a torque of 35 Ncm after 3-4 months of healing; this confirmed the first hypothesis of the protocol. After 6 additional weeks of healing, the rotated implant resisted abutment tightening and was then rehabilitated. At the 1-year control, all implants were clinically stable and the definitive prostheses were in function.

Radiographic analysis

Measurements of the changes of the endo-sinus level on the mesial and distal sides

showed that all implants gained endo-sinus bone. The second hypothesis of the study was therefore confirmed. The mean endo-sinus gain was 2.5 ± 1.2 mm, whereas at the mesial side it was 2.4 ± 1.3 mm and 2.6 ± 0.9 mm at the distal side. The lowest bone gain was 0.7 and 1.1 mm on the mesial and distal sides, respectively. The highest gain was 5.6 and 4.7 mm on the mesial and distal side, respectively. Distribution of bone gain is detailed in table 3; 31 (62.0 %) sides out of 50 gained 2.0 mm and more.

Post-operatively, implants protruded into the sinus for an average of 4.6 ± 2.1 and 5.2 ± 1.4 mm on the mesial and distal sides, respectively. At the 1-year control, the protruding length was reduced to 2.0 ± 1.1 and 2.3 ± 1.0 mm on the mesial and distal sides respectively.

The mean CBL was 1.2 ± 0.7 mm, whereas at the mesial and the distal sides it was 1.4 ± 0.7 and 1.1 ± 0.6 mm, respectively. The highest and lowest CBL at the mesial side were 3.1 and 0.3 mm, these were 2.9 and 0.4 mm at the distal sides. The distribution and frequency of bone loss are given in table 4; 30 (60.0 %) sides out of 50 displayed a CBL > 1.0 mm, 7 (14.0 %) sides had a CBL > 2 mm.

A strong negative correlation between RBH and endo-sinus bone gain was found on the mesial ($r = - 0.78$) and the distal ($r = - 0.80$) side, i.e. lower residual bone heights showed higher endo-sinus gains. A good correlation ($r = 0.73$) was found between implant penetration in the sinus and endo-sinus bone gain. The correlation between RBH and crestal bone loss was very weak ($r = 0.13$).

Discussion

Although more difficult and challenging, this pilot treatment procedure showed that it was possible to achieve implant primary stability even when the available bone height was limited down to 3-4 mm. Expansion-osteotomes were used instead of drills, to avoid ovalization of the osteotomy site and condense the surrounding bone. Implants were often placed deeper with the flared neck resting against the crestal bone, this contributed to the achievement of stability.

Perforation of the membrane was observed in 4 (16 %) cases because of inadequate evaluation of the drilling length; it happened while using the Ø 2.1 mm drill. It is possible, however, that perforations of class I (≤ 2 mm) according to Reiser et al. (2001) might not have been noticed. In a study on cadavers, Reiser et al. (2001) found that OSFE of 4-5 mm up to 6-8 mm can be achieved with a membrane perforation rate of 24 % (6/25). The tenting effect could even be maintained following perforation since 50 % of their perforations did not lead to membrane collapse. Interestingly, the present perforation cases did not lead to any healing perturbations, only mild nasal bleeding was recorded for 1 patient.

The OSFE procedure is less invasive than sinus lifting with a lateral approach. It increases patient acceptance because surgical treatment can be performed in one session, instead of two or three for the sinus lifting procedure. In contrast to other sinus elevation procedures that advocate submerged (Lundgren et al. 2003, 2004; Berengo et al. 2004) or semi-submerged (Brägger et al. 2004) implants, the present study implemented the non-submerged technique and documents that it is predictable and uneventful.

Healing times of 6-9 months before implant placement are usually recommended for sinus elevation in combination with grafting material (Jensen et al. 1998); they are followed by an additional 3-6 months of implant healing time. In our study, the healing time before abutment tightening at 35 Ncm was 3.1 months in average; only one implant did not resist the applied torque. This 10 mm long implant was placed in type 4 bone with 3.0 and 4.2 mm of bone on each side, while the neighbor implants placed in the same bone quality had more bone for anchorage. The healing time presently allowed is shorter than the 6 months advocated by Lundgren et al (2004) for TiUnite implants used in a direct sinus elevation procedure without grafting material. It is also shorter than the 6 months healing time allotted by Brägger et al. (2004) for an OSFE procedure with bone grafting material. It is possible that a longer healing time is required for integration of the grafted material. However, it is also possible that the 6-month healing period is an empirically set conservative measure that derives from previous recommendations given by the users of machined-surface implants (Adell et al. 1981; Bahat 1993, 2000). For textured surface implants, shorter healing periods have been documented in the posterior maxilla (Cochran et al. 2002; Testori et al. 2002). Yet, SLA implants placed in the posterior area showed a rotation rate of 5.9 % when the healing time was shortened to 6 weeks (Roccuzzo et al. 2001). Our study demonstrated that 3 months are sufficient for SLA implants to resist a 35 Ncm torque even when the RBH is limited. However, it is still unknown if it was due to the original bone volume or also to the additional gained bone.

For the OSFE procedure with bone grafting material and various types of implants, Toffler (2004) reported a failure rate of 13.0 % and 5.3 % respectively for machined

and acid-etched implants. However, he observed that the most significant contributing failure parameter was not implants surface (i.e. the machined one) but the RBH at implant placement. Implants with a RBH ≤ 4 mm presented a failure rate of 26.7 %, significantly higher than the 5.1-5.5 % failure rate observed when the RBH was 5-6 mm and > 7 mm, respectively. Noteworthy, the RBH is usually determined before implant placement (Bragger et al. 2004; Toffler 2004), whereas in the present study the RBH was measured after implant placement on the mesial and distal sides of each implant. The difference in RBH between the mesial and the distal side of each implant was > 2 mm for 40 % of the implants and 1-2 mm for another 40 % of implants. These substantial differences between sides reveal the importance of precise reporting of the available bone on each side, instead of a RBH determined at a single spot during the planning step. Precise reporting is especially critical in studies addressing the issue of implant placement under the sinus in reduced RBH, because each extra or missing millimeter of bone may significantly contribute toward higher predictability or higher failure and therefore bias the reported clinical result. On the other hand, these precise mesial and distal bone heights are unable to account for the real picture of the supporting bone because the cortical vestibular or palatal plates may also provide an additional bone support that cannot be detected on a 2D radiograph. Nevertheless, in order to convey the most precise bone situation at the implant site readable on a 2D radiograph, it is suggested to provide systematically the effective RBH on both mesial and distal implants sides, i.e. determined after implant placement.

According to the consensus conference held on sinus augmentation (Jenssen et al. 1998), when the RBH is 4-6 mm, sinus elevation with a lateral approach is

recommended. If this recommendation would have been strictly followed for both implant sides, 11 (44.0 %) implants would not have benefited from a shorter, easier and more affordable treatment procedure. Enforcement of the aforementioned recommendation to one implant side, would have discarded 21 (84.0 %) implants from the procedure.

In the present treatment without grafting material, no SLA implant failed either during the healing period or within the first year, even when implants were placed in a RBH < 6 mm on both sides. Implant stability was presently better achieved by deepening the implants until resting the flared neck against the crest. This procedure was performed for 18 (72 %) implants to improve primary stability. In this case, an increased CBL is expected because bone remodels up to the rough-smooth boundary (Hämmerle et al. 1996; Hartman et al. 2004). Indeed, Brägger et al. (2004) reported a crestal bone loss of 1.9 and 1.4 mm after 1 year on the mesial and distal sides, respectively. These CBL values were higher than data reported elsewhere by the same authors for other indications (Brägger et al. 1998). Our present findings are in line with that study because the present mean CBL after 1 year was 1.4 and 1.1 mm on the mesial and distal sides, respectively. The latter was higher than the CBL previously reported, after 2 years, for 102 wide neck ITI implants where the mean CBL was 0.7 and 0.8 mm on the mesial and the distal sides, respectively (Bischof et al. 2006). Weber et al. (2000) also found a limited CBL of 0.6 mm after 1 year for 112 ITI implants placed under standard conditions.

Deeper implant placement during an OSFE procedure contrasts with the purpose of gaining endo-sinus bone to ensure a better anchorage, because it leads to an

increased crestal bone loss. Our data showed that the mean endo-sinus bone gain was 2.4-2.6 mm, while the mean CBL was 1.1-1.4 mm, in part due to implant deepening. This still resulted into an average net bone gain of 1.3-1.2 mm that participated to implant stability, as evidenced at the 1-year control. Noteworthy, CBL might also be attributed to overloading (Isidor 1996), a feature that might have occurred more often due to a limited RBH. However, the correlation between limited RBH and CBL was low ($r = 0.13$) and could not be assessed.

In the present procedure without bone grafting material and after 1 year, all implants gained endo-sinus bone. Post-operatively, implants were protruding in the sinus for an average of 4.6 mm and 5.2 mm on the mesial and distal sides, respectively. The mean endo-sinus bone gain was 2.5 mm, despite the fact that implant extremity was not surrounded by bone. Bone gain was often accompanied by formation of new densification of the sinus floor. After 3 and 6 months, the demarcation between the old and new limit of the sinus floor was still indistinct at 53.8 % of the sides but changes in densification were noticed from 3 to 6 months. At 1 year, the outline of a clear demarcation of the new sinus limit associated with bone densification could be detected at 63.7 % of the sides. This means that elevation of the sinus membrane alone was sufficient to induce formation of bone beyond the original skeletal contour of the sinus. Thus, the new created space delimited by elevation of the Schneiderian membrane and supported by the implant dome was filled with new bone in a predictive way. Although, this approach has been scarcely documented in clinical applications, all reports are conveying a noticeable bone gain and are showing that this procedure can be highly predictable (Lundgren et al. 2003, 2004).

A strong correlation between higher endo-sinus bone gain and reduced RBH was observed on the mesial and distal sides. This means that bone gain was more predictably obtained in sites that displayed limited bone height. Similarly, a good correlation was found between bone gain and implant protrusion. A longer protruding length of the implant may lead to a better tenting effect and may provide more space for bone formation. However, it increases the risk of sinus membrane perforation.

The present OSFE procedure avoided grafting material, it presents the following advantages:

1) there is no need for a donor site involving a more or less invasive surgical approach and no need to get an allograft of animal origin or an alloplastic material, 2) a limited perforation of the membrane may be better perceived while the presence of a grafting material decreases the acuity of this sensation, 3) in case of membrane perforation, there is no risk of penetration of the grafting material in the sinus, 4) the procedure is more affordable without compromising implant predictability.

On the other hand, the use of a filling material permits a larger distension of the membrane and preparation of a larger grafted volume that might be better maintained over time. The material should also, in theory, protect the membrane from perforation by direct contact with the metallic osteotomes.

In conclusion, this procedure showed that elevation of the sinus membrane alone without a grafting material is able to create a space for predictable bone formation beyond the sinus floor. Despite a limited RBH, a healing period of 3-4 months was found to be sufficient to resist a torque of 35 Ncm applied during abutment tightening. At the 1-year control, all implants were in function. Formation of a new recognizable

bone structure delimiting the sinus floor was identified, this radiological evidence increased with time. The OSFE procedure without bone grafting material led to an endo-sinus bone gain of 2.5 mm in average. Endo-sinus bone gain was correlated with a limited RBH.

Acknowledgments

Françoise Porchet, Sylvie Biefer and Monika Dubath are acknowledged for their efficient help during surgery and recall. Dr Florian Combremont is acknowledged for his contribution to illustrations.

References

1. Adell, R., Lekholm, U., Rockler, B. & Brånemark, P.-I. (1981) A 15-year study of osseointegrated implants in the treatment of the edentulous jaw. *International Journal of Oral Surgery* **10**: 387-416.
2. Bahat, O. (1993) Treatment planning and placement of implants in the posterior maxilla: report of 732 consecutive Nobelpharma implants. *International Journal of Oral and Maxillofacial Implants* **8**:151-161.
3. Bahat, O. (2000) Brånemark system implants in the posterior maxilla: clinical study of 660 implants followed for 5 to 12 years. *International Journal of Oral and Maxillofacial Implants* **15**: 646-653.
4. Berengo, M., Sivoilella, S., Majzoub, Z. & Cordioli, G. (2004) Endoscopic evaluation of the bone-added osteotome sinus floor elevation procedure. *International Journal of Oral and Maxillofacial Surgery* **33**: 189-194.
5. Bischof, M., Nedir, R, Abi Najm, S., Szmukler-Moncler, S. & Samson, J. (2006)

- A 5-year Life Table Analysis from a prospective study on Wide Neck ITI implants with prosthetic evaluation and radiographic analysis. Results from a private practice. *Clinical Oral Implants Research*, in press
6. Boyne, P. & James, R. (1980) Grafting of the maxillary floor sinus with autologous marrow and bone. *Journal of Oral Surgery* **38**: 613-616
 7. Brägger, U., Gerber, C., Joss, A., Haenni, S., Meier, A., Hashorva, E., & Lang, N.P. (2004) Patterns of tissue remodelling after placement of ITI dental implants using an osteotome technique: a longitudinal radiographic case cohort study. *Clinical Oral Implants Research* **15**: 158-166.
 8. Brägger, U., Hafeli, U., Huber, B., Hämmerle, C.H. & Lang, N.P. (1998) Evaluation of post-surgical crestal bone levels adjacent to non-submerged dental implants. *Clinical Oral Implants Research* **9**: 218-224.
 9. Bruschi, G.B, Scipioni, A., Celesini, G. & Bruschi, E. (1998) Localized management of sinus floor with simultaneous implant placement. A clinical report. *International Journal of Oral and Maxillofacial Implant* **13**: 219-226.
 10. Buser, D., Mericske-Stern, R., Bernard, J.P., Behneke, A., Behneke, N., Hirt, H.P., Belser, U.C. & Lang, N.P. (1997) Long-term evaluation of non-submerged ITI implants. Part 1: 8-year Life Table Analysis of a prospective multi-center study with 2359 implants. *Clinical Oral Implants Research* **8**: 161-172.
 11. Cavicchia, F., Bravi, F. & Petrelli, G. (2001) Localized augmentation of the maxillary sinus floor through a coronal approach for the placement of implants. *International Journal of Periodontics and Restorative Dentistry* **21**: 475-485.
 12. Chavanaz, M. (1996) Sinus grafted related implantology. Statistical analysis of 15 years of surgical experience. *Journal of Implantology* **22**: 119-130.

13. Cochran, D.L., Buser, D., ten Bruggenkatte, C., Wiengart, D., Taylor, T., Bernard, J.P., Simpson, J.P. & Peters, F. (2002) The use of reduced healing times on ITI implants with a sandblasted and etched (SLA) surface: early results from clinical trials on ITI SLA implants. *Clinical Oral Implants Research* **13**: 144-153.
14. Esposito, M., Hirsch, J.M., Lekholm, U. & Thomsen, P. (1998). Biological factors contributing to failures of osseointegrated oral implants. (I). Success criteria and epidemiology. *European Journal of Oral Sciences* **106**: 527-551.
15. Froum, S.J., Tarnow, D.P., Wallace, S.S., Rohrer, M.D. & Cho, S.C. (1998) Sinus floor elevation using anorganic bovine bone matrix (OsteoGraf/N) with and without autogenous bone: a clinical, histologic, radiographic, and histomorphometric analysis. Part 2 of an ongoing prospective study. *International Journal of Periodontics and Restorative Dentistry* **18**: 528-543.
16. Fugazzotto, P.A. (2002) Immediate implant placement following a modified trephine/osteotome approach: success rate of 116 implants to 4 years in function. *International Journal of Oral and Maxillofacial Implants* **17**: 113-120.
17. Haas, R., Donath, K., Födinger, M. & Watzek G. (1998) Bovine hydroxyapatite for maxillary sinus grafting: comparative histomorphometric findings in sheep. *Clinical Oral Implants Research* **9**: 107-116.
18. Hämmerle, C.H., Brägger, U., Burgin, W. & Lang, N.P. (1996) The effect of subcrestal placement of the polished surface of ITI implants on marginal soft and hard tissues. *Clinical Oral Implants Research* **7**: 111-119.
19. Hartman, G.A. & Cochran, D.L. (2004) Initial implant position determines the magnitude of crestal bone remodelling. *Journal of Periodontology* **75**: 572-577.
20. Hatano, N., Shimizu, Y. & Ooya, K. (2004) A clinical long-term radiographic evaluation of graft height changes after maxillary sinus floor augmentation with

- a 2:1 autogenous bone/xenograft mixture and simultaneous placement of dental implants. *Clinical Oral Implants Research* **15**: 339-345.
21. Isidor, F. (1996) Loss of osseointegration caused by occlusal load of oral implants. A clinical and radiographical study in monkeys. *Clinical Oral Implants Research* **7**: 143-152
 22. Jensen, O.T., Shulman, L.B., Block, M.S. & Iacone, V.J. (1998) Report of the sinus consensus conference of 1996. *International Journal of Oral and Maxillofacial Implants (Special sup.)*: 11-32.
 23. John, H.D. & Wenz, B. (2004) Histomorphometric analysis of natural bone mineral for maxillary sinus augmentation. *International Journal of Oral and Maxillofacial Implants* **19**: 199-207.
 24. Leblebicioglu, B., Ersanli, S., Karabuda, C., Tosun, T. & Gokdeniz, H. (2005) Radiographic evaluation of dental implants placed using an osteotome technique. *Journal of Periodontology* **76**: 385-90.
 25. Lekholm, U. & Zarb, G.A. (1985) Patient selection and preparation. In : Brånemark, P.-I., Zarb, G.A. & Albrektsson, T., eds. *Tissue integrated prostheses: Osseointegration in Clinical Dentistry*, 199-209. Chicago: Quintessence Publishing Company.
 26. Lundgren, S., Andersson, S. & Sennerby, L. (2003) Spontaneous bone formation in the maxillary sinus after removal of a cyst: Coincidental or expected reaction? *Clinical Implant Dentistry and Related Research* **5**: 78-81.
 27. Lundgren, S., Andersson, S., Gualini, F. & Sennerby, L. (2004) Bone reformation with sinus membrane elevation: a new surgical technique for maxillary sinus floor augmentation. *Clinical Implant Dentistry and Related Research* **6**: 165-173.

28. Nedir, R., Bischof, M., Briaux, J.M., Beyer, S., Szmukler-Moncler, S. & Bernard, J.P. (2004) A 7-year Life Table Analysis from a prospective study on ITI implants with special emphasis on the use of short implants. Results from a private practice. *Clinical Oral Implants Research* **15**: 150-157.
29. Nkenke, E., Radespiel-Troger, M., Wiltfang, J., Schultze-Mosgau, S., Winkler, G. & Neukam, F. W. (2002) Morbidity of harvesting of retromolar bone grafts: a prospective study. *Clinical Oral Implants Research* **13**: 514-521.
30. Ozyuvaci, H., Bilgic, B. & Firatli E. (2003) Radiologic and histomorphometric evaluation of maxillary sinus grafting with alloplastic graft materials. *Journal of Periodontology* **74**: 909-915.
31. Piattelli, M., Favero, G.A., Scarano, A., Orsini, G. & Piattelli, A. (1999) Bone reactions to anorganic bovine bone (Bio-Oss) used in sinus augmentation procedures: a histologic long-term report of 20 cases in humans. *International Journal of Oral and Maxillofacial Implants* **14**: 835-840.
32. Raghoobar, G.M., Timmenga, N.M., Reintsema, H., Stegenga, B. & Vissink, A. (2001) Maxillary bone grafting for insertion of endosseous implants: results after 12-124 months. *Clinical Oral Implants Research* **12**: 279-286.
33. Reinert, S., Konig, S., Bremerich, A., Eufinger, H. & Krimmel, M. (2003) Stability of bone grafting and placement of implants in the severely atrophic maxilla. *British Journal of Oral and Maxillofacial Surgery* **41**: 249-55.
34. Reiser, G.M., Rabinovitz, Z., Bruni, J., Damoulis, P. & Griffin, T.J. (2001) Evaluation of maxillary sinus membrane response following elevation with the crestal osteotome technique in human cadavers. *International Journal of Oral and Maxillofacial Implants* **16**: 833-840.
35. Rocuzzo, M., Bunino, M., Prioglio, F. & Bianchi, S.D. (2001) Early loading of

- sandblasted and acid etched (SLA) implants: A prospective split-mouth comparative study. *Clinical Oral Implants Research* **12**: 572-578.
36. Rosen, P.S., Summers, R., Mellado, J.R., Salkin, L.M., Shanaman, R.H., Marks, M.H. & Fugazzotto, P.A. (1999) The bone-added osteotome sinus floor elevation technique: multicenter retrospective report of consecutively treated patients. *International Journal of Oral and Maxillofacial Implants* **14**: 853-858.
37. Scharf, D.R. & Tarnow, D.P. (1993) Success rates of osseointegration for implants placed under sterile versus clean conditions. *Journal of Periodontology* **64**: 954-956.
38. Schwarz-Arad, D. & Dolev, E. (2000) The challenge of endosseous implants placed in the posterior partially edentulous maxilla: a clinical report. *International Journal of Oral and Maxillofacial Implants* **15**: 261-264.
39. Summers, R.B: (1994a) A new concept in maxillary implant surgery: The osteotome technique. *Compendium of Continuous Education in Dentistry* **15**: 152-160.
40. Summers, R.B: (1994b) The osteotome technique. Part 3. Less invasive methods in elevation of the sinus floor. *Compendium of Continuous Education in Dentistry* **15**: 698-708.
41. Tatum, O.H (1986) Maxillary and sinus implant reconstructions. *Dental Clinic of North America* **30**: 207-229.
42. Testori, T., Wiseman, L., Woolfe, S. & Porter, S.S. (2001) A prospective multicenter clinical study of the Osseotite implant: four-year interim report. *International Journal of Oral and Maxillofacial Implants* **16**: 193-200.
43. Testori, T., Del Fabbro, M., Feldman, S., Vincenzi, G., Sullivan, G., Rossi, R, Jr., Anitua, E., Bianchi, F., Francetti, L. & Weinstein, R.L. (2002) A multi-center

- prospective evaluation of 2-months loaded Osseotite implants in the posterior jaws: 3-year follow-up results. *Clinical Oral Implants Research* **13**: 154-161.
44. Tidwell, J.K., Blijdorp, P.A., Stoelinga, P.J., Brouns, J.B. & Hinderks, F. (1992) Composite grafting of the maxillary sinus for placement of endosteal implants. A preliminary report of 48 patients. *International Journal of Oral and Maxillofacial Surgery* **21**: 204-209.
 45. Timmenga, N.M., Raghoobar, G.M., Liem, R.S., van Weissenbruch, R., Manson, W.L. & Vissink, A. (2003) Effects of maxillary sinus floor elevation surgery on maxillary sinus physiology. *European Journal of Oral Science* **111**: 189-197.
 46. Toffler, M. (2004) Osteotome-mediated sinus floor elevation: a clinical report. *International Journal of Oral and Maxillofacial Implants* **19**: 266-273.
 47. Weber, H.P., Crohin, C.C. & Fiorellini, J.P. (2000) A 5-year prospective clinical and radiographic study of non-submerged dental implants *Clinical Oral Implants Research* **11**: 144-153.
 48. Weng, D., Jacobson, Z., Tarnow, D., Hurzeler, M.B., Faehn, O., Sanavi, F., Barkvoll, P. & Stach, R.M. (2003). A prospective multicenter clinical trial of 3i machined-surface implants: results after 6 years of follow-up. *International Journal of Oral and Maxillofacial Implants* **18**: 417-423.
 49. Winter, A.A., Pollack, A.S. & Odrich, R.B. (2002) Placement of implants in the severely atrophic posterior maxilla using localized management of the sinus floor. *International Journal of Oral and Maxillofacial Implants* **17**: 687-695.
 50. Winter, A.A., Pollack, A.S. & Odrich, R.B. (2003) Sinus/alveolar crest tenting (SACT): a new implantation technique in atrophied maxillae ridges without bone grafting or membrane *International Journal of Periodontics and Restorative Dentistry* **23**: 557-565.

51. Zerbo, I.R., Zijdeveld, S.A., de Boer, A., Bronckers, A.L., de Lange, G., ten Bruggenkate, C.M. & Burger, E.H. (2004) Histomorphometry of human sinus floor augmentation using a porous beta-tricalcium phosphate: a prospective study. *Clinical Oral Implants Research* **15**: 724-732.
52. Zitzmann, N.U. & Schäfer, P. (1998) Sinus elevation procedures in the resorbed posterior maxilla. Comparison of the crestal and lateral approaches. *Oral Surgery Oral Medicine Oral Pathology Oral Radiology and Endodontics* **85**: 8-17.

Captions

Table 1

Difference in RBH recorded between the mesial and the distal sides of an implant.

Note that the difference was larger than 2 mm for 40 % of the implants.

Table 2

Detail of the RBH on one and two implant sides.

Table 3

Distribution and frequency of the endo-sinus bone gain.

Table 4

Distribution and frequency of the crestal bone loss.

Figure 1

Schematic drawing of the parameters measured on the radiographs taken immediately after implant placement and at the 1-year control.

The A distance corresponds to the RBH under the sinus. B corresponds to the distance from the most coronal implant thread to the most apical visible implant-bone contact. Increase of the B distance on the 1-year radiograph corresponds to endo-sinus bone gain. The C distance corresponds to implant length protruding in the sinus. The D distance corresponds to the distance between the most apical implant thread and the most coronal bone-implant contact. Decrease of the D distance on the 1-year radiograph corresponds to crestal bone loss.

Figure 2

Evolution with time of sinus demarcation after the OSFE procedure without grafting material. a) Radiograph taken immediately after implant placement. b) Radiograph taken at the 1-year control. Note the endo-sinus bone gain and the crestal bone loss down to the smooth-rough boundary due to deeper implant placement.

Figure 1

Schematic drawing of the parameters measured on the radiographs taken immediately after implant placement and at the 1-year control.

The A distance corresponds to the RBH under the sinus. B corresponds to the distance from the most coronal implant thread to the most apical visible implant-bone contact. Increase of the B distance on the 1-year radiograph corresponds to endo-sinus bone gain. The C distance corresponds to implant length protruding in the sinus. The D distance corresponds to the distance between the most apical implant thread and the most coronal bone-implant contact. Decrease of the D distance on the 1-year radiograph corresponds to crestal bone loss.

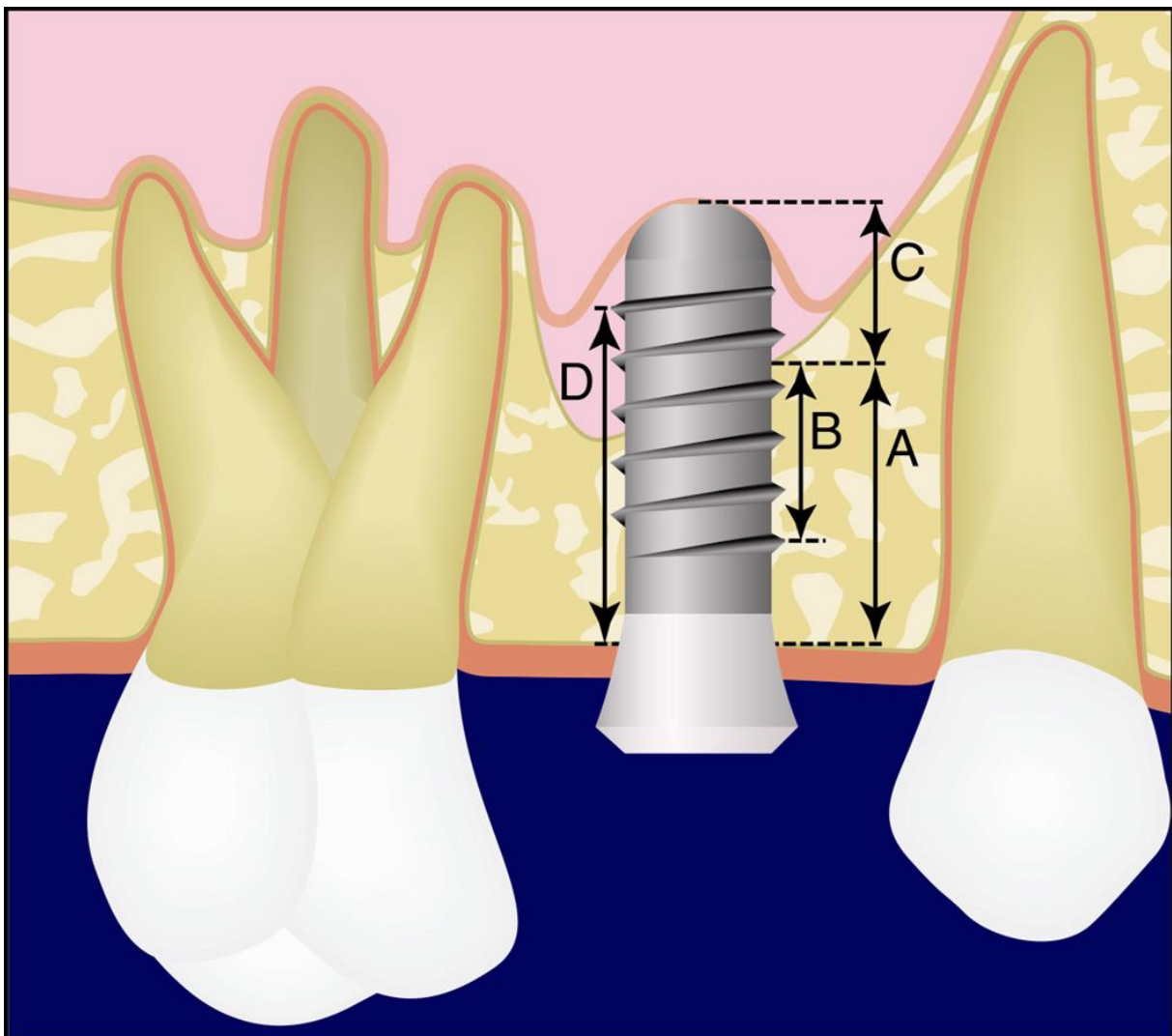


Figure 2

Evolution with time of sinus demarcation after the OSFE procedure without grafting material. a) Radiograph taken immediately after implant placement. b) Radiograph taken at the 1-year control. Note the endo-sinus bone gain and the crestal bone loss down to the smooth-rough boundary due to deeper implant placement.

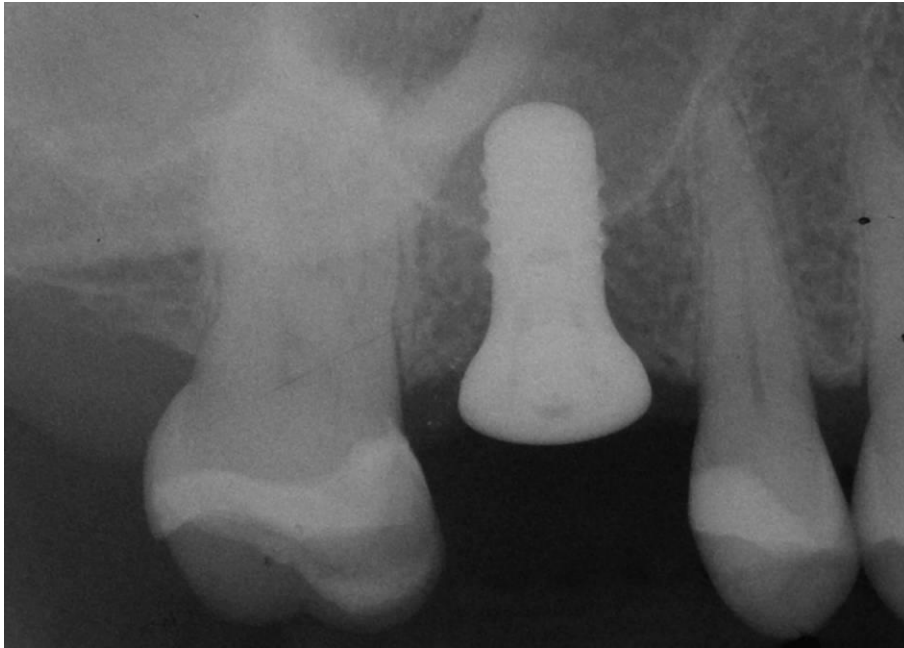


Table 1

Difference in bone height	0-1 mm	1-2 mm	2-3 mm	3-4 mm	4-5 mm	5-6 mm
Number of implants	5	10	6	2	1	1
Percentage	20%	40%	24%	8%	4%	4%

Table 2

Residual bone height	on both implant sides	on at least one implant side
< 4 mm	5	9
< 6 mm	11	21
≤ 8 mm	18	25

Table 3

Gain	Mesial side	Distal side	Sum
Gain 0-1 mm	3 (12.0 %)	0 (0.0 %)	3 (6.0 %)
Gain 1-2 mm	8 (32.0 %)	8 (32.0 %)	16 (32.0 %)
Gain 2-3 mm	5 (20.0 %)	9 (36.0 %)	14 (28.0 %)
Gain 3-4 mm	7 (28.0 %)	6 (24.0 %)	13 (26.0 %)
Gain > 4 mm	2 (8.0 %)	2 (8.0 %)	4 (8.0 %)
Sum	25 (100 %)	25 (100 %)	50 (100 %)

Table 4

CBL	Mesial side	Distal side	Sum
0-0.5 mm	4 (16.0 %)	4 (16.0 %)	8 (16.0 %)
0.5-1.0 mm	3 (12.0 %)	9 (36.0 %)	12 (24.0 %)
1.0-1.5 mm	7 (28.0 %)	6 (24.0 %)	13 (26.0 %)
1.5-2.0 mm	5 (20.0 %)	5 (20.0 %)	10 (20.0 %)
> 2.0 mm	6 (24.0 %)	1 (4.0 %)	7 (28.0 %)
Sum	25 (100 %)	25 (100 %)	50 (100 %)