

Effectiveness of the GentleWave System in Removing Separated Instruments

Pierre Wohlgenuth, DDS,* Davide Cuocolo, DDS,* Prashanthi Vandurangi, PhD,[†] and Asgeir Sigurdsson, DDS, MS*

Abstract

Introduction: A separated instrument in a root canal system has the potential of severely affecting the outcome of endodontic therapy. This study evaluated the effectiveness of the minimally invasive GentleWave System (Sonendo Inc, Laguna Hills, CA) in removing separated stainless steel endodontic files from the apical and midroot regions of molar root canals. **Methods:** Thirty-six extracted human molars were accessed, and the glide path was confirmed to the apex. ISO #10, #15, and #20 K-file fragments of 2.5-mm length were separated at the apical ($n = 18$) or midroot ($n = 18$) region of the molars by engaging a weakened file with downward pressure. During analysis, the teeth were divided into 2 curved groups based on the curvature of the root ($<30^\circ$ and $>30^\circ$). The success rate of instrument removal and the treatment time were noted. Statistical comparison was done with the Fisher exact test and independent 2-sample t test ($P < .05$). **Results:** The overall success rate of instrument removal when the separated files were engaged in the apical region was 61%, and for the midroot region, it was 83%. Less curved canals ($<30^\circ$) showed a 91% success rate ($n = 24$), whereas canals with an angle of curvature greater than 30° showed a 42% success rate ($n = 12$). The median treatment time for instrument retrieval was 10 minutes 44 seconds. **Conclusions:** The results revealed that the GentleWave System is effective in retrieving separated instruments while conserving the dentinal structure. (*J Endod* 2015; ■:1–4)

Key Words

File separation, GentleWave System, Multisonics Ultracleaning, steel hand files

Separated instruments in a root canal have the potential to compromise the outcome of endodontic therapy because they prevent access to the apex and thereby impede thorough cleaning, shaping, and sealing of the root canal system (1, 2). Previous studies have shown that the incidence of separation of stainless steel hand instruments can be as high as 6% (1, 3). The most common reasons for steel file separation in canals can be attributed to 1 of 2 reasons, torsional failure and/or cyclic fatigue (4, 5). In cases of torsional failure, the tip of the file binds and if the file is either continued to be rotated clockwise or it is pulled out with force greater than its torsional strength, it will separate (4). Additionally, steel files are subjected to wear and tear because of continuous bending in curved canals, causing a dynamic fracture similar to the cyclic fatigue that can occur for nickel-titanium rotary files (5–7).

Several systems, including ultrasonics, the Masserann kit (Micro-Mega, Besancon Cedex, France), and the Nd:YAG laser have been introduced to aid the endodontist in removing or bypassing the separated instrument (8–12). Almost all of these systems require direct access and visualization of the separated instrument and the success of removal has varied (9–15). Nevares et al (16) showed that when using ultrasonic tips, 85.3% of visible fractured instrument fragments could be removed compared with only 47.7% of nonvisible instrument fragments. It is important to note that the investigators had to sometimes remove a substantial amount of dentin to gain straight-line access to the fragment. In another study, the Nd:YAG laser provided a 55% success rate in removal; however, it was accompanied with a temperature rise between 17°C and 27°C (17). Using the Masserann kit, a 55% success rate in removal was reported, again accompanied with extensive dentinal removal, and it was concluded that the kit had limited application in posterior teeth with thin and curved roots (18). These results indicate that the prerequisite for better success was a straight-line view of the separated instrument such that troubleshooting around it was possible, in most cases compromising the root integrity.

Even though these procedures can be successful, complications like extrusion of the fragment apically, temperature rise on the external surface of the root, operator fatigue, compromise of the root canal wall thickness, and perforations are often reported (12, 13, 19–21). All the potential complications associated with the current processes of the removal of separated instruments calls for new and more conservative techniques.

The GentleWave System has been designed to deliver a broad spectrum of waves within the irrigant to effectively clean the root canal system (22–25). Molina et al (24) showed that the GentleWave System (Sonendo Inc, Laguna Hills, CA) thoroughly cleans the root canal system even in the apical thirds. More importantly, Charara et al (25) showed no extrusion when teeth were treated with the GentleWave System. These studies introduced the concept of Multisonic Ultracleaning and provided the motivation of the present work to evaluate the possibility of the removal of a separated instrument using the GentleWave System. The aim of this study was to investigate the success in removing a separated hand steel file from the mid and apical thirds of extracted molar teeth using the GentleWave System.

Methods

Thirty-six extracted human first and second molars with varying degrees of root curvatures were collected and stored in phosphate-buffered saline at 4°C . Teeth with decay

From the *Department of Endodontics, New York University College of Dentistry, New York, New York; and [†]Sonendo Inc, Laguna Hills, California.

Address requests for reprints to Dr Asgeir Sigurdsson, Department of Endodontics, New York University College of Dentistry, 345 East 24 Street, New York, NY 10010. E-mail address: asgeir.sigurdsson@nyu.edu
0099-2399/\$ - see front matter

Copyright © 2015 American Association of Endodontists.
<http://dx.doi.org/10.1016/j.joen.2015.08.015>

Basic Research—Technology

or fractures below the cemento-enamel junction, internal or external resorption, open apices, or previous endodontic therapy were excluded. Only intact mesiobuccal canals of maxillary molars and mesial canals of mandibular molars were selected. The roots of all teeth were sealed and firmly secured within a water-saturated porous medium to simulate blood-saturated periradicular tissue.

Preparation of the Instrument

Before placement into the canal, a notch was carefully cut on the #10, #15, or #20 K-files to a depth of half the thickness of the file using a diamond disc (NTI; Rotary Dental Instruments, Kahla, Germany). The location of the notch was 2.5 mm from the tip of the instrument (26).

Initial Radiographic Evaluation

After endodontic access, all teeth were radiographed, and the root curvature was measured using ImageJ (National Institutes of Health, Bethesda, MD) (27, 28).

The working length, defined as 1 mm from the apical foramen, was determined. Patency was confirmed with #6, #8, and/or #10 K-files (K-files; MANI, Utsunomiya, Japan) for all the canals. The patency/instrumentation protocol was as follows: for the separation of #10 K-files, the canals were explored with a hand file of #6; for #15 K-files, the canals were explored/instrumented to #8; and for #20 K-files, the canals were explored/instrumented to #10. During initial instrumentation, approximately 2 mL 3% sodium hypochlorite (NaOCl; Clorox, Oakland, CA) was delivered using a 30-G Max-I-Probe needle (Dentsply Rinn, Elgin, IL). Occasionally, the first 2 mm of the canal was opened using a #2 Gates Glidden drill for coronal flaring.

Separation of the Weakened Instrument

The notched files were placed as far as possible toward the working length with clockwise rotation and downward pressure until the file separated by 2 calibrated operators.

Postinstrument Separation Radiograph

Radiographs were taken buccolingually and mesiodistally to confirm instrument separation. The location of the separated instrument was recorded.

GentleWave System Treatment

The handpiece of the GentleWave System was placed on the accessed tooth as described previously (23–25). GentleWave System treatment was performed with 3% NaOCl for 5 minutes, distilled water for 30 seconds, 8% EDTA for 2 minutes, and distilled water for 15 seconds in sequence for a total treatment time of 7 minutes 45 seconds (24–25). Radiographs were taken after each GentleWave System treatment cycle to investigate if the file fragment had been removed. A maximum of 3 treatment cycles (the total treatment time was 23 minutes 25 seconds) were performed. Success was defined as the complete removal of the separated instrument. In this study, 2 trained clinicians operated the GentleWave System, independent of who separated the instrument.

Evaluation of Removal Success

The percentage of success for the removal of the separated instruments was calculated using the following equation:

$$\% \text{ Success} = \frac{\# \text{ Separated Instruments Removed}}{\text{Total } \# \text{ Canals Treated}} \times (100\%)$$

Statistical Analysis

The amount of time needed for removal was analyzed for each sample. Data sets were analyzed with the Fisher exact test and the independent 2-sample *t* test at $P = .05$.

Results

Of the 36 teeth, file fracture occurred 18 times in the apical and 18 times in the midroot regions. Figure 1A and B shows representative radiographs of the molars before and after the removal of #10, #15, and #20 files from the apical and midroot regions. The instruments were successfully removed 61.1% of the time when engaged in the apical region and 83.3% of the time when engaged in the midroot region. When comparing different file sizes, #10 K-files were removed 75% of the time, #15 K-files were removed 92% of the time, and #20 K-files were removed 50% of the time (Fig. 2A). There was no significant difference in the removal of the separated instruments from the locations of file engagement and the file sizes ($P = .798$).

When comparing the effect of the root curvature with the success of removal of the engaged file fragments, the files were successfully removed 91% of the time when the curvature was less than 30° and 42% of the time when the curvature exceeded 30° (Fig. 2B). The association between the removal of separated instruments and the curvature of roots was statistically significant (Fisher exact test at $P = .003$).

Fourteen separated instruments (5 in the apical region and 9 in the midroot region) were successfully removed in 7 minutes 45 seconds (1 treatment). Eight separated instruments (3 in the apical region and 5 in the midroot region) were removed within 15 minutes 30 seconds (2 treatments). Four separated instruments (3 in the apical region and 1 in the midroot region) were removed within 23 minutes 15 seconds. The exact time of removal was not determined because the samples were radiographed after each full GentleWave System treatment, hence providing an upper bound of the removal time (in increments of 7 minutes 45 seconds). The median treatment time needed for the 26 successful cases was 10 minutes 44 seconds. The mode (most frequent treatment time) for successfully removing the separated instrument was 7 minutes 45 seconds (Table 1).

There was no significant difference in the removal of the separated instruments from the apical and midroot regions (Fisher exact test at $P = .99$) between the 2 operators.

Discussion

A separated instrument is an obstacle to the apex. It prevents optimal shaping of the root canal system, impedes the cleaning of tissue debris and bacteria from the apical portion of the root, and can compromise the success rate of endodontic therapy (29).

Various methods have been developed and are recommended for the removal of the separated instruments. Most lack clinical practicality and can in many cases be quite destructive to the root.

Overenlargement of the canal when attempting to remove a separated instrument compromises the dentinal structure and integrity, thereby making the roots prone to fractures (30, 31). For example, in a study using the Masseran kit, the thickness of the dentin in the apical third was reduced to the critical thickness (32). When the ultrasonic system is used, the mean load required to induce root fractures is inversely proportional to the depth of the root canal system; therefore, the deeper the instrument is the higher the risk of fracturing the root (33). Using the GentleWave System, the dentinal integrity is not compromised because the technology involves no shaping or instrumentation and no further dentin is removed.

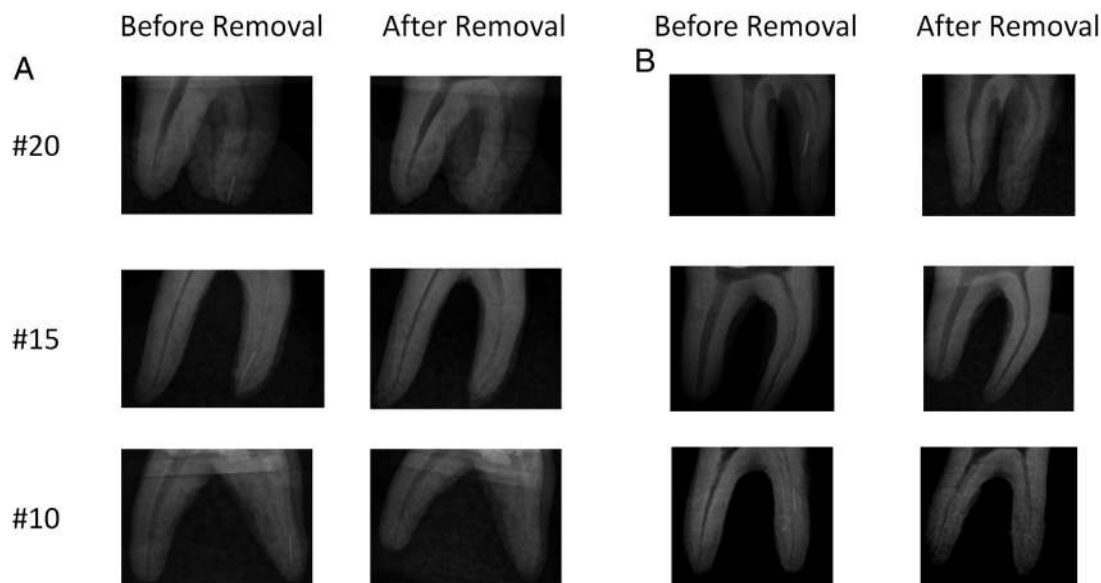


Figure 1. Representative radiographs showing the buccolingual or the mesiobuccal views of the molars before removal and after removal of #20, #15, and #10 files. Files were separated in the (A) apical region and the (B) midroot region. The median treatment time was 10 minutes 44 seconds.

It is important to note that the GentleWave System is performed in the presence of irrigants, hence mitigating issues, such as heat damage and desiccation, associated with current retrieval techniques (12). It is conceivable that the GentleWave System is able to move activated irrigant solutions in a similar fashion as has been shown already in unobstructed canals, along wedged instruments in case of ovoid canals and thereby clean the canals along if not beyond the instrument, even though it has not been successfully removed (22). Future studies should also probe into the cleaning efficiency of the GentleWave System around and beyond the separated instruments in cases in which the separated instruments could not be removed.

Furthermore, the use of Masserann kits and ultrasonic tips is limited in curved canals (12, 31, 33). In the present study, when using the GentleWave System, a success rate of 42% was observed in

canals where the angle of curvature was greater than 30° , indicating that removal is possible beyond the curve without any preparation or removal of root dentin.

The GentleWave System uses various phenomena with degassed treatment fluids inside the root canal system. A reduced amount of dissolved gas within the treatment fluid allows for interplay between propagating multisonic energy and fluid dynamics. The GentleWave System disperses different treatment fluids from the tip of the handpiece into the pulp chamber. When the treatment fluid is dispersed from the handpiece and is in contact with stagnant fluids in the pulp chamber, because of shear forces, hydrodynamic cavitation occurs, forming thousands of microbubbles called a cavitation cloud. The bubbles subsequently implode and create sound waves that cover a broad frequency spectrum (Multisonic Ultracleaning spectra) that reverberate and contribute to

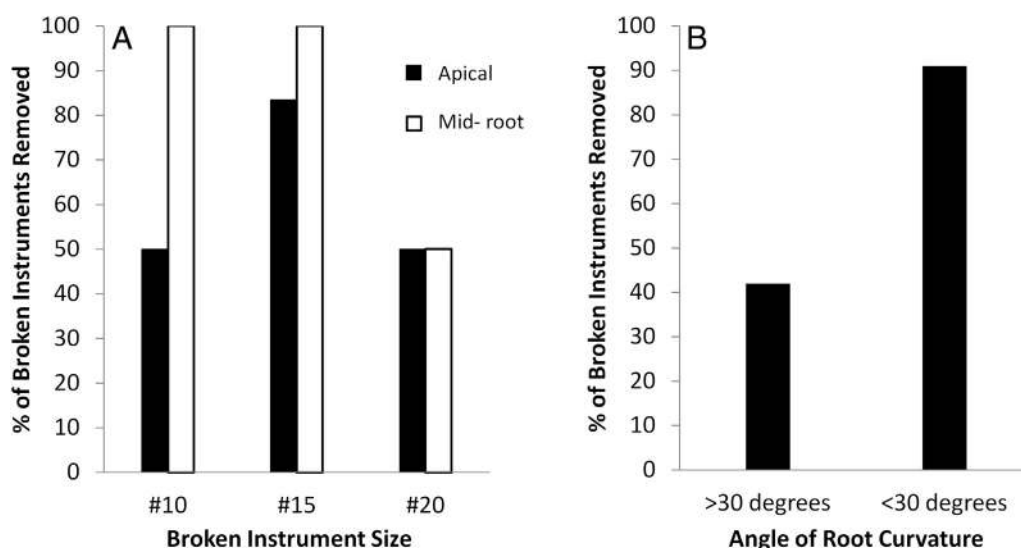


Figure 2. (A) The percentage of separated instruments removed when the instruments (K-files #10, #15, and #20) were separated either in the apical or midroot region. (B) The mesials of mandibular molars and mesiobuccals of maxillary molars (separated in both the apical and midroot regions) were divided into 2 groups: $>30^\circ$ and $<30^\circ$.

Basic Research—Technology

TABLE 1. The Time Taken for Removal of the Separated Instrument When Retrieved from the Apical or the Midroot Region of the Molars

| Treatment time (minutes) | Apical (%) | Midroot (%) |
|--------------------------|------------|-------------|
| <8 | 45 | 60 |
| >8 and <16 | 27 | 33 |
| >16 and <24 | 27 | 67 |

the cleaning throughout the entire root canal system. Excess fluid is continuously removed from the chamber by the built-in suction along with a proprietary fluid handling system. More information about the controlled fluid delivery and suctioning of the GentleWave System has been explained previously (24, 25). The presence of the Multisonic Ultracleaning energy in combination with advanced fluid dynamics enables the loosening of the separated instruments when engaged in the dentinal wall. Furthermore, the interplay of fluid dynamics and acoustics eventually lead to the higher success rate in the removal of separated instruments.

In an effort to standardize the fracture and minimize the effect of instrumentation, all the steel files in this study were weakened by cutting a notch 2.5 mm from the tip. This potentially has the effect that the file separation in this study mimics dynamic (cyclic) failure rather than torsional. The torsional failures could be harder to remove because of the fact that they are possibly more firmly wedged in the canals. Even though this study is limited to evaluate the GentleWave System for removing fragments of steel hand files, it is worth noting that the separation rate of rotary file instruments is greater than that of hand files (26). Of interest will be to test the performance of the GentleWave System in the removal of rotary files. Furthermore, the removal of separated instruments using the GentleWave System in tooth types other than molars has yet to be investigated. In the future, clinical studies showing the efficiency of the GentleWave System in the removal of separated instruments are warranted.

Conclusion

In conclusion, within the limitations of this study, the GentleWave System showed 61.3% and 83.3% success rates in removing separated instruments from the apical and midroot regions, respectively, when treated for a median time of 10 minutes 44 seconds. The removal rate was independent of the operator who separated the instruments and performed the GentleWave System treatments, and no instrumentation or manual opening of canals after the file was separated was necessary for the GentleWave System to successfully dislodge a significant number of files. Even though further *in vivo* case studies are necessary, these results may have implications in the success of root canal treatment when an instrument has been separated in the root canal.

Acknowledgments

We acknowledge Drs Mehrzad Khakpour and Mandana Ziai for their input and support while performing the experiments.

Supported in part by Sonendo Inc.

Prashanthi Vandurangi is an employee of Sonendo Inc, and Asgeir Sigurdsson has a commercial interest in the tested product.

References

- Crump MC, Natkin E. Relationship of broken root canal instruments to endodontic case prognosis: a clinical investigation. *J Am Dent Assoc* 1970;80:1341–7.
- Feldman G, Solomon C, Notaro P, Moskowitz E. Retrieving broken endodontic instruments. *J Am Dent Assoc* 1974;88:588–91.
- Hulsmann M, Schinkel I. Influence of several factors on the success or failure of removal of fractured instruments from the root canal. *Endod Dent Traumatol* 1999;15:252–8.
- Roth WC, Gough RW, Grandich RA, Walker WA 3rd. A study of the strength of endodontic files: potential for torsional breakage and relative flexibility. *J Endod* 1983;9:228–32.
- Haikel Y, Gasser P, Allemann C. Dynamic fracture of hybrid endodontic hand instruments compared with traditional files. *J Endod* 1991;17:217–20.
- Haikel Y, Serfaty R, Bateman G, et al. Dynamic and cyclic fatigue of engine-driven rotary nickel-titanium endodontic instruments. *J Endod* 1999;25:434–40.
- Bahia MG, Martins RC, Gonzalez BM, Buono VT. Physical and mechanical characterization and the influence of cyclic loading on the behaviour of nickel-titanium wires employed in the manufacture of rotary endodontic instruments. *Int Endod J* 2005;38:795–801.
- Ruddle CJ. Nonsurgical retreatment. *J Endod* 2004;30:827–45.
- Gencoglu N, Helvacoglu D. Comparison of the different techniques to remove fractured endodontic instruments from root canal systems. *Eur J Dent* 2009;3:90–5.
- Alomairy KH. Evaluating two techniques on removal of fractured rotary nickel-titanium endodontic instruments from root canals: an *in vitro* study. *J Endod* 2009;35:559–62.
- Terauchi Y, O'Leary L, Kikuchi I, et al. Evaluation of the efficiency of a new file removal system in comparison with two conventional systems. *J Endod* 2007;33:585–8.
- Madarati AA, Hunter MJ, Dummer PM. Management of intracanal separated instruments. *J Endod* 2013;39:569–81.
- D'Arcangelo C, Varvara G, De Fazio P. Broken instrument removal—two cases. *J Endod* 2000;26:368–70.
- Shen Y, Peng B, Cheung GS. Factors associated with the removal of fractured NiTi instruments from root canal systems. *Oral Surg Oral Med Oral Pathol Oral Radiol Endod* 2004;98:605–10.
- Madarati AA, Qualtrough AJ, Watts DC. Efficiency of a newly designed ultrasonic unit and tips in reducing temperature rise on root surface during the removal of fractured files. *J Endod* 2009;35:896–9.
- Nevaras G, Cunha RS, Zuolo ML, Bueno CE. Success rates for removing or bypassing fractured instruments: a prospective clinical study. *J Endod* 2012;38:442–4.
- Yu DG, Kimura Y, Tomita Y, et al. Study on removal effects of filling materials and broken files from root canals using pulsed Nd:YAG laser. *J Clin Laser Med Surg* 2000;18:23–8.
- Hulsmann M. Methods for removing metal obstructions from the root canal. *Endod Dent Traumatol* 1993;9:223–37.
- Madarati AA, Watts DC, Qualtrough AJ. Factors contributing to the separation of endodontic files. *Br Dent J* 2008;204:241–5.
- Esen E, Yoldas O, Kurkcu M, et al. Apical microleakage of root-end cavities prepared by CO₂ laser. *J Endod* 2004;30:662–4.
- Iqbal MK, Rafailov H, Kratchman SI, Karabucak B. A comparison of three methods for preparing centered platforms around separated instruments in curved canals. *J Endod* 2006;32:48–51.
- Haapasalo M, Wang Z, Shen Y, et al. Tissue dissolution by a novel multisonic ultracleaning system and sodium hypochlorite. *J Endod* 2014;40:1178–81.
- Ma J, Shen Y, Yang Y, et al. *In vitro* study of calcium hydroxide removal from mandibular molar root canals. *J Endod* 2015;41:553–8.
- Molina B, Glickman GN, Vandurangi P, Khakpour M. Histological evaluation of root canal debridement of human molars using the GentleWave™ system. *J Endod* 2015 Aug 11; <http://dx.doi.org/10.1016/j.joen.2015.06.018>. pii: S0099-2399(15)00599-3. [Epub ahead of print].
- Charara K, Friedman S, Sherman A, et al. Assessment of apical extrusion during root canal procedure with the novel GentleWave system in a simulated apical environment. *J Endod* 2015. In Press.
- Skyttner B. Endodontic instrument separations: evaluation of a patient cases series with separated endodontic instruments and factors related to the treatment regarding separated instruments [thesis]. Stockholm: Karolinska Institutet; 2007.
- Schneider CA, Rasband WS, Eliceiri KW. NIH Image to ImageJ: 25 years of image analysis. *Nat Methods* 2012;9:671–5.
- Schneider SW. A comparison of canal preparations in straight and curved root canals. *Oral Surg Oral Med Oral Pathol* 1971;32:271–5.
- Ward JR. The use of an ultrasonic technique to remove a fractured rotary nickel-titanium instrument from the apical third of a curved root canal. *Aust Endod J* 2003;29:25–30.
- Fors UG, Berg JO. A method for the removal of broken endodontic instruments from root canals. *J Endod* 1983;9:156–9.
- Souter NJ, Messer HH. Complications associated with fractured file removal using an ultrasonic technique. *J Endod* 2005;31:450–2.
- Suter B, Lussi A, Sequeira P. Probability of removing fractured instruments from root canals. *Int Endod J* 2005;38:112–23.
- Yoldas O, Oztunc H, Tinaz C, Alparlan N. Perforation risks associated with the use of Masserann endodontic kit drills in mandibular molars. *Oral Surg Oral Med Oral Pathol Oral Radiol Endod* 2004;97:513–7.