

Short implants placed with or without grafting into atrophic sinuses. The 5-year results of a prospective randomized controlled study.

Rabah Nedir¹, Nathalie Nurdin¹, Semaan Abi Najm², Marc El Hage³, Mark Bischof³

¹ Ardentis Clinique Dentaire Vevey, Swiss Dental Clinics Group, Vevey, Switzerland.

² Ardentis Clinique Dentaire Geneva, Swiss Dental Clinics Group, Geneva, Switzerland

³ Ardentis Clinique Dentaire Lausanne, Swiss Dental Clinics Group, Lausanne, Switzerland.

Running title

Sinus elevation in atrophic maxillae with or without grafting

Corresponding author

Dr Rabah Nedir

Ardentis Clinique Dentaire Vevey, Swiss Dental Clinics Group

Rue du Collège 3, 1800 Vevey, Switzerland

Tel.: + 41 58 234 00 10, e-mail: rabah.nedir@ardentis.ch

Key words

atrophic maxilla, bone gain, bone graft, bone regeneration, crestal bone loss, dental implants, internal sinus lift, no grafting, osteotome sinus floor elevation, posterior maxilla, prospective randomized clinical trial, sinus-lift

ABSTRACT

Objectives: Over five years, 1) to evaluate the clinical efficiency of 8-mm implants placed with osteotome sinus floor elevation (OSFE) in extremely atrophic maxillae and 2) to compare bone levels around implants placed with and without grafting.

Material and Methods: TE[®] SLActive[®] implants (Institut Straumann AG, Basel, Switzerland) were placed in sites with a residual bone height (RBH) of ≤ 4 mm. Before surgery, sinuses were randomized to receive anorganic bovine bone (control) or no graft (test). After 10 weeks of healing, implants were functionally loaded with single crowns. Bone levels were measured from standardized peri-apical radiographs.

Results: Thirty-seven (17 test, 20 control) implants were placed in 12 patients (RBH: 2.4 ± 0.9 mm). Two early and one late failures occurred. The success rate was 91.9% (94.1% test, 90.0% control). All implants gained endo-sinus bone (3.8 ± 1.0 mm test, 4.8 ± 1.2 mm control; $p = 0.004$). Mean crestal bone loss (CBL) was 0.6 ± 1.1 mm, without significant difference between the groups ($p = 0.527$). Mean bone gain and CBL did not change significantly between one and five years ($p = 0.249$ and $p = 0.293$, respectively).

Conclusions: Atrophic posterior maxillae can be predictably rehabilitated using OSFE with simultaneous implant placement. The new bone formed around implants after one year was stable after five years, irrespective of the presence or absence of graft. Grafting was unnecessary to achieve an average bone augmentation of 3.8 mm but more bone was gained with grafting.

INTRODUCTION

The severely atrophic edentulous posterior maxilla can be treated with a bone grafting technique to provide sufficient bone volume for implant placement. When the maxillary residual bone height (RBH) is <6 mm, the lateral approach through a bony window is recommended; this involves the use of a grafting material in conjunction with immediate or delayed implant placement (Jensen et al. 1998). The osteotome sinus floor elevation (OSFE) procedure through the crestal approach (Summers 1994) is less invasive than the lateral approach, less time-consuming and reduces post-operative discomfort. The augmented bone volume is usually less than that obtained using the lateral technique. Until recently, OSFE was applied when the RBH was >5 mm (Chen et al. 2011) and a minimum RBH of 5 mm is recommended to stabilize the implant at placement (Misch 1987). An RBH of <4–5 mm may not allow sufficient primary stability and, for some authors, this is a local contra-indication (Pjetursson & Lang 2014). However, the OSFE procedure has been successfully performed in posterior maxillae with an RBH of <4 mm (Nedir et al. 2013, Si et al. 2013). Using this technique, reconstruction of the posterior maxilla can be simplified and accelerated. To date, no evidence has indicated a critical threshold RBH value for the survival of implants placed with OSFE, because there is a lack of data on maxillae with an RBH of <4 mm (Chao et al. 2010).

Data on the long-term outcomes (≥ 5 years) of implants placed with the OSFE technique are scarce, especially when the RBH was <4 mm. In 2003, eight studies reported the outcomes of at least 10 patients and six months of functional loading of implants; their mean follow-up period was 19.7 months. The survival and success rates were 90.9% and 96.0%, respectively, after 36 months of loading, for all OSFE indications and independently of the RBH reported (Emmerich et al. 2005). Between

January 1985 and December 2011, 25 studies reported on 3,092 implants inserted for at least one year in 1,859 patients. The overall implant survival rate was 96.15% (Călin et al. 2014). In a systematic review of eight studies published before 2013, Corbella et al. (2015) reported an implant survival rate ranging from 95.4–100% for a 3-year follow-up of 1,208 implants.

The use of autogenous bone and/or biomaterial grafts is advocated and yields predictable results for sinus elevation. However, several studies have demonstrated the potential for healing and bone formation in the posterior maxilla beneath the sinus membrane in the absence of grafting material (Bruschi et al. 1998, Winter et al. 2003, Lundgren et al. 2004). Of 19 publications examined in a systematic review of studies published up until 2007 (Tan et al. 2008), three used transalveolar sinus floor elevation without graft insertion (Leblebicioglu et al. 2005, Nedir et al. 2006, Pjetursson et al. 2009). It was recently estimated that 16.9% of implants are placed without any grafting material (Antonaya-Mira et al. 2012). Elevating the sinus membrane in the presence of an RBH of 1–5 mm without the addition of a bone graft may be sufficient to regenerate new bone and allow rehabilitation with implant-supported prostheses (Esposito et al. 2014). The clinical benefits of OSFE without grafting are now documented in terms of implant survival rate, success rate and bone levels. However, only two studies published since 2013 have evaluated OSFE with grafting material against control procedures for up to one (Nedir et al. 2013) and three (Nedir et al. 2016, Si et al. 2013) years.

This study evaluates the efficacy of the OSFE procedure in atrophic maxillae (RBH \leq 4 mm) over a 5-year period. It should confirm the predictability and lasting performance of the procedure. The main aim was to test the null hypothesis that there would be no difference in the 5-year clinical and radiographic outcomes

between implants placed with OSFE in the presence or absence of grafting. Implant success and peri-implant bone levels - endo-sinus bone gain, crestal bone level and available bone height- were compared at one, three and five years. The second objective was to determine whether shrinkage of the bony dome created by the insertion of grafting material occurred.

MATERIAL AND METHODS

Ethics Committees and patient's entry

This study was approved by the ethics committees of the University Hospital of Geneva (Geneva, Switzerland) and the University of Lausanne (Lausanne, Switzerland) for human research, under the protocol reference numbers 06-089 and 245/06, respectively. Informed consent was obtained from all participants. The study was conducted in accordance with the Declaration of Helsinki (2002) and guidelines issued by the ethics committees. Patients were recruited between June 2007 and February 2009 according to the inclusion criteria presented in Figure 1. Sinus randomization was assigned at the time of surgery after implant bed preparation. A random allocation sequence was generated using an open generator (<http://biostat.med.univ-tours.fr>). For each patient, one sinus was randomized by allocation of a sealed independently prepared envelope indicating material grafting (control) or no grafting (test; Nedir et al. 2013). If both sinuses met the enrollment requirements, the right side was treated according to the procedure attributed by randomization, whereas the left side was treated with the other procedure. A single surgeon (RN) enrolled the participants and assigned the surgeries.

Implant placement and prosthetic rehabilitation

All treatments were conducted in a private practice setting (Ardentis Clinique Dentaire Vevey, Vevey, Switzerland; Nedir et al. 2013). The surgical procedures were performed under antibiotic prophylaxis initiated the day prior to surgery (Amoxi-Mepha, Mepha Pharma SA, Aesch Basel, Switzerland; 750 mg, 3 times/day during 6 days or Dalacin C, Pfizer, Zürich, Switzerland; 300 mg, 3 times/day during 5 days, in case of penicillin allergy). A mid-crestal incision was performed for flap elevation, without a vertical or periosteal releasing incision. To obtain access to the sinus floor, the cortical bone was marked using round burs of increasing diameter (\varnothing 1.4–3.1 mm). No drills were used to prepare the osteotomy site prior to direct infracture with the osteotomes. A sinus floor elevation osteotome (\varnothing 2.8 mm; Institut Straumann AG, Basel, Switzerland) was used first. The Schneiderian membrane was elevated by carefully and lightly tapping with a mallet on osteotomes to push the bony sinus floor into the sinus cavity. Stops were used on osteotomes to control the depth of osteotome penetration into the sinus. The osteotomy site was then enlarged with a \varnothing 3.5 mm osteotome; the integrity of the membrane was controlled with an undersized \varnothing 2.1 mm depth gauge and by using the Valsalva maneuver. If the sinus was allocated to the control group, it was filled with 0.5 cm³ (0.25 g) of Bio-Oss® (Geistlich Pharma AG, Wolhusen, Switzerland; granulometry 0.25–1 mm). Implants were placed without tapping and were seated in the osteotomy site until the rough surface limit was no longer visible on the mesial and distal sides; the implant neck protruded above the crest. Although percussive force of the mallet on the osteotomes can induce trauma (Peñarrocha et al. 2001), no patients reported vertigo after surgery. The implants were left to heal transgingivally and the sites were kept prosthesis-free for the whole healing period. Regardless to insertion torque, an impression was taken

after eight weeks of healing. Thereafter conventional prosthetic steps for single-screw crown rehabilitation were conducted.

Clinical follow-up

Implants were examined at one, eight (impression time), 10 (prosthesis delivery) and 12 weeks, and at one, three and five years after implant placement. The criteria for success were: no pain or any subjective sensation, no recurrent peri-implant infection, no clinically detectable implant mobility and no continuous radiolucency around the implant (Buser et al. 1997).

At 12 weeks, and at one, three and five years after implant placement, the following measurements were performed using a periodontal probe at four sites around each implant and the average value was calculated (Buser et al. 1990, Mombelli et al. 1987):

- modified Sulcus Bleeding Index (mBI): score 0: no bleeding when a periodontal probe is passed along the gingival margin adjacent to the implant; score 1: isolated bleeding; score 2: blood forms a confluent red line on margin; score 3: heavy or profuse bleeding;
- probing depth (PD, mm).

Radiographic measurements

Standardized peri-apical radiographs were taken immediately after surgery, at eight weeks and at one, three and five years. Implant placement served as the baseline. Internal calibration was realized on each standardized radiograph by measuring three inter-thread distances (2.4 mm). The peri-apical crestal and endo-sinus bone levels, protrusion of the implant into the sinus and available bone height were recorded on

the mesial and distal sides of the implant. Apical graft height above the implant dome was measured along the implant axis in the control group. Figure 2 details the radiographic landmarks.

Statistical analysis

Descriptive statistics –mean, SD, median and range– were used to present the bone level measurements and regression residuals of data were examined at 1, 3 and 5 years. The data were analysed using mixed linear models that included a random effect (random intercept) for each patient and a fixed effect for the treatment group and year. The threshold value for statistical significance was set at $p < 0.05$.

RESULTS

Patients and implants

Twelve patients (nine women and three men, with a mean age of 57.6 ± 4.7 years) were enrolled. Seven patients needed treatment of both sinuses (bilateral sites) and five patients one sinus. Thirty-seven sites (32 molars and five premolars; 19 sinuses) were treated. All sites presented an RBH of ≤ 4 mm (mean: 2.4 ± 0.9 mm; range: 0.9–4.0 mm). Through randomization, 17 implants were placed without grafting (test group: nine patients, nine sinuses) and 20 implants were placed with grafting material (control group: 10 patients, 10 sinuses).

Clinical follow-up

The mean healing time was 2.6 ± 0.9 months. Throughout the 5-year study, three implants failed. At the 8-week examination, two control implants placed in merged corticals (patient 2, site 16, RBH: 1.4 mm; patient 12, site 27, RBH: 1.2 mm)

were clinically mobile and were removed (Nedir et al. 2013). At 2.7 years, one osseointegrated test implant was removed because of peri-implantitis (patient 7, site 16, RBH: 2.8 mm; Nedir et al. 2016). The remaining 34 implants (16 test and 18 control) were successful and patients reported complete satisfaction after five years. The overall implant success rate was 91.9%; it was 94.1% for the test group and 90.0% for the control group.

Radiographic evaluation

Figure 3a-c shows the clinical and radiographic follow-up of the implants before and immediately after implant insertion, immediately after prosthetic rehabilitation and at the 1-, 3- and 5-year examinations after implant placement. Table 1 displays bone level data measured from standardized radiographs. Statistical analysis confirmed that the distribution of residuals for endo-sinus bone gain (ESBG), crestal bone loss (CBL) and available bone height were approximately normal except for CBL at 1 and 5 years. All implants gained endo-sinus bone. After one year, the mean ESBG was 3.9 ± 1.0 mm (test) and 5.0 ± 1.3 mm (control). It reached 4.1 ± 1.0 mm (test) and 5.1 ± 1.2 mm (control) after 3 years and 3.8 ± 1.0 mm (test) and 4.8 ± 1.2 mm (control) after five years. Most test implant sides (50%) gained 2–4 mm of bone, whereas most control implant sides (55.6%) gained 4–6 mm. An ESBG of >6 mm was observed for one test and seven control implant sides (Table 2). The difference in mean ESBG between the test and control groups was statistically significant at one ($p < 0.001$), three ($p = 0.001$) and five years ($p = 0.004$; Table 1).

The mean CBL was limited, without significant difference between the groups (Table 1). The CBL was >2 mm at one side of three test and five control implants

(Table 2); however, none of these eight implants showed mobility. The available bone height was at least 5.3 mm for seven of these implants.

The 5-year mean available bone height for all sites studied reached 6.5 ± 0.9 mm (test) and 7.8 ± 1.4 mm (control; Table 1); 65.6% of test implant sides exhibited a mean value >6 mm, compared with 86.1% of control implant sides. The available bone height reached at least 8 mm for eleven control implant sides, with a maximum value of 9.7 mm (Table 2). The mean overall ESG, CBL and available bone height did not change significantly between one and three years and between one and five years (Table 3).

Mean protrusion into the sinus in the test implant group was 5.0 ± 1.2 mm immediately after placement; it decreased to 1.0 ± 0.8 mm after one year and remained stable for the remainder of the 5-year follow-up period. The graft above the implants in the control group showed a mean height of 1.5 ± 1.0 mm immediately after surgery (Table 1). At one year, 13 implants in the control group were completely embedded in the peri-implant bony material. The mean apical graft height above the dome of these 13 implants was 0.9 ± 0.8 mm. At three and five years, respectively, 11 implants were embedded, with mean heights of 0.7 ± 0.7 mm and 0.6 ± 0.6 mm, respectively. The difference between apical graft height measurements taken at three and five years was not statistically significant (Table 3). In the test group, two implants were completely embedded at one and three years and four were completely embedded at five years.

Gingival parameters

The mean mBI and PD were presented for all implants in Table 4. The implants of the patients #2, #4 and #7 showed pathological outcomes at 5 years with

increased bleeding on probing and probing depth. Furthermore, one implant (patient 2, site 15) showed a low available bone height of 3.5 mm because of high CBL (4.3 mm). These implants were placed in periodontally-compromised patient who did not strictly attend appointments for dental hygiene and maintenance care.

DISCUSSION

Although an RBH of 5 mm is recommended to achieve sufficient implant stability and osseointegration (Misch 1987), this study was designed to optimize primary stability in sites with an RBH of <4 mm: expansion osteotomes were used instead of drills to avoid ovalization of the osteotomy site and to condense the surrounding bone; implants with a tapered shape and reduced thread pitch were selected to reach primary stability, even in soft bone (Sakoh et al. 2006) and in an RBH of <6 mm (Nedir et al. 2009); and the chemically enhanced rough hydrophilic surface of the implants decreased healing time and improved bone regeneration (Wennerberg et al. 2011). The use of grafting material may not improve the primary stability of the implant.

The overall 5-year success rate was 91.9%. It was higher than the value of 85% reported by Rosen et al. (1999), for implants placed in RBH \leq 4 mm with a mean short-term loading period of 20.2 months. Recently, Gonzalez et al. (2013) compared sinus augmentation via the crestal approach with simultaneous implant placement in sites with an RBH of \leq 4 mm (40 implants) versus those with an RBH of >4 mm (60 implants). The success rate was 100% and 98.51%, respectively, at 6–100 months after prosthetic loading, independent of patient age, sex and treatment centre. The authors concluded that the crestal approach for sinus floor elevation is a viable technique in sites with an RBH of \leq 4 mm. However, in the severely deficient posterior

maxilla (RBH: ≤ 2 mm), the procedure remains challenging and it is necessary to inform patients of the risk of adverse events.

In this study, all implants gained endo-sinus bone over five years. Peri-implant bone was mainly gained during the first year, with no significant change thereafter. A tent-like shape was adopted over the implant dome by the sinus membrane immediately after surgery. However, air pressure within the maxillary sinus cavity can cause the Schneiderian membrane to fall down onto the implant. The collapse of the membrane may prevent bone formation over the implant dome (Sul et al. 2008). Most test implants were not covered with bone; they remained proident within the sinus. The mean ESBG around implants placed without grafting was 3.8 mm. A review of five studies with an implant follow-up period of >1 year reported that a mean gain of 2.86 mm (range: 1.7–4.4 mm) was achieved without grafting material (Romero-Millán et al. 2012). Some authors state that the sinus elevation procedure should be used without grafting only when a small amount of new bone formation is necessary around implants placed in the maxillary sinus cavity (Kim et al. 2010). Nonetheless, Nedir et al. showed that the procedure without grafting appears predictable, with favourable long-term results up to five (Nedir et al. 2010) and 10 (Nedir et al. 2015) years for 10-mm implants placed in sites with a mean RBH of 5.4 ± 2.3 mm. Endo-sinus bone was gained mainly during the first year and reached 2.5 mm after five years and 3 mm after 10 years.

When grafting material is added, the Schneiderian membrane is substantially elevated and a filled space is formed above the implant dome (Reiser et al. 2001). The introduction of biomaterial allows the membrane to withstand sinus air pressure and provides a scaffold for osteogenesis by maintaining the space above the implant dome (Xu et al. 2004). Therefore, bone can form along the implant and beyond the

implant dome. The mean ESBG was 4.8 mm when grafting material was inserted and the mean apical graft height was 0.6 mm. However, resorption of the augmented space above the implant occurs over time. In a long-term study of implants placed using lateral sinus elevation procedures, Hatano et al. (2004) reported that grafts made of a mixture of autologous bone and Bio-Oss® (1:2) shrank during the first three years and then stabilized close to the implant dome. Some fully synthetic materials, such as nanocrystalline hydroxyapatite embedded in silica gel, have shown a mean graft height shrinkage percentage at 12 months after surgery of $8.84 \pm 5.32\%$ (El Hage et al. 2012). For the osteotome procedure, mean shrinkage was approximately 20% for implants placed with miscellaneous materials and in use for at least 24 months (Bernardello et al. 2011). Reductions in the augmented volume generally occur after short observation periods but do not adversely influence implant survival (Shanbag et al. 2014). The size of Bio-Oss® particles does not decrease over time and they do not show typical resorption lacunae on their surfaces (Mordenfeld et al. 2010). Furthermore, implants are in direct contact with newly formed bone, but not with Bio-Oss®, in augmented areas (Hallman et al. 2002). Bio-Oss® therefore functions as a support and may not interfere with the osseointegration of implants and new bone formation along implants (Oliveira et al. 2012). In this study, the height of the graft over the implant dome decreased during the first year and stabilized at 0.6 mm after 5 years. It has been shown that the apical bone level under shrinkage can reach the same level as that obtained without grafting after at least three years (Si et al. 2013). Further assessment of outcomes in the grafted area should be performed in three dimensions using cone-beam computed tomography. This technique is considered a useful radiographic tool to follow up changes in sinus graft volumes (Umanjec-Korac et al. 2014).

High CBL was noticed in patients who exhibited periodontal disease before implant treatment. This was related to the patient's periodontal history and the absence of a strict hygiene follow-up but not to the augmentation technique used. Lack of adherence to supportive periodontal treatment correlates with a higher incidence of bone and implant loss (Roccuzzo et al. 2010). The sinus augmentation procedure should be performed only in patients who demonstrate a capacity to maintain a high standard of oral hygiene (Ellegaard et al. 1997).

Given that the amount of residual bone height is a key factor for primary implant stability and, consequently, osseointegration (Chao et al. 2010), the question of the long-term bone anchorage height needed to maintain long-term stability is rarely addressed. Despite shrinkage of the graft over the implant dome, the mean available bone height obtained for implants placed with grafting remained greater than that for implants placed without grafting (7.7 mm and 6.5 mm, respectively). The insertion of grafting material allows the implant to be embedded in bone up to and over its dome. The outcome of implants that protrude 4 mm into the sinus placed without grafting material was investigated by Sul et al. (2008). The authors reported partial coverage by bone, with an ESBG ranging from 2.5 mm to 3.6 mm (mean: 3.3 mm). In this study, most implants placed in test group were not completely covered by bone. However, exposure of the implant within the sinus was not detrimental to their 5-year survival rate; a mean available bone height of 6.5 mm was sufficient to maintain long-term implant function.

Historically, an RBH of at least 10 mm was recommended for the placement of implants of standard length (≥ 10 mm). Ahn et al. (2012) evaluated reamer-mediated crestal sinus floor elevation and simultaneous placement of 10–12 mm implants in sites with an RBH of < 4 mm or > 4 mm. They reported a 92.7% and 96.4% success

rate, respectively. The authors suggested that, at sites with an RBH of <4 mm, elevation of the Schneiderian membrane by >10 mm may be beyond its resistance capacity. In formalin-fixed cadavers, the risk of membrane perforation was higher when membranes were elevated by 6–8 mm than by 4–5 mm (Reiser et al. 2001). Preservation of the 'tent' shape of the membrane may be a key factor in ESBG. The presence of adjacent implants enables the membrane to remain in an elevated position. In this study, in all patients but one, at least two adjacent implants were inserted in each sinus studied.

The use of short implants (<10 mm) helps to minimize the amount of sinus floor elevation required (Toffler 2006). Therefore, the question 'Is the extremely atrophic posterior maxilla an indication for short (≤ 6 mm) implants?' is pertinent. The use of short implants avoids sinus perforation and grafting. However, it may be limited by biomechanical complications such as an unfavourable crown-to-implant ratio or a higher failure rate in areas of soft bone (Thoma et al. 2015a). Most studies using short implants involved the posterior mandible, rather than the posterior maxilla, because of the presence of cortical bone and the high primary bone-to-implant contact obtained in dense bone structures (Nisand et al. 2015, Slotte et al. 2012). When 8-mm implants are used in sites with an RBH of 1–6 mm, new bone forms around them; therefore, the length of the bony support is expected to be greater for 8-mm implants than for shorter ones (Nedir et al. 2009) and the crown-to-implant ratio offers a more favourable long-term prognosis.

From a patient perspective, implant survival rates and bone level changes are not the only relevant outcome parameters. Safety, cost and morbidity are major determinants of treatment acceptance (Thoma et al. 2015b). In this context and in comparison with lateral sinus-lift, the one-step OSFE procedure without grafting

material allows reductions in treatment cost, duration of surgery and treatment and patient morbidity related to graft infection.

CONCLUSIONS

The outcome of this study indicated that safe and predictable results can be obtained for five years in atrophic posterior maxillae with an RBH of ≤ 4 mm when 8-mm implants are placed using OSFE. After five years, the implant success rate was $>90\%$; the failure risk is higher for implants placed in periodontally-compromised patients. The new bone that formed around implants in the first year was maintained at five years, irrespective of the presence or absence of grafting material. A lack of bone coverage over the implant dome does not lower the success rate.

ACKNOWLEDGEMENTS

The ITI Foundation is acknowledged for its financial support during the first year of the study (grant no 428/2005). The authors declare that they have no conflict of interests.

REFERENCES

- Ahn, S.H., Park, E.J. & Kim, E.S. (2012) Reamer-mediated transalveolar sinus floor elevation without osteotome and simultaneous implant placement in the maxillary molar area: clinical outcomes of 391 implants in 380 patients. *Clinical Oral Implants Research* **23**: 866–872.
- Antonaya-Mira, R., Barona-Dorado, C., Martínez-Rodríguez, N., Cáceres-Madroño, E. & Martínez-González, J.M. (2012) Meta-analysis of the increase in height in maxillary sinus elevations with osteotome. *Medicinal Oral Patología Oral Cirugía Bucal* **17**: e146–e152.
- Bernardello F., Righi, D., Cosci, F., Bozzoli, P., Soardi C. & Spinato, S. (2011) basic and clinical research crestal sinus lift with sequential drills and simultaneous implant placement in sites with <5 mm of native bone: a multicenter retrospective study. *Implant Dentistry*: **20**: 439–444.
- Bruschi, G.B., Scipioni, A., Celesini, G. & Bruschi, E. (1998) Localized management of sinus floor with simultaneous implant placement. A clinical report. *The International Journal of Oral & Maxillofacial Implants* **13**: 219–226.
- Buser, D., Weber, H.P. & Lang, N.P. (1990) Tissue integration of non-submerged implants. 1-year results of a prospective study with 100 ITI hollow-cylinder and hollow-screw implants. *Clinical Oral Implants Research* **1**: 33-40.
- Buser, D., Mericske-Stern, R., Bernard, J.P., Behneke, N., Hirt, H.P., Belser, U.C. & Lang, N.P. (1997) Long-term evaluation of non-submerged ITI implants. Part 1: 8-year life table analysis of a prospective multi-center study with 2359 implants. *Clinical Oral Implants Research* **8**: 161–172.

- Călin, C., Petre, A. & Drafta, S. (2014) Osteotome-mediated sinus floor elevation: a systematic review and meta-analysis. *The International Journal of Oral & Maxillofacial Implants* **29**: 558–576.
- Chao, Y.L., Chen, H.H., Mei, C.C., Tu, Y.K. & Lu, H.K. (2010) Meta-regression analysis of the initial bone height for predicting implant survival rates of two sinus elevation procedures. *Journal of Clinical Periodontology* **37**: 456–465.
- Chen, S., Buser, D. & Wismeijer, D. (2011) Proceedings of the 4th ITI consensus conference and literature review: Sinus floor elevation procedures. In: Chen, S., Buser, D. & Wismeijer, D., eds. ITI treatment guide. Sinus floor elevation procedures, volume 5, p. 6. Berlin: Quintessence.
- Corbella, S., Taschieri, S. & Del Fabbro M. (2015) Long-term outcomes for the treatment of atrophic posterior maxilla: A systematic review of literature. *Clinical Implant Dentistry and Related Research* **17**: 120–132.
- El Hage, M., Abi Najm, S., Bischof M., Nedir, R., Carrel, J.P. & Bernard. J.P. (2012) Graft shrinkage and survival rate of implants after sinus floor elevation using a nanocrystalline hydroxyapatite embedded in silica gel matrix: a 1-year prospective study. *Implant Dentistry* **21**: 213–219.
- Ellegaard, B., Baelum, V. & Karring, T. (1997) Implant therapy in periodontally compromised patients. *Clinical Oral Implants Research* **8**: 180–188.
- Emmerich, D., Att, W. & Stappert, C. (2005). Sinus floor elevation using osteotomes: a systematic review and meta-analysis. *Journal of Periodontology* **76**: 1237–1251.
- Esposito, M., Grusovin, M.G., Rees, J., Karasoulos, D., Felice, P., Alissa, R., Worthington, H.V. & Coulthard, P. (2014) Interventions for replacing missing teeth: augmentation procedures of the maxillary sinus. *Cochrane Database of Systematic Reviews* **5**: CD008397.

- Gonzalez, S., Tuan, M.C., Ahn, K.M. & Nowzari, H. (2013) Crestal approach for maxillary sinus augmentation in patients with ≤ 4 mm of residual alveolar bone. *Clinical Implant Dentistry and Related Research* **16**: 827–835.
- Hallman, M., Sennerby, L. & Lundgren, S. (2002) A clinical and histologic evaluation of implant integration in the posterior maxilla after sinus floor augmentation with autogenous bone, bovine hydroxyapatite, or a 20:80 mixture. *International Journal of Oral & Maxillofacial Implants* **17**: 635–643.
- Hatano, N., Shimizu, Y. & Ooya, K. (2004) A clinical long-term radiographic evaluation of graft height changes after maxillary sinus floor augmentation with a 2:1 autogenous bone/xenograft mixture and simultaneous placement of dental implants. *Clinical Oral Implants Research* **15**: 339–345.
- Jensen, O.T., Shulman, L.B., Block, M.S. & Iacono, V.J. (1998) Report of the sinus consensus conference of 1996. *International Journal of Oral & Maxillofacial Implants* **13** (Suppl): 11–32.
- Kim, H.R., Choi, B.H., Xuan, F. & Jeong, S.M. (2010) The use of autologous venous blood for maxillary sinus floor augmentation in conjunction with sinus membrane elevation: an experimental study. *Clinical Oral Implants Research* **21**: 346–349.
- Leblebicioglu, B., Ersanli, S., Karabuda, C., Tosun, T. & Gokdeniz, H. (2005) Radiographic evaluation of dental implants placed using an osteotome technique. *Journal of Periodontology* **76**: 385–390.
- Lundgren, S., Andersson, S., Gualini, F. & Sennerby, L. (2004) Bone reformation with sinus membrane elevation: a new surgical technique for maxillary sinus floor augmentation. *Clinical Implant Dentistry and Related Research* **6**: 165–173.
- Misch, C.E. (1987) Maxillary sinus augmentation for endosteal implants: organized alternative treatment plans. *International Journal of Oral Implantology* **4**: 49–58.

- Mombelli, A., van Oosten, M.A., Schurch, E. Jr & Lang, N.P. (1987) The microbiota associated with successful or failing osseointegrated titanium implants. *Oral microbiology and immunology* **2**: 145-51.
- Mordenfeld, A., Hallman, M., Johansson, C.B. & Albrektsson, T. (2010) Histological and histomorphometrical analyses of biopsies harvested 11 years after maxillary sinus floor augmentation with deproteinized bovine and autogenous bone. *Clinical Oral Implants Research* **21**: 961–970.
- Nedir, R., Bischof, M., Vazquez, L., Szmukler-Moncler, S. & Bernard, J.P. (2006) Osteotome sinus floor elevation without grafting material: a 1-year prospective pilot study with ITI implants. *Clinical Oral Implants Research* **17**: 679–686.
- Nedir R., Nurdin N., Szmukler-Moncler S., Bischof M. (2009) Placement of tapered implants using osteotome sinus floor elevation technique without bone grafting: 1-year results. *The International Journal of Oral & Maxillofacial Implants* **24**: 727–733.
- Nedir, R., Nurdin, N., Vazquez, L., Szmukler-Moncler, S., Bischof, M. & Bernard, J.P. (2010) Osteotome sinus floor elevation technique without grafting: a 5-year prospective study. *Journal of Clinical Periodontology* **37**: 1023–1028.
- Nedir, R., Nurdin, N., Khoury, P., Perneger, T., El Hage, M., Bernard, J.P. & Bischof, M. (2013) Osteotome sinus floor elevation with and without grafting material in the severely atrophic maxilla. A 1-year prospective randomized controlled study. *Clinical Oral Implants Research* **24**: 1257–1264.
- Nedir, R., Nurdin, N., Khoury P. & Bischof, M. (2016) Short implants placed with or without grafting in atrophic sinuses: The 3-year results of a prospective randomized controlled study. *Clinical Implant Dentistry and Related Research* **18**: 10–18.

- Nedir, R., Nurdin, N., Vazquez, L., Abi Najm, S. & Bischof, M. (2015) Osteotome sinus floor elevation without grafting: A 10-year prospective study. *Clinical Implant Dentistry and Related Research* DOI 10.1111/cid.12331.
- Nisand, D., Picard, N., Rocchiettam I. (2015) Short implants compared to implants in vertically augmented bone: a systematic review (EAO). *Clinical Oral Implants Research* **26** (Suppl 11): 170–179.
- Oliveira, R., El Hage, M., Carrel, J.P., Lombardi, T. & Bernard, J.P. (2012) Rehabilitation of the edentulous posterior maxilla after sinus floor elevation using deproteinized bovine bone: a 9-year clinical study. *Implant Dentistry* **21**: 422–426.
- Peñarrocha, M., Pérez, H., Garcíá, A. & Guarinos J. (2001) Benign paroxysmal positional vertigo as a complication of osteotome expansion of the maxillary alveolar ridge. *Journal of Oral and Maxillofacial Surgery* **59**: 106–107.
- Pjetursson, B.E., Ignjatovic, D., Matuliene, G., Brägger, U., Schmidlin, K. & Lang, N.P. (2009) Transalveolar maxillary sinus floor elevation using osteotomes with or without grafting material. Part II: radiographic tissue remodeling. *Clinical Oral Implants Research* **20**: 677–683.
- Pjetursson, B.E. & Lang N.P. (2014) Sinus floor elevation utilizing the transalveolar approach. *Periodontology 2000* **66**: 59–71.
- Reiser, G.M., Rabinovitz, Z., Bruno, J., Damoulis, P.D. & Griffin, T.J. (2001) Evaluation of maxillary sinus membrane response following elevation with the crestal osteotome technique in human cadavers. *The International Journal of Oral & Maxillofacial Implants* **16**: 833–840.
- Roccuzzo, M., De Angelis, N., Bonino, L. & Aglietta, M. (2010) Ten-year results of a three arms prospective cohort study on implants in periodontally compromised

- patients. Part 1: implant loss and radiographic bone loss. *Clinical Oral Implants Research* **21**: 490–496.
- Romero-Millán, J., Martorell-Calatayud, L., Peñarrocha, M. & García-Mira, B. (2012) Indirect osteotome maxillary sinus floor elevation: an update. *Journal of Oral Implantology* **38**: 799–804.
- Rosen, P.S., Summers, R., Mellado, J.R., Salkin, L.M., Shanaman, R.H., Marks, M.H. & Fugazzotto, P.A. (1999) The bone-added osteotome sinus floor elevation technique: Multicenter retrospective report of consecutively treated patients. *The International Journal of Oral & Maxillofacial Implants* **14**: 853–858.
- Sakoh, J., Wahlmann, U., Stender, E., Al-Nawas, B. & Wagner, W. (2006) Primary stability of a conical implant and a hybrid, cylindrical screw-type implant in vitro. *The International Journal of Oral & Maxillofacial Implants* **21**: 560–566.
- Shanbhag, S., Shanbhag, V. & Stavropoulos, A. (2014) Volume changes of maxillary sinus augmentations over time: a systematic review. *The International Journal of Oral & Maxillofacial Implants* **29**: 881–92.
- Si, M.S., Zhuang, L-F., Gu, Y.X., MO, J.J., Qiao, S.C. & Lai H.C. (2013) Osteotome sinus floor elevation with or without grafting: a 3-year randomized controlled clinical trial. *Journal of Clinical Periodontology* **40**: 396–403.
- Slotte, C., Grønningsaeter, A., Halmøy, A.M., Öhrnell, L.O., Stroh, G., Isaksson, S., Johansson, L.Å., Mordenfeld, A., Eklund, J. & Embring, J. (2012) Four-millimeter implants supporting fixed partial dental prostheses in the severely resorbed posterior mandible: two-year results. *Clinical Implant Dentistry and Related Research* **14** (Suppl 1): e46–e58.
- Sul, S.H., Choi, B.H., Li, J., Jeong, S.M. & Xuan, F. (2008) Effects of sinus membrane elevation on bone formation around implants placed in the maxillary

- sinus cavity: an experimental study. *Oral Surgery, Oral Medicine, Oral Pathology, Oral Radiology, and Endodontology* **105**: 684–687.
- Summers, R.B. (1994) A new concept in maxillary implant surgery: the osteotome technique. *Compendium* **15**: 152–162.
- Tan, W.C., Lang, N.P., Zwahlen, M. & Pjetursson, B.E. (2008) A systematic review of the success of sinus floor elevation and survival of implants inserted in combination with sinus floor elevation. Part II: transalveolar technique. *Journal of Clinical Periodontology* **35** (Suppl.): 241–254.
- Thoma, D.S., Zeltner, M., Hüsler, J., Hämmerle, C.H.F. & Jung, R.E. (2015a) EAO Supplement Working Group 4 – EAO CC 2015. Short implants versus sinus lifting with longer implants to restore the posterior maxilla: a systematic review. *Clinical Oral Implants Research* **26** (Suppl 11): 154–169.
- Thoma, D.S., Haas, R., Tutak, M., Garcia, A., Schincaglia, G.P. & Hämmerle, C.H.F. (2015b) Randomized controlled multicentre study comparing short dental implants (6 mm) versus longer dental implants (11–15 mm) in combination with sinus floor elevation procedures. Part 1: demographics and patient-reported outcomes at 1 year of loading. *Journal of Clinical Periodontology* **42**: 72–80.
- Toffler, M. (2006) Treating the atrophic posterior maxilla by combining short implants with minimally invasive osteotome procedures. *Practical Procedures & Aesthetic Dentistry* **18**: 301–308.
- Umanjec-Korac, S., Wu, G., Hassan, B., Liu, Y. & Wismeijer, D. (2014) A retrospective analysis of the resorption rate of deproteinized bovine bone as maxillary sinus graft material on cone beam computed tomography. *Clinical Oral Implants Research* **25**: 781–785.

- Wennerberg, A., Galli, S. & Albrektsson, T. (2011) Current knowledge about the hydrophilic and nanostructured SLActive. *Clinical, Cosmetic and Investigational Dentistry* **3**: 59–67.
- Winter, A.A., Pollack, A.S. & Odrich, R.B. (2003) Sinus/alveolar crest tenting (SACT): a new technique for implant placement in atrophic maxillary ridges without bone grafts or membranes. *The International Journal of Periodontics and Restorative Dentistry* **23**: 557–565.
- Xu, H., Shimizu, Y., Asai, S., Ooya, K. (2004) Grafting of deproteinized bone particles inhibits bone resorption after maxillary sinus floor elevation. *Clinical Oral Implants Research* **15**: 126–133.

FIGURE LEGENDS

Fig. 1. Inclusion criteria.

Fig. 2. Radiographic measurements.

Crestal bone level: The distance (A), parallel to the implant axis, between the most apical implant thread and the most coronal bone-implant contact, was measured on both sides of each implant and then averaged. A decrease in this mean value on consecutive radiographs was indicative of crestal bone loss whereas an increase was indicative of crestal bone gain. Endo-sinus bone gain: The distance (B) between the most apical implant-bone contact and a reference coronal implant thread was measured on both sides of each implant and then averaged. An increase in this mean value on consecutive radiographs was indicative of endo-sinus bone gain. Protrusion into the sinus: The distance (D) between the implant dome and the most apical implant-bone contact was measured and averaged on both sides of each test implant. Apical graft height: The distance (E) was measured in the control group, along the implant axis. When the Schneiderian membrane was in contact with the implant dome, the (E) value was null. Available bone height: The distance (C) between the most coronal and the most apical implant-bone contact was measured and averaged on both sides of each implant. (C) and (C + E), respectively, express the available bone height for the test and control implants, respectively.

Fig. 3a. Evolution of sinus floor level over 5 years. Radiographs and clinical photographs of cases 1-5.

Implants test (without grafting) Implants control (with grafting).

Fig. 3b. Evolution of sinus floor level over 5 years. Radiographs and clinical photographs of cases 6-9.

Implants test (without grafting) Implants control (with grafting).

Fig. 3c. Evolution of sinus floor level over 5 years. Radiographs and clinical photographs.

Note that the implant 26 of the patient 12 was loaded with a temporary crown after the failure of the implant 27. Definitive crown was delivered 7.5 months later.

Implants test (without grafting) Implants control (with grafting).

Patient inclusion criteria

- a. Patient requires implant treatment in the posterior maxilla.
- b. Tooth extractions at the implant sites were performed at least 4 months before surgery.
- c. Residual bone height between the alveolar bone crest and the sinus floor, measured on panoramic radiograph at each implant site, is ≤ 4 mm.
- d. The osteotome sinus floor elevation procedure will be performed with or without grafting material according to the randomization process.
- e. TE[®] SLActive[®] implants, 4.1/4.8 mm in diameter and 8 mm in length (Institut Straumann AG, Basel, Switzerland) will be placed.
- f. The patient agrees to avoid wearing a removable prosthesis at the implants site during the healing period.
- g. Absence of medical history of acute or chronic sinusitis, sinus disease and previous sinus surgery.
- h. Absence of active periodontal disease, diabetes and metabolic bone disease.

Fig. 1. Inclusion criteria.

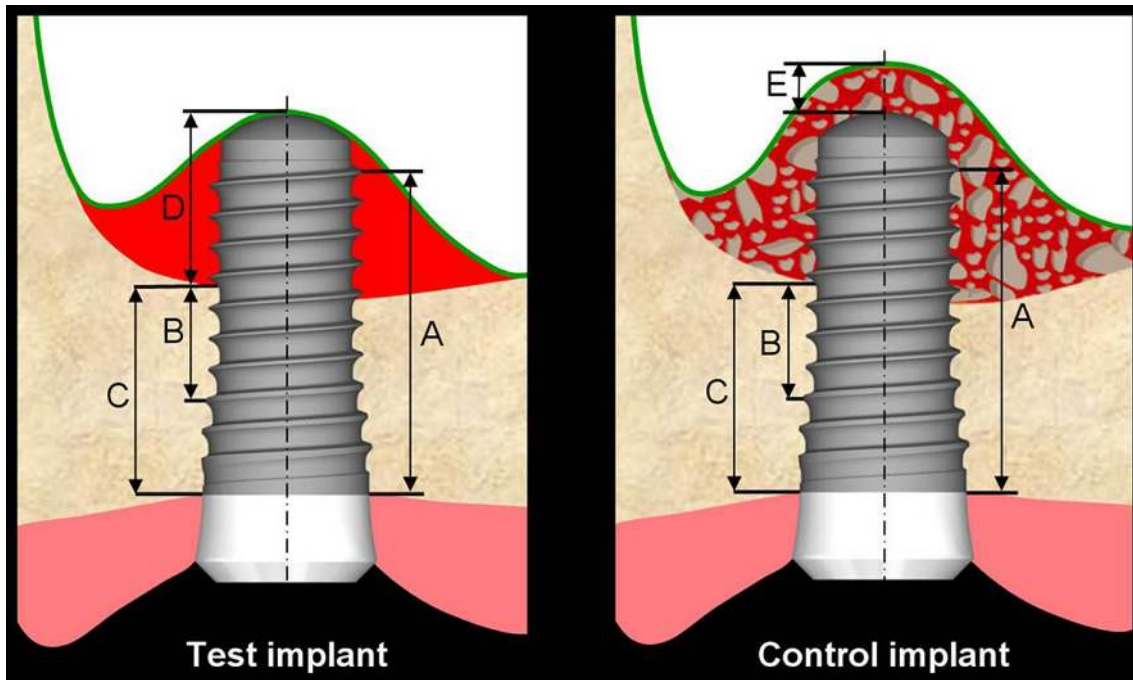


Fig. 2. Radiographic measurements.

Crestal bone level: The distance (A), parallel to the implant axis, between the most apical implant thread and the most coronal bone-implant contact, was measured on both sides of each implant and then averaged. A decrease in this mean value on consecutive radiographs was indicative of crestal bone loss whereas an increase was indicative of crestal bone gain. Endo-sinus bone gain: The distance (B) between the most apical implant-bone contact and a reference coronal implant thread was measured on both sides of each implant and then averaged. An increase in this mean value on consecutive radiographs was indicative of endo-sinus bone gain. Protrusion into the sinus: The distance (D) between the implant dome and the most apical implant-bone contact was measured and averaged on both sides of each test implant. Apical graft height: The distance (E) was measured in the control group, along the implant axis. When the Schneiderian membrane was in contact with the implant dome, the (E) value was null. Available bone height: The distance (C) between the most coronal and the most apical implant-bone contact was measured

and averaged on both sides of each implant. (C) and (C + E), respectively, express the available bone height for the test and control implants, respectively.

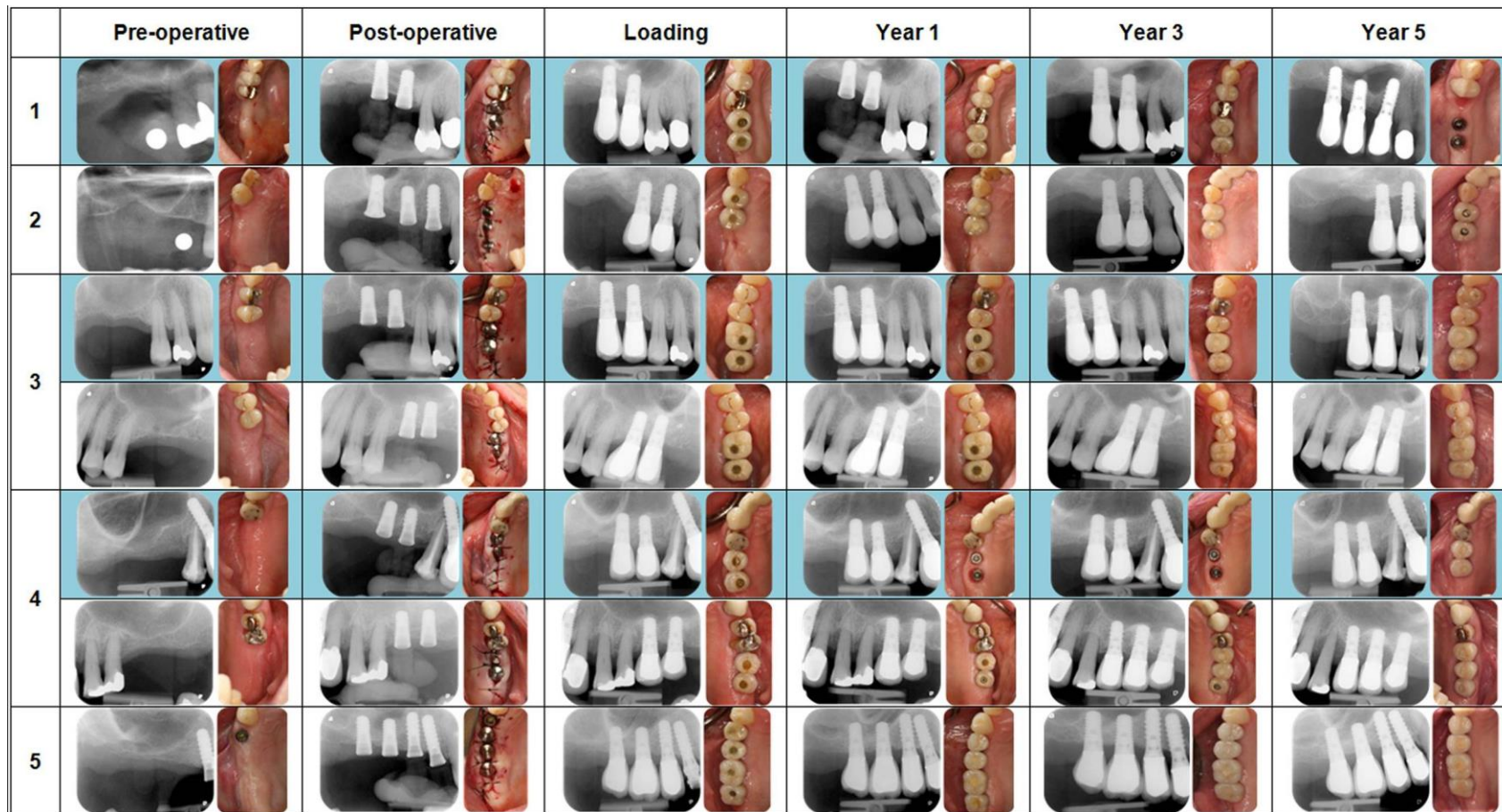


Fig. 3a. Evolution of sinus floor level over 5 years. Radiographs and clinical photographs of cases 1-5.

■ Implants test (without grafting) □ Implants control (with grafting).

	Pre-operative	Post-operative	Loading	Year 1	Year 3	Year 5
6						
7						
8						
9						

Fig. 3b. Evolution of sinus floor level over 5 years. Radiographs and clinical photographs of cases 6-9.

■ Implants test (without grafting) □ Implants control (with grafting).

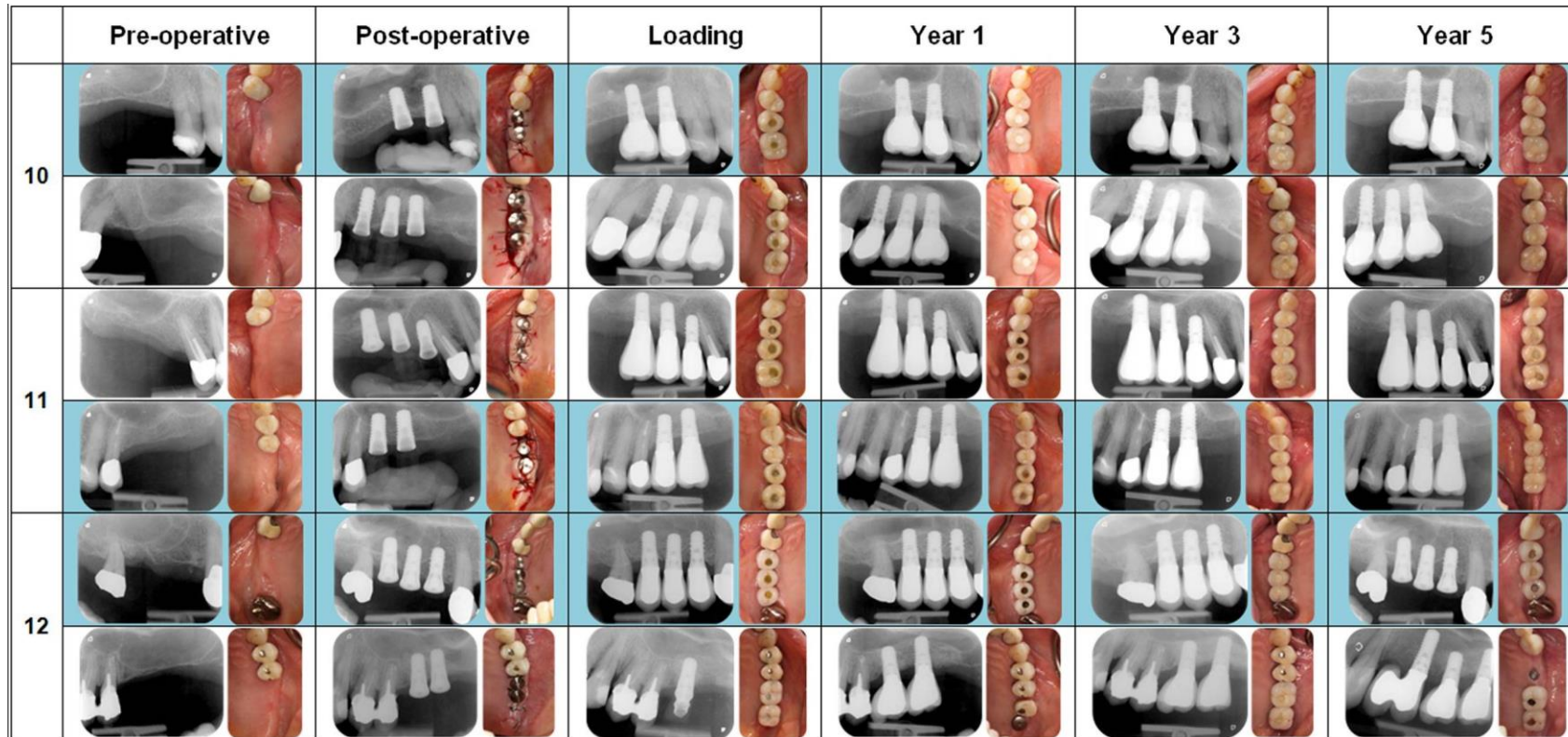


Fig. 3c. Evolution of sinus floor level over 5 years. Radiographs and clinical photographs.

Note that the implant 26 of the patient 12 was loaded with a temporary crown after the failure of the implant 27. Definitive crown was delivered 7.5 months later.

Implants test (without grafting) Implants control (with grafting).

Table 1. Measured radiographic bone data (mean, standard deviation, median value and range).

*p expresses the significance of the difference in results between the test and control groups.

Implant group		Post-surgery		1 year			3 years			5 years		
		Test	Control	Test	Control	p*	Test	Control	p*	Test	Control	p*
Endo-sinus bone gain (mm)	mean			3.9	5.0	<0.001	4.1	5.1	0.001	3.8	4.8	0.004
	SD			1.0	1.3		1.0	1.2		1.0	1.2	
	median		-	4.1	5.1		3.9	5.3		3.9	5.0	
	range			1.8–6.2	2.9–6.7		1.5–7.0	2.0–7.0		0.8–6.7	1.4–7.3	
Crestal bone loss (mm)	mean			0.6	0.4	0.530	0.6	0.5	0.990	0.6	0.7	0.527
	SD			0.8	0.7		1.1	1.0		0.9	1.4	
	median		-	0.5	0.3		0.5	0.2		0.6	0.4	
	range			0–2.4	0–2.1		0.0–3.1	0.0–2.5		0–2.6	0–4.4	
Available bone height (mm)	mean			6.5	8.2	<0.001	6.7	8.0	<0.001	6.5	7.8	<0.001
	SD			1.0	1.5		1.0	1.3		0.9	1.4	
	median		-	6.4	8.5		6.7	8.0		6.2	8.0	
	range			4.6–8.2	5.4–10.3		4.7–8.9	5.4–10.5		4.7–9.0	4.1–10.0	
Protrusion into the sinus (mm)	mean	5.0		1.0		-	0.9		-	1.0		-
	SD	1.2		0.8			0.7			0.8		
	median	5.4	-	1.0	-		0.7	-		1.1	-	
	range	3.1-6.9		0–3.2			0–2.85			0–2.5		
Apical graft height (mm)	mean		1.5		0.9	-		0.7	-		0.6	-
	SD		1.0		0.8			0.7			0.6	
	median		1.5		0.9			0.6			0.7	
	range		0–4.3		0–2.7			0–2.2			0–2.0	

Table 2. Frequency analysis of the 5-year endo-sinus bone gain, crestal bone level and available bone height measured at each side of test and control implants.

		Test (no grafting)	Control (grafting)
		Number of implant sides (%) N= 32	Number of implant sides (%) N = 36
Endo-sinus bone gain	0–2 mm	3 (9.4%)	2 (5.6%)
	2–4 mm	16 (50.0%)	7 (19.4%)
	4–6 mm	12 (37.5%)	20 (55.6%)
	>6 mm	1 (3.1%)	7 (19.4%)
Crestal bone level	loss >3 mm	0 (0%)	3 (8.3%)
	loss 2–3 mm	3 (9.4%)	2 (5.6%)
	loss 1–2 mm	8 (28.0%)	6 (16.7%)
	loss 0–1 mm	10 (31.2%)	9 (25.0%)
	gain	11 (34.4%)	16 (44.4%)
Available bone height	3–6 mm	11 (34.4%)	5 (13.9%)
	6–8 mm	19 (59.4%)	20 (55.6%)
	>8 mm	2 (6.2%)	11 (30.5%)

Table 3. p expresses the significance of the difference in results between follow-up examinations.

p-value	ESBG	CBL	Available bone height	Apical graft height
Years 0–1	-	-	-	0.025
Years 0–3	-	-	-	0.008
Years 0–5	-	-	-	0.025
Years 1–3	0.272	0.371	0.489	0.008
Years 1–5	0.249	0.293	0.426	0.049
Years 3–5	0.050	0.350	0.302	0.347

Table 4. Values of modified Sulcus Bleeding Index (mBI) and probing depth (PD) measured at 12 weeks, and at one, three and five years after implant placement.

Patient	History of periodontitis	Site	Grafting	mBI 12 weeks	mBI 1 year	mBI 3 years	mBI 5 years	BD 12 weeks	BD 1 year	BD 3 years	BD 5 years
1	yes	16	no	0.25	0.50	0.25	0.00	1.25	1.25	1.50	1.00
		17	no	0.25	0.25	0.00	0.50	1.00	1.25	1.75	1.00
2	yes	15	yes	0.50	0.25	1.25	1.25	1.75	1.25	3.25	3.25
		16	yes	-	-	-	-	-	-	-	-
3	yes	16	no	0.25	0.00	0.00	0.25	1.50	1.25	1.25	1.00
		17	no	0.25	0.25	0.00	0.25	1.25	1.00	1.00	1.00
		26	yes	0.50	0.50	0.00	0.50	1.00	1.00	1.00	1.25
		27	yes	0.00	0.25	0.00	0.00	1.00	1.00	1.00	1.00
4	yes	16	no	0.25	1.00	0.00	0.50	1.50	3.00	1.50	4.50
		26	yes	0.25	0.25	0.00	0.50	2.00	2.25	1.50	4.25
		27	yes	0.50	0.25	0.00	0.50	1.50	2.00	2.25	3.75
5	yes	16	yes	0.25	0.25	0.00	0.25	1.00	1.25	1.00	1.00
		17	yes	0.25	0.50	0.75	0.25	1.25	1.50	2.00	1.00
6	no	16	yes	0.25	0.50	0.25	0.25	1.25	1.25	1.00	1.25
		17	yes	0.00	0.50	0.25	1.00	1.00	1.00	1.00	1.50
		26	no	0.00	0.25	0.75	0.00	1.25	1.25	1.50	2.25
		27	no	0.00	0.75	0.75	0.25	1.00	1.00	1.50	1.00
7	yes	16	no	0.75	0.00	-	-	2.25	3.25	-	-
		17	no	0.50	0.00	1.00	0.00	2.50	2.00	6.00	2.75
8	yes	16	yes	0.00	0.25	0.00	0.25	1.75	1.00	1.00	1.50
		17	yes	0.00	0.25	0.00	0.00	1.25	1.25	1.00	1.25
		26	no	0.00	0.00	0.25	0.25	1.00	1.25	1.00	1.00
		27	no	0.00	0.25	0.25	0.00	1.25	1.00	1.00	1.00

9	yes	25	yes	0.50	0.50	0.50	0.50	1.00	1.00	1.00	1.00
		26	yes	0.25	0.25	0.50	0.25	1.00	1.00	1.00	1.25
10	yes	15	no	0.25	0.50	0.00	0.25	1.50	1.00	0.75	1.00
		16	no	0.25	0.75	0.50	0.50	1.50	1.00	0.75	1.00
		25	yes	0.25	0.00	0.25	0.50	1.75	1.00	1.25	1.25
		26	yes	0.25	0.25	0.00	0.25	1.00	1.00	0.25	1.00
11	yes	16	yes	0.50	0.25	0.50	0.00	3.30	1.50	1.25	0.75
		17	yes	0.50	0.25	1.00	0.25	3.00	1.50	1.25	1.00
		26	no	0.25	0.25	0.25	0.25	1.50	1.25	1.00	1.00
		27	no	0.25	0.00	0.25	0.25	1.00	1.75	1.50	1.75
12	no	15	no	0.00	0.25	0.25	0.25	1.00	1.25	1.00	1.00
		16	no	0.25	0.25	0.50	0.25	1.00	1.00	1.00	1.00
		26	yes	0.25	0.25	0.25	0.00	1.00	1.00	1.00	1.25
		27	yes	-	-	-	-	-	-	-	-
Mean				0.25	0.31	0.31	0.30	1.43	1.36	1.38	1.52
Standard deviation				0.19	0.23	0.34	0.27	0.58	0.55	0.96	0.99